

## CLINICAL IMAGES

### Intraoperative point-of-care subcostal Inferior Vena Cava (IVC) imaging to detect embolism during hip arthroplasty: clinical image



Alejandro Corujo<sup>a,b</sup>, Laura Girón-Arango<sup>id c,d,\*</sup>, Gonzalo Irizaga<sup>a,b</sup>, Anahi Perlas<sup>c,d</sup>

<sup>a</sup> Banco de Prótesis, Department of Anesthesiology, Montevideo, Uruguay

<sup>b</sup> Universidad de la República, Department of Anesthesiology, Montevideo, Uruguay

<sup>c</sup> University Health Network, Toronto Western Hospital, Department of Anesthesia and Pain Management, Toronto, Canada

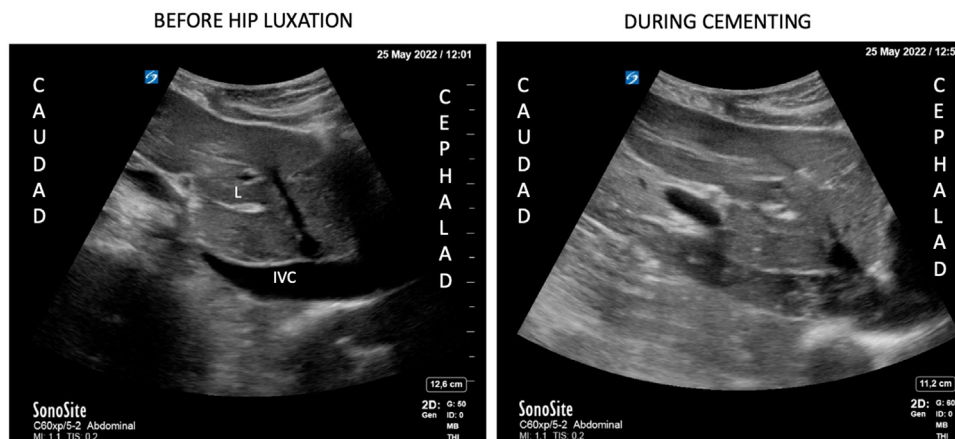
<sup>d</sup> University of Toronto, Department of Anesthesiology and Pain Medicine, Toronto, Canada

Received 6 February 2023; accepted 28 February 2023

Available online 8 March 2023

These images and video were obtained using a low-frequency curvilinear probe, at the subcostal Inferior Vena Cava (IVC) view on a patient with poor functional reserve undergoing a Total Hip Arthroplasty under spinal anesthesia. Embolic material in-transit was initially identified after hip luxation with

progression of severity culminating in an embolic storm during cementing (Fig. 1). The embolic phenomena preceded hemodynamic instability and an episode of cardiac arrest in pulseless electrical activity. Cardiopulmonary resuscitation was successful. Surgery finalized without further events once the



**Figure 1** IVC subcostal view before hip luxation and during cementing. L, Liver; IVC, Inferior Vena Cava.

\* Corresponding author.

E-mail: [laura.gironarango1@uhn.ca](mailto:laura.gironarango1@uhn.ca) (L. Girón-Arango).

<https://doi.org/10.1016/j.bjane.2023.02.007>

0104-0014/© 2023 Sociedade Brasileira de Anestesiologia. Published by Elsevier España, S.L.U. This is an open access article under the CC BY-NC-ND license (<http://creativecommons.org/licenses/by-nc-nd/4.0/>).

patient was stabilized. Once fully recovered, the patient was discharged home within 72 hours. She provided written informed consent for publication.

Embolic events are common but mostly undiagnosed phenomena during hip and knee arthroplasties.<sup>1</sup> However, severe embolic episodes may lead to hemodynamic collapse. The etiology of these emboli is believed to be mixed with bone and soft tissue debris, thrombus, and cement.<sup>2</sup> The use of Transesophageal Echocardiography (TEE) is well-described in the literature to diagnose and quantify embolic events during arthroplasty.<sup>3</sup> However, TEE is not readily available in non-cardiac operating rooms and may not be feasible to perform in patients under spinal anesthesia and mild sedation. We here report the use of the subcostal IVC view as less invasive and more widely available alternative to monitor for embolic phenomena in real time during orthopedic surgery. The early identification of severe embolic events can alert the anesthesiologist and assist in early resuscitation and hemodynamic support, as well as potentially guide surgical technique and timing to prevent further embolization.

### Conflicts of interest

None.

### Funding

Anahi Perlas receives academic support time from a Merit Award, Department of Anesthesiology and Pain Medicine, University of Toronto.

### Supplementary materials

Supplementary material associated with this article can be found in the online version at [doi:10.1016/j.bjane.2023.02.007](https://doi.org/10.1016/j.bjane.2023.02.007).

### References

1. Hagio K, Sugano N, Takashina M, et al. Embolic events during total hip arthroplasty. An echocardiographic study. *J Arthroplasty*. 2003;18:186–92.
2. Moriyama M, Watanabe S, Hiraki T, et al. Relationship between intraoperative transesophageal echocardiography findings and perfusion lung scintigraphy results on first postoperative day. *Br J Anaesth*. 2005;94:607–12.
3. Bisignani G, Bisignani M, San Pasquale G, et al. Intraoperative embolism, and hip arthroplasty: intraoperative transesophageal echocardiographic study. *J Cardiovasc Med*. 2008;9:277–81.