



Brazilian Journal of ANESTHESIOLOGY



CLINICAL IMAGES

Surgical treatment of huge orbital retinoblastoma under general anesthesia in a three-year old child

Bercin Tarlan ^{a,*}, Berrin Gunaydin ^b, Orhan Veyselov ^b, Irfan Gungor ^b, Onur Konuk ^a

^a Gazi University School of Medicine, Department of Ophthalmology, Oculoplastic and Orbital Surgery Service, Ankara, Turkey

^b Gazi University Faculty of Medicine, Department of Anesthesiology, Ankara, Turkey

Received 17 November 2021; accepted 26 March 2022

Available online xxx

Retinoblastoma is the most common primary intraocular cancer in pediatric age.¹ We describe a 3-year-old boy refugee with orbital extension of retinoblastoma due to delayed treatment because of war in his country (Fig. 1). There was no evidence of metastasis. He received 3 cycles of chemotherapy including vincristine, etoposide, and carboplatin. Hemoglobin level was 5.4 g.dL⁻¹ and blood transfusion was given preoperatively. Left orbital exenteration with tumor – free margins under general anesthesia – were performed (Fig. 2) Anesthesia induction was provided using in situ Intravenous (IV) route with 2 mg.kg⁻¹ (50 mg) propofol, and endotracheal intubation was facilitated with IV 3 mg rocuronium with wired tube (ID = 4.0 mm). Then anesthesia was maintained with 2% sevoflurane inhalation in 50% oxygen-air mixture and remifentanil infusion (0.1 μg.kg⁻¹.min⁻¹).

Operation ended uneventfully in 90 minutes. The patient was followed by pediatric oncologist, and systemic chemotherapy was completed. Retinoblastoma is a curable malignancy if detected while it is still limited to the globe.^{1,2} The 5-year survival rate has been reported to be 96% in the USA.² However, due to late diagnosis and presentation of the tumor with advanced disease, retinoblastoma still continues to be a life-threatening problem in low-income countries.³

Conflicts of interest

The authors declare no conflicts of interest.

* Corresponding author:

E-mail: bercintarlan@gmail.com (B. Tarlan).

<https://doi.org/10.1016/j.bjane.2022.03.009>

0104-0014/© 2022 Sociedade Brasileira de Anestesiologia. Published by Elsevier Editora Ltda. This is an open access article under the CC BY-NC-ND license (<http://creativecommons.org/licenses/by-nc-nd/4.0/>).

Please cite this article in press as: B. Tarlan, B. Gunaydin, O. Veyselov et al., Surgical treatment of huge orbital retinoblastoma under general anesthesia in a three-year old child, Brazilian Journal of Anesthesiology (2022), <https://doi.org/10.1016/j.bjane.2022.03.009>

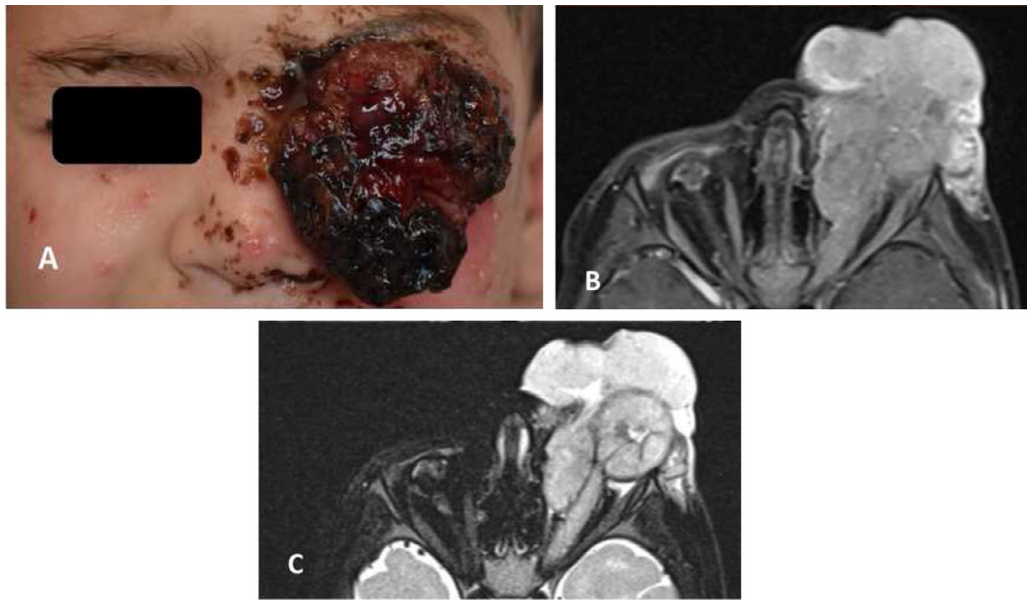


Figure 1 (A) Orbital extension of an intraocular retinoblastoma at the initial clinical presentation, manifesting with massive proptosis of the left eye. (B and C) T1 and T2 magnetic resonance imaging of the orbit.

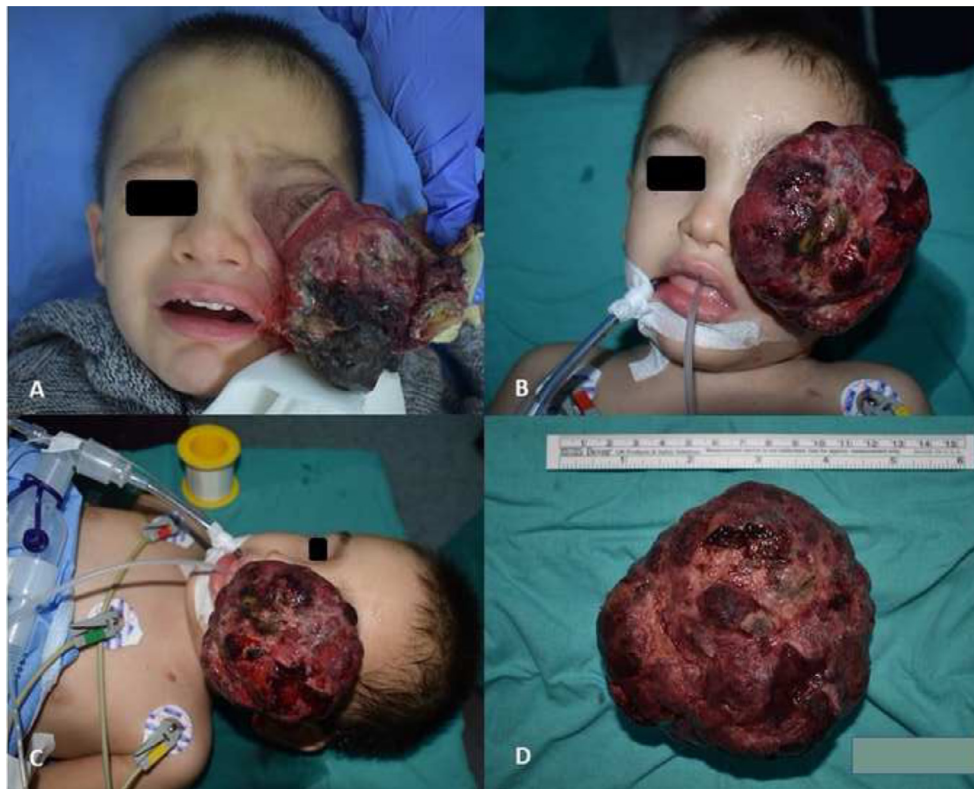

Figure 2 (A) Image of the patient after three cycles of chemotherapy. (B and C) Peroperative images of the patient. (D) The excision specimen was measured to be 20 × 16 × 11 cm.

References

1. Kaliki S, Shields CL, Rojanaporn D, et al. High-risk retinoblastoma based on international classification of retinoblastoma: analysis of 519 enucleated eyes. *Ophthalmology*. 2013;120:997–1003.
2. Broaddus E, Topham A, Singh AD. Survival with retinoblastoma in the USA: 1975-2004. *Br J Ophthalmol*. 2009;93:24–7.
3. Chantada GL, Qaddoumi I, Canturk S, et al. Strategies to manage retinoblastoma in developing countries. *Pediatr Blood Cancer*. 2011;56:341–8.