



CASE REPORT

Anesthetic management of a patient with acquired angioedema submitted to broncofibroscopy: a case report



Melanie Barata *, Ana Marques , Catarina Tiago , Marta Dias-Vaz , Nuno Losa, Carmen Oliveira

Centro Hospitalar Vila Nova de Gaia/Espinho, Department of Anaesthesiology, Vila Nova de Gaia, Portugal

Received 7 January 2021; accepted 13 November 2021

Available online 27 November 2021

KEYWORDS

Angioedema;
C1 Esterase Inhibitor;
Airway Management;
Bronchoscopy

Abstract Acquired angioedema with C1 inhibitor deficiency (AAE-C1INH) is a very rare condition of bradykinin-mediated angioedema. One of its major complications is potentially life-threatening, laryngeal edema. We report a 53-year-old woman with AAE-C1INH proposed for an elective broncofibroscopy. The direct stimulation caused by broncofibroscopy poses a high risk of angioedema, thus presenting an anesthetic challenge. Due to the risk of death, it is essential to adopt preventive measures. Short-term prophylaxis was performed, and the acute treatment was readily available. A well-structured multidisciplinary periprocedural plan makes it possible to safely approach the airway, in a remote area of the hospital.

© 2021 Sociedade Brasileira de Anestesiologia. Published by Elsevier Editora Ltda. This is an open access article under the CC BY-NC-ND license (<http://creativecommons.org/licenses/by-nc-nd/4.0/>).

Introduction

Acquired angioedema with C1 inhibitor deficiency (AAE-C1INH) is a very rare condition of angioedema with a prevalence in the general population estimated to be 1:10 that of the hereditary form, that is, around 1:50.000.¹

It is characterized by an increase in vascular permeability and vasodilation, resulting from an overproduction of

bradykinin, due to C1 esterase inhibitor (C1-INH) deficiency or dysfunction.^{2,3} C1-INH plays an important role in the complement cascade, fibrinolysis, and contact activation (Fig. 1).² It is usually associated with rheumatologic disorders and B-cell lymphoproliferative diseases.^{2,4} This condition usually appears after the fourth decade with no family history.^{1,4} It manifests with acute, localized, non-pitting, nonpruritic, non-erythematous, and demarcated angioedema.^{1,3} It typically lasts for 2–5 days and resolves spontaneously.³ Edema predominantly involves the face, tongue, uvula, and upper airways.¹ Laryngeal edema incidence is approximately 70% during the disease course and can be fatal in 15–33% of the cases.³ Although the edema can be spontaneous, there are several triggers such as (1)

Abbreviations: AAE-C1INH, Acquired angioedema with C1 inhibitor deficiency; C1-INH, C1 esterase inhibitor; HAE, Hereditary angioedema; PdC1INH, Plasma-derived C1-INH concentrate.

* Corresponding author.

E-mail: melaniebarata2@gmail.com (M. Barata).

<https://doi.org/10.1016/j.bjane.2021.11.007>

0104-0014/© 2021 Sociedade Brasileira de Anestesiologia. Published by Elsevier Editora Ltda. This is an open access article under the CC BY-NC-ND license (<http://creativecommons.org/licenses/by-nc-nd/4.0/>).

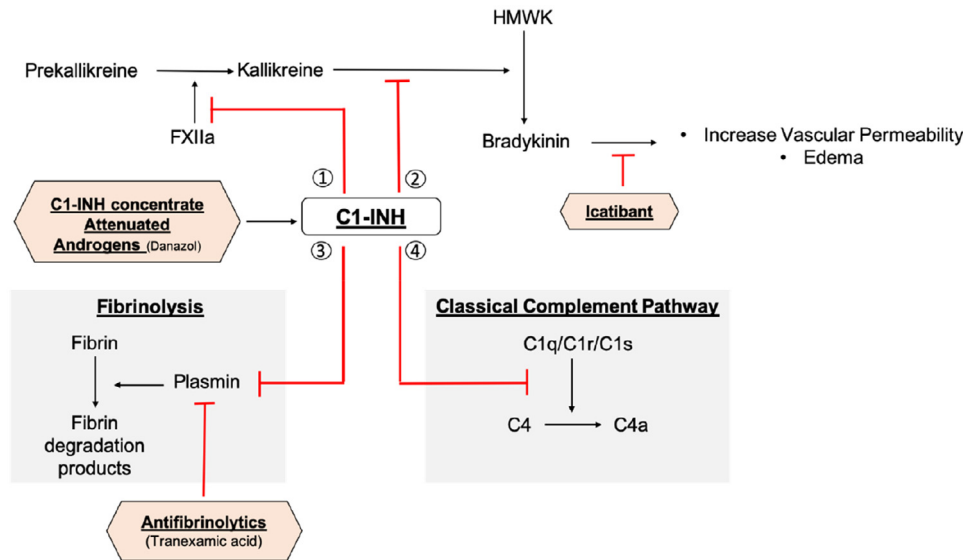


Figure 1 The function of C1 esterase inhibitor (C1-INH) includes inhibition of (1) activated factor XII (FXIIa)-mediated cleavage of prekallikrein to kallikrein; (2) kallikrein-mediated conversion of highmolecular-weight kinin (HMWK) to bradykinin; (3) plasmin-mediated fibrinolysis; (4) C1 esterase-mediated activation of C4 in the classical complement pathway. In the presence of C1-INH dysfunction or deficiency, there is no inhibition of the contact activation, fibrinolysis and complement cascade, leading to overproduction of bradykinin and consequently edema. Management of bradykinin-mediated angioedema can include increasing C1-INH levels with C1-INH concentrate and attenuated androgens (e.g., danazol) and inhibition of bradykinin with Icatibant and plasmin with antifibrinolytics (e.g., tranexamic acid). C1-INH, C1 esterase inhibitor; FXII, Factor XII; HMWK, highmolecular-weight kinin. Figure redrawn based on “MacBeth LS, Volcheck GW, Sprung J, Weingarten TN. Perioperative course in patients with hereditary or acquired angioedema. *J Clin Anesth.* 2016;34:385-91.” with authors’ permission.

anesthetic and surgical trauma, (2) dental procedures, and (3) psychological and physiological stress. Triggers may vary between and within patients, thus it is not possible to predict complications, making the management of this disorder especially challenging.²

Distinguishing between AAE-C1INH and hereditary angioedema (HAE) can be difficult as clinically these two entities are indistinguishable.^{3,4} Both conditions have usually low C1-INH and C4 levels.^{3,4} By contrast, C1q levels are often depressed in patients with AAE-C1INH, but nearly always normal in patients with HAE.^{3,4} Clinical history can also provide important clues. Family history and onset of symptoms in the first or second decade of life favors HAE, and the presence of malignancy or auto-immune diseases favors AAE-C1INH.^{3,4}

The following clinical case is presented after informed consent was obtained.

Clinical case

We report a case of a 53-year-old woman, with obesity grade I, hypertension, anxiety, and AAE-C1INH associated with systemic lupus erythematosus. She was never submitted to general anesthesia with airway manipulation.

She was proposed for bronchofibroscopy, in the bronchoscopy suite, with bronchoalveolar lavage due to suspicion of interstitial lung disease.

The patient was diagnosed with AAE-C1INH nine years ago, after recurrent episodes of angioedema (lip, eye, and hand). Two previous episodes required stay in an

intermediate care unit and the last one was seven years ago, triggered by an infection. At the time of diagnosis, C4 and C1q were decreased. The patient has been on Danazol since then, currently in a dose of 100 mg every 3 days, prescribed by the attending immunologist.

After multidisciplinary evaluation by the anesthesiologist, pulmonologist and immunologist, short-term prophylaxis was performed with Danazol 200 mg each 8 hours 5 days prior and maintained 3 days after the procedure. Plasma-derived C1-INH concentrate (PdC1INH) 2 doses of 1500 U and subcutaneous Icatibant 30 mg were readily available for acute treatment of AAE-C1INH.

Prior to anesthetic induction, standard ASA (American Society of Anesthesiologists) monitoring and a peripheral venous access were obtained. Emergency equipment was readily available, and a second anesthesiologist was within reach. Bronchofibroscopy was performed under deep sedation with fractionated boluses of intravenous propofol, total dose of 290 mg. The patient remained on spontaneous ventilation with oxygen supply through a fiberoptic face mask. Anesthetic procedure lasted 20 minutes and was uneventful. The patient was transferred to the Postanesthesia Care Unit for recovery and surveillance during 24 hours. Drugs for acute treatment were not needed.

Discussion

Despite being a very rare disease, AAE-C1INH poses a great anesthetic challenge due to the high risk of angioedema caused by airway manipulation. Bronchofibroscopy directly

stimulates the airway, increasing the risk of upper airway angioedema in these patients. Angioedema can be fatal, so it is important to consider it pre-, intra-, and post-procedure, and anesthesiologists must be familiar with prevention and treatment strategies.

Management of patients with AAE-C1INH is still not well defined. There are no specific guidelines for AAE-C1INH. Its treatment has been extrapolated from HAE with some particularities.¹ Treatment of the underlying disease may lead to resolution of angioedema.¹

To treat acute crises, PdC1INH and newer treatments such as Icatibant, a bradykinin receptor antagonist, are available.^{2,5} Replacement therapy with PdC1INH has been effective with most patients responding, however some are resistant or require higher doses, because of rapid C1-INH catabolism mediated by autoantibodies. Those patients may respond to Icatibant.^{1,5} For this reason, PdC1INH and Icatibant were available, although the probability of using both was very low. PdC1INH is used in a dose of 20 U.kg⁻¹ IV (intravenous), usually 1500 U repeated if ineffective. Icatibant is used in a dose of 30 mg subcutaneously and can be repeated every six hours twice if needed.⁵

Long-term prophylaxis to prevent angioedema has been used in AAE-C1INH.¹ It is indicated when patients have more than one exacerbation monthly if rescue therapy is not effective or is unavailable.⁵ Antifibrinolytics (such as tranexamic acid 20–50 mg.kg⁻¹.day⁻¹ split 2 to 3 times daily), attenuated androgens (such as Danazol up to 200 mg.day⁻¹), or PdC1INH are recommended for this approach.^{1,5} Attenuated androgens were considered to be more effective and best tolerated for long-term prophylaxis of HAE^{1,5} and were traditionally used.⁴ PdC1INH is currently the preferred long-term prophylaxis in HAE patients.⁴ Antifibrinolytic agents are not recommended for long-term prophylaxis. They are primarily used when PdC1INH is not available and androgens are contraindicated.⁴ However, in AAE-C1INH, antifibrinolytic agents tend to be more effective than in the hereditary form and experts recommend this as the drug of choice for prophylaxis in AAE-C1INH.^{1,4} Our patient was already medicated with danazol and has her disease well controlled free of crisis for 7 years. For this reason, no modifications in her long-term prophylaxis were made.

Short-term prophylaxis has only been described for HAE and mainly necessary when planning an elective dental extraction or other surgical procedures with manipulation of the airway.^{4,5} PdC1INH and attenuated androgens are available. Due to possible refractoriness of AAE-C1INH patients to C1-INH concentrate, it is reserved for acute treatment and not for prophylaxis.⁴ For this reason, our patient did short-term prophylaxis by increasing the dose of danazol in the periprocedural period, instead of PdC1INH.

For any procedure, acute treatment of bradykinin-induced angioedema should be readily available.^{4,5}

Since the principal mediator is bradykinin, and not histamine, agents such as epinephrine, steroids, antihistamines will be ineffective to treat AAE-C1INH.^{2,5}

Even with short-term prophylaxis and having acute treatment readily available, there is the possibility of an acute

periprocedural crisis. Accordingly, it is desirable to minimize any laryngeal trauma which may trigger later angioedema and continue to monitor the patient in a Postanesthesia Care Unit.

The role of the anesthesiologist becomes essential to emergently manage a difficult airway and its particularities in the out of the room setting. Emergency airway equipment and help must be readily available. So far, no anesthetic drugs have been contraindicated in patients with bradykinin-mediated angioedema.^{2,3} Drugs that are known to potentially worsen this disease are estrogen contraceptives, hormone replacement therapy, and angiotensin-converting enzyme inhibitors.^{4,5}

In this case, sedation with propofol was chosen, maintaining spontaneous ventilation. In the case of acute angioedema, direct laryngoscopy may be difficult or even impossible due to the possibility of distorted airway anatomy. Awake fiberoptic intubation with spontaneous ventilation may be an alternative. However, it is important to be prepared for urgent cricothyrotomy.³

Although AAE-C1INH is a very rare disease, its life-threatening risk makes it essential that the patients and their families are informed and are aware of the importance of informing health providers when reaching a health facility. A multidisciplinary approach is extremely important, and it is essential that anesthesiologists become familiarized with the disease, its management, and preventive measures. Prophylactic and acute treatment drugs should be available throughout the procedure.

A well-structured multi-disciplinary periprocedural plan makes it possible to safely approach the airway in a patient with AAE-C1INH, in a remote area of the hospital. In this case, all the preventive measures contributed to a positive outcome.

Conflicts of interest

The authors declare no conflicts of interest.

References

1. Cicardi M, Aberer W, Banerji A, et al. Classification, diagnosis, and approach to treatment for angioedema: consensus report from the Hereditary Angioedema International Working Group. *Allergy*. 2014;69:602–16.
2. MacBeth LS, Volcheck GW, Sprung J, et al. Perioperative course in patients with hereditary or acquired angioedema. *J Clin Anesth*. 2016;34:385–91.
3. Hoyer C, Hill MR, Kaminski ER. Angio-oedema: an overview of differential diagnosis and clinical management. *Continuing Education in Anaesthesia Critical Care & Pain*. 2012;12:307–11.
4. Maurer M, Magerl M, Ansotegui I, et al. The international WAO/EAACI guideline for the management of hereditary angioedema – the 2017 revision and update. *Allergy*. 2018;73:1575–96.
5. Bowen T, Cicardi M, Farkas H, et al. 2010 International consensus algorithm for the diagnosis, therapy and management of hereditary angioedema. *Allergy Asthma Clin Immunol*. 2010;6:24.