

## CASE REPORT

# Unilateral lingual nerve and hypoglossal nerve injury caused by a novel laryngeal mask airway: a case report



Caixia Li<sup>a,1</sup>, Yi Lou<sup>a,1</sup>, Yafang Shen<sup>b</sup>, Su Jiang<sup>c</sup>, Hua Xu<sup>id a,\*</sup>

<sup>a</sup> Shanghai University of Traditional Chinese Medicine, Yueyang Hospital of Integrated Traditional Chinese and Western Medicine, Department of Anesthesiology, Shanghai, China

<sup>b</sup> Fudan University, Huashan Hospital, Department of Anesthesiology, Shanghai, China

<sup>c</sup> Fudan University, Huashan Hospital, Department of Hand Surgery, Shanghai, China

Received 31 July 2021; accepted 24 October 2021

Available online 27 November 2021

### KEYWORDS

Case report;  
Complication;  
Cranial nerve injury;  
The laryngeal mask  
airway

### Abstract

Cranial nerve injury by a laryngeal mask airway is rare but a serious complication. The nerve injuries must be prevented during the intubation using a laryngeal mask airway. We report a female patient who complained of tongue numbness, slurred speech, and slight difficulty in swallowing solid food after a hand surgery. She was then diagnosed with unilateral lingual nerve and hypoglossal nerve injuries. Extreme head rotation, relatively small oral cavity, and wide rigid composition at the lower part of the novel laryngeal mask probably resulted in cranial nerve injury.

© 2021 Sociedade Brasileira de Anestesiologia. Published by Elsevier Editora Ltda. This is an open access article under the CC BY-NC-ND license (<http://creativecommons.org/licenses/by-nc-nd/4.0/>).

## Introduction

The laryngeal mask airway (LMA) is a supraglottic airway device between the face mask and the endotracheal tube. It has been widely used in certain surgical procedures. Complications related to the LMA during surgery are commonly not life-threatening. However, serious and rare complications like aspiration of gastric contents, trauma, nerve injuries, and compression of vascular structures have been reported.<sup>1–3</sup> Here, we report a rare case of unilateral lingual nerve and hypoglossal nerve injuries during the use of a novel laryngeal mask airway.

## Case report

A 57-year-old female patient (weight, 65 kg; height, 155 cm) with no significant medical history underwent exploratory release of the right brachial plexus under general anesthesia. Anesthesia was induced with 1 mg of midazolam, 20 µg of sufentanyl, 100 mg of propofol, and 6 mg of cisatracurium. A novel size-4 laryngeal mask was then inserted smoothly. The location of LMA inserting was confirmed by capnography, with the absence of sounds over the epigastrium. The maintenance of anesthesia consisted of continuous intravenous infusions of propofol and remifentanyl under mechanical ventilation, with a peak inspiratory pressure of 15 cmH<sub>2</sub>O. Neuromuscular blockers were not administered during the operation due to the requirement for intraoperative electromyography monitoring. The surgery lasted approximately 1 hour. No clinical

\* Corresponding author

E-mail: [pshhuaxu@163.com](mailto:pshhuaxu@163.com) (H. Xu).

<sup>1</sup> Caixia Li and Yi Lou has equal contribution

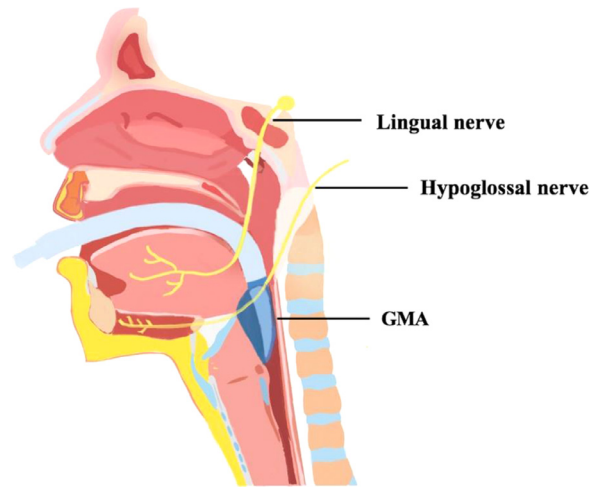
meaningful changes in cardiovascular or respiratory parameters during the operation. The LMA was gently removed after the surgery when spontaneous respiration was adequate and the patient was fully awake. She was then relocated to the recovery room with no complaints. Two hours later, she complained of tongue numbness, and slurred speech as well. Physical examination indicated the decrease in sensation and loss of taste in the anterior two-thirds of the tongue. Meanwhile, when she was requested to stick out her tongue, it deviated toward the left side. The limb muscle strength and tone were not seen any abnormal. On day 2 (1 day postoperative), her speech recovered to some extent. After receiving a normal diet, she complained of a slight difficulty in swallowing solid food, but no concern in drinking water. A cranial MRI plain scan ruled out the diagnosis of acute cerebral infarction. MRI scan for this patient indicated small double frontal parietal lobe ischemic foci without diffusion weighted imaging (DWI) hyperintensity lesions. DWI is a commonly performed MRI sequence for evaluation of acute ischemic stroke, which is sensitive and specific in the detection of small and early infarcts. No DWI hyperintensity lesions in this patient and her speech impairment gradually recovered without sudden limb dysfunction, limb numbness, and disturbance of consciousness, suggesting the acute cerebral infarction was very unlikely. In addition, laryngoscopy showed a good movement of both vocal cords. According to her symptoms and examinations, a clinical diagnosis of unilateral lingual nerve and hypoglossal nerve injury was suggested. She was then given intravenous dexamethasone for three days. Her symptoms improved substantially, with slight numbness of her tongue and mild difficulty in swallowing a week after. After six weeks, she completely recovered without any residue symptoms.

## Discussion

Cranial nerve injury following the use of LMA is rare but a serious complication. Branches of the trigeminal, glossopharyngeal, vagus, and hypoglossal nerves are considered involved in the cranial nerve injury. As summarized by a systematic review, lingual nerve injury was the leading report, then followed by recurrent laryngeal, hypoglossal, glossopharyngeal, inferior alveolar, and infra-orbital nerves.<sup>3</sup>

The clinical manifestation depends on the cranial nerve revolved in the injury. Lingual nerve lesions are generally related to loss of taste and sensation in the anterior region of the tongue; hypoglossal nerve damage leads to dysphagia and tongue deviation to the affected side, and the lesion of the recurrent laryngeal nerve causes postoperative dysarthria and aspiration. In the current report, this patient initially showed the decrease in sensation in the anterior two-thirds of the tongue and tongue deviation, as well as the difficulties in speaking and swallowing, which suggested a result of lingual and hypoglossal nerve damages.

Cranial nerve paralysis can be caused by the damages from somewhere along the nerve. When the lingual nerve runs beneath the mucosa on the inner surface of the mandible below the roots of the third molar tooth, it is prone to compression at the periosteum close to the molar by the shaft of the LMA.<sup>4</sup> The hypoglossal nerve located above the greater horn of the hyoid bone at the angle of the mandible before turning forward and medially toward the tongue. The

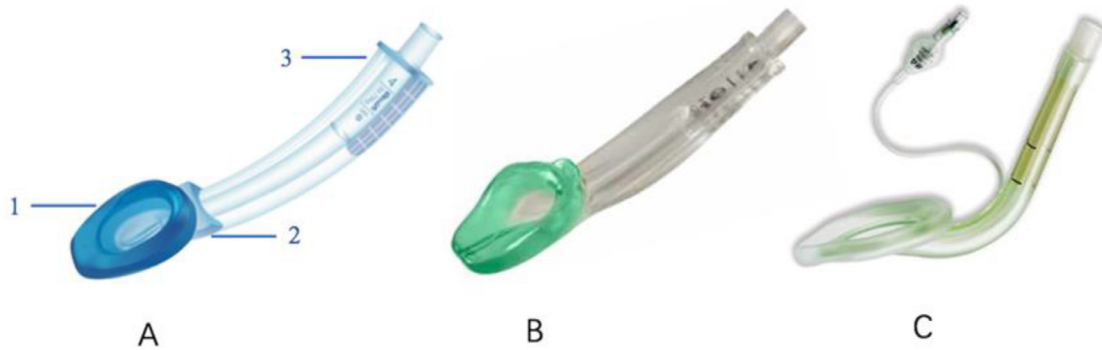

**Figure 1** Insertion of the laryngeal mask airway and the surrounding nerves.

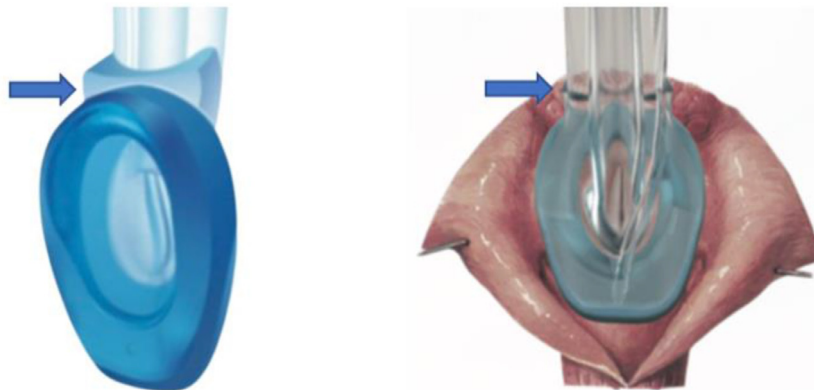
nerve is vulnerable to damage from compression against the hyoid bone by the cuff of the LMA (Fig. 1).

The etiology of cranial nerve injury by LMA was considered to be multifactorial, including anesthesia-related factors (e.g., incorrect or forceful insertion and excessive cuff pressures), patient-associated factors (like diabetes mellitus patients vulnerable to ischemia injury) and surgery-dependent factors incorporating lateral position and prolonged duration.<sup>3</sup>

Regarding this reported case, the LMA was placed gently and smoothly, and it was confirmed to be in the appropriate position without any leakage. The operation lasted approximately 1 hour. A novel LMA with FDA approval named glottis mask airway (GMA) (Fig. 2), manufactured by Chinese Tianjin Medan Medical Crop, was used for this patient. It was a bowl-shaped glottis mask airway with a non-inflatable cuff that was specifically designed to match the anatomy of the laryngeal aperture. As many reports in the literature, the cranial nerve injury was associated with the high pressure of the over-inflatable cuff of the LMA. However, nerve injury in association with the i-gel has also been described despite its lack of a cuff. It was speculated to be attributed to some of the design features of the i-gel device.<sup>5</sup> Being similar to i-gel, GMA has a soft gel-like cuff, but without the necessity of inflation. Unlike other LMA, there was a distinctive tongue base rest for GMA as the device stabilizer and a C-channel for gastric tube insertion on the side of the tube. The wide stabilizer and the integral bite block design resulted in the tube a bit bulkier and harder than other types of LMA (Fig. 2). The tongue base rest of GMA was a horizontal plane to hold a tongue base and stabilize the glottis mask airway, especially in case of position shift during anesthesia, as shown in Figure 3. During the operation, the patient was in supine position, but her head was tilted to the left side as much as possible for the convenience of the surgeons. Extreme head rotation and wide rigid composition at the lower part of the tube, probably resulted in an increase in the pressure on the lingual nerve at the medial aspect of the inner surface of the mandible, which was close to the third molar and hypoglossal nerve at the site of the angle of the mandible. Moreover, the distinctive tongue base rest for



**Figure 2** The view of 3 types of laryngeal mask. A, GMA; B, i-gel; C, inflatable LMA; 1, non-inflatable gel-like cuff; 2, tongue base rest; 3, C-channel for gastric tube insertion.



**Figure 3** A, the tongue base rest of GMA (blue arrow); B, a schematic view of the contrasted position between the human larynx and GMA. Blue arrow indicates the tongue base rest.

GMA was likely to increase the risk of lingual nerve compression at the lateral edge of the tongue base, in case of extreme head rotation for this patient.

In addition, the size of the LMA should also be considered. The small size of LMA which could lead to an overinflated cuff, was likely to cause cranial nerve injury.<sup>3</sup> The current choice of LMA size was mainly based on body weight. In this case, the female patient with bodyweight of 65 kg used the size-4 GMA with a non-inflatable cuff. Again, her oral cavity was relatively small for the wide shaft of the GMA, thereby increase the pressure on the cranial nerve substantially, especially during head rotation.

This report suggests the differences in device design, such as the width of the shaft or the material quality of the LMA, might influence their propensity to cause nerve injury. The caution should be taken to prevent cranial nerve injuries during the use of the LMA.

### Conflicts of interest

The authors declare no conflicts of interest.

### Supplementary materials

Supplementary material associated with this article can be found in the online version at [doi:10.1016/j.bjane.2021.10.014](https://doi.org/10.1016/j.bjane.2021.10.014).

### References

1. Kluger MT, Short TG. Aspiration during anaesthesia: a review of 133 cases from the Australian Anaesthetic Incident Monitoring Study (AIMS). *Anaesthesia*. 1999;54:19–26.
2. Jindal P, Rizvi AA, Khurana G, et al. Safety and efficacy of insertion of supraglottic devices in anaesthetised patients by first-time users. *South Afr J Anaesth Analg*. 2010;16: 23–6.
3. Thiruvankatarajan V, Van Wijk RM, Rajbhoj A. Cranial nerve injuries with supraglottic airway devices: a systematic review of published case reports and series. *Anaesthesia*. 2015;70: 344–59.
4. Graff-Radford SB, Evans RW. Lingual nerve injury. *Headache*. 2003;43:975–83.
5. Thiruvankatarajan V, Van Wijk RM, Elhalawani I, et al. Lingual nerve neuropraxia following use of the Laryngeal Mask Airway Supreme. *J Clin Anesth*. 2014;26:65–8.