

## SHORT COMMUNICATION

# The effectiveness of the axillary plexus block in the resource-limited area of a low-income country, Ethiopia: a prospective cohort study

Fantahun Tarekegn \*, Misganew Terefe, Kassaw Moges

Bahir Dar University, Department of Anesthesia, Bahir Dar, Ethiopia

Received 11 August 2021; accepted 30 October 2021

Available online 27 November 2021



## Background

The brachial plexus block is the preferred regional anesthesia for upper limb surgery because it has the clinical benefits of less nausea and vomiting, longer pain relief, and earlier hospital discharge for outpatient surgery.<sup>1,2</sup> According to the anatomical study of Carlos A. and Jaime A., the median, radial, and ulnar nerves are found in discrete fascial compartments of the axillary neurovascular sheath.<sup>3</sup> Burnham and his colleagues discovered that accumulating local anesthetic solution in the axillary sheath could make the blocking procedure easier and allow for a single axillary injection.<sup>4</sup>

The success rate of axillary plexus block is dependent on the loss of resistance to the axillary sheath.<sup>5</sup> In addition, the standard criterion for the onset of the block was set arbitrarily at 30 minutes for the assessment of primary axillary block.<sup>6</sup> A variety of tools are available to evaluate the effectiveness of axillary blockage, such as pinprick or loss of cold sensation with an icepack,<sup>7</sup> and skin temperature.<sup>8</sup>

The main objective of our study was to establish the overall success rate and incidence of complications associated with the axillary plexus block with loss of resistance technique for forearm, wrist, or hand surgery.

## Methods

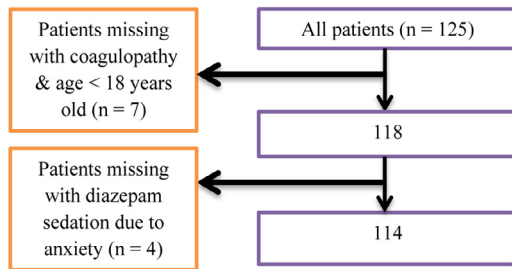
The College of Medicine and Health Science's ethical review board (ERB) gave its approval for the study to go on with written informed consent. The surveys were completed anonymously. From August 1, 2019, through December 30, 2020, data was collected using a prospective cohort study design. The study was also given a research registry unique identification number (UIN) of research registry 6893 retrospectively. Furthermore, the data from the study was presented utilizing the EQUATOR checklist or flowchart as a guide.

All adult patients scheduled for elbow, forearm, or hand surgery at Tibebe Ghion Specialized Hospital operation theatre were selected for the prospective study design. Patients with coagulopathy, infection at the site of the nerve block, history of allergy to local anesthetics, known neuropathies, age less than 18 years old, body mass index greater than 35 kg.m<sup>-2</sup>, and a patient with anxiety who needed diazepam sedation were all excluded (Fig. 1).

Patients were supine, with one arm nearly 90 degrees abducted and the other resting on the pillow next to the head. The block was administered with 60 mL of local anesthetics (20 mL of 1% lidocaine and 40 mL of 0.25% bupivacaine), with the amount increased to 70 mL for patients weighing more than 70 kg. The insertion of a short beveled needle (just above the axillary artery) was noticed, but one pass of the axillary sheath sounded like "POP". The complete quantities of local anesthetic were then deposited

\* Corresponding author.

E-mail: medeset39@gmail.com (F. Tarekegn).



**Figure 1** The number of cases with missing data at Tibebe Ghion Specialized Hospital.

into the axillary sheath with continuous aspiration to minimize inadvertent vascular puncture.

Pinprick was used to test the sensory block (4 nerves) on a three-point scale: 0 = normal sensation, 1 = loss of pinprick sensation (analgesia), and 2 = loss of touch sensitivity. The sensory block was evaluated every 5 minutes for 30 minutes following the administration of local anesthetic.

The sample size was chosen based on the largest data that has been collected during the study period, rather than on power calculations.

The efficacy of the axillary plexus block, as determined by the block's status after 30 minutes, was the study's main outcome variable. The block's level was regarded as a binary variable (0 if the block was incomplete and 1 if it was complete). The incidence of intraoperative complications was the study's secondary outcome variable.

Age, weight, height, sex, ASA (American Society of Anesthesiologists) physical status, and operation site (forearm, wrist, or hand) were the independent variables.

The data was collected between August 2019 and February 2021. Within 30 minutes of the surgery, data collectors checked on the patients' nerve block status. SPSS v. 21 was used for the statistical analysis with presentation of absolute or relative frequencies and percentages.

## Results

A total of 125 participants were enrolled in the study. Because the data on eligibility requirements was incomplete, seven patients were ruled out of the research. Due to the patients' concern, it also overlooked four patients who were given diazepam for sedation. There was no need for intraoperative analgesia in any of the 114 patients.

During surgery, all axillary block patients were awake and no one required airway support. There were no complications that were noted. The efficacy of axillary block was not linked with patient demographics or other independent variables (Table 1). The findings were reported in a descriptive manner, with absolute and relative frequencies of events observed (Table 2).

## Discussion

According to our study, the axillary plexus block has proven to be extremely reliable in our practice. As a result, blocking the axillary plexus with the Winnie method or a loss of resistance approach resulted in a greater overall sensory

**Table 1** Patient demographics and clinical characteristics.

	Mean ± SD
Age	33.95±12.69
Weight	61.42±7.04
Height	168.37±4.15
Sex	
Male	96 (84.2%)*
Female	18 (15.8%)*
ASA physical status	
I	92 (80.7%)*
II	17 (14.9%)*
III	5 (4.40%)*

Frequency (percentage) = n (%)\*

**Table 2** Frequency of the complete and failed nerve blocks.

	Frequency n (%)
<b>Successful blocks</b>	101 (88.59%)
<b>Failed blocks</b>	13 (11.41%)
Failure on Musculocutaneous nerve	9 (7.89%)
Failure on Radial nerve	3 (2.63%)
Failure on Ulnar nerve	1
Failure on Medial nerve	1
Failure on Medial cutaneous nerve of forearm	1

blockage of the ulnar, median, radial, and musculocutaneous nerves (88.59%). This result matched a 92.5% success rate found in an Australian study.<sup>9</sup> Other research, however, suggested that the axillary plexus block was only 60–65% effective.<sup>10</sup> Our assessment's result variance could be attributed to discrepancies in the block's procedures and methodology.

The effectiveness of the Winnie axillary block, also known as a loss of resistance approach, was dependent on a correct diagnosis of the axillary sheath as well as block techniques.<sup>5</sup> Because the musculocutaneous nerve exits the brachial plexus proximally, a beveled needle should be guided to the head of the humerus to cover the musculocutaneous nerve with local anesthetic diffusion.<sup>4</sup> This brought about the rationalization of the complete axillary plexus block.

When a peripheral nerve stimulator and ultrasound tools are not available, this approach (loss of resistance/Winnie) can be used as the sole regional anesthetic in resource-constrained areas of low-income countries. It would also be utilized by clinicians and other researchers as a resource.

Our research does have certain limitations. In this prospective study, only the intraoperative time was examined. We didn't check the motor function after the axillary block. In addition, the effects of the axillary block on postoperative analgesic use and the time it took for the first analgesic request were not considered.

## Conclusion

The axillary plexus block with loss of resistance (Winnie) technique has been shown to be a safe and reliable mode of

regional anesthesia in procedures involving the forearm, wrist, or hand. There had been no reported complications, therefore this block was considered a good alternative for upper-limb surgery.

### Conflicts of interest

The authors declare no conflicts of interest.

### Acknowledgment

Our special gratitude was to the Anesthesia Department, Bahir Dar University for helping with data collection.

### Supplementary materials

Supplementary material associated with this article can be found, in the online version, at [doi:10.1016/j.bjane.2021.10.004](https://doi.org/10.1016/j.bjane.2021.10.004).

### References

1. Pavlin DJ, Rapp SE, Polissar NL, et al. Factors affecting discharge time in adult outpatients. *Anesthesia & Analgesia*. 1998;87:816–26.
2. Chan VW, Peng PW, Kaszas Z, et al. A comparative study of general anesthesia, intravenous regional anesthesia, and axillary block for outpatient hand surgery: clinical outcome and cost analysis. *Anesth Analg*. 2001;93:1181–4.
3. Bollini CA, Wikinski JA. Anatomical review of the brachial plexus. *Techniques in Regional Anesthesia and Pain Management*. 2006;10:69–78.
4. Burnham PJ. Regional block of the great nerves of the upper arm. *Anesthesiology*. 1958;19:281–4.
5. Vester-Andersen T, Christiansen C, Sørensen M, et al. Perivascular axillary block II: influence of injected volume of local anaesthetic on neural blockade. *Acta Anaesthesiol Scand*. 1983;27:95–8.
6. Sia S, Bartoli M, Lepri A, et al. Multiple-injection axillary brachial plexus block: a comparison of two methods of nerve localization—nerve stimulation versus paresthesia. *Anesth Analg*. 2000;91:647–51.
7. Curatolo M, Petersen-Felix S, Arendt-Nielsen L, et al. Sensory assessment of regional analgesia in humans: a review of methods and applications. *Anesthesiology*. 2000;93:1517–30.
8. Galvin EM, Niehof S, Medina HJ, et al. Thermographic temperature measurement compared with pinprick and cold sensation in predicting the effectiveness of regional blocks. *Anesthesia & Analgesia*. 2006;102:598–604.
9. Pearce H, Lindsay D, Leslie K. Axillary brachial plexus block in two hundred consecutive patients. *Anaesth Intensive Care*. 1996;24:453–8.
10. Youssef M, Desgrand D. Comparison of two methods of axillary brachial plexus anaesthesia. *Br J Anaesth*. 1988;60:841–4.