

high minute ventilation (12–15 L.min⁻¹). In these patients, we changed the humidification system from HME to HH. The patients became more compliant to the NIV with better synchrony and sputum clearance. We were able to wean all patients in due course of 15 to 20 days.

During invasive ventilation, the natural humidification system of the upper airway is bypassed. Theoretically 30 mg H₂O.L⁻¹ is the minimum humidity required for ventilation⁴; however, it is not clear whether the same is required during NIV. The minimum absolute humidity during NIV is 15 mg H₂O.L⁻¹.⁵ If no humidification is used, the absolute humidity during NIV comes down to 5 mg H₂O.L⁻¹.⁴ Lellouche et al.⁵ stated that if mask leak is present, humidification dropped by 30% when HME is used, but remained the same with heated humidifier.

An international survey was conducted by Esquinas et al.⁴ to determine humidification practices and its relationship with untoward outcomes during NIV. They found that in NIV failure patients, difficult intubation was encountered in 5.4%. It stated that in 50% of this subgroup of patients, no humidification system was used during NIV.

Hence, we suggest regular use of active humidification (heated wire) in COVID-19 patient, as humidification improves airway function by clearing secretion from the airway. This would result in increased comfort to the patient, increases NIV tolerance, and prevent the creation of a challenging environment for endotracheal tube placement.

There is a lack of clear guideline or recommendation regarding the appropriate humidification application to COVID-19 ARDS patients during NIV. Different humidification methods applied for intubated patients cannot be extrapolated to NIV. A well-structured comparative study between humidification versus ambient air during NIV will answer the question.

Conflicts of interest

The authors declare no conflicts of interest.

References

1. Yang X, Yu Y, Xu J, et al. Clinical course and outcomes of critically ill patients with SARS-CoV-2 pneumonia in Wuhan, China: a single-centered cc, retrospective, observational study. *Lancet Respir Med.* 2020;8:475–81.
2. Avdeev SN, Yaroshetskiy AI, Tsareva NA, et al. Noninvasive ventilation for acute hypoxemic respiratory failure in patients with COVID-19. *Am J Emerg Med.* 2021;39:154–7.
3. Cheung TM, Yam LY, So LK, et al. Effectiveness of noninvasive positive pressure ventilation in the treatment of acute respiratory failure in severe acute respiratory syndrome. *Chest.* 2004;126:845–50.
4. Esquinas A, Nava S, Scala R, et al. Intubation in failure of noninvasive mechanical ventilation: preliminary results (abstract). *Am J Respir Crit Care Med.* 2008;177:A644.
5. Lellouche F, Maggiore SM, Lyazidi A, et al. Water content of delivered gases during non-invasive ventilation in healthy subjects. *Intensive Care Med.* 2009;35:987–95.

Amarjeet Kumar^a, Chandni Sinha^{b,*}, Abhyuday Kumar^b, Neeraj Kumar^a, Ajeet Kumar^b, Kunal Singh^b, Prabhat Kumar Singh^c

^a Department of Trauma and Emergency, All India Institute of Medical Sciences Patna, Bihar, India

^b Department of Anaesthesiology, All India Institute of Medical Sciences Patna, Bihar, India

^c Director, All India Institute of Medical Sciences Patna, Bihar, India

* Corresponding author.

E-mail: drchandnis@aiimspatna.org (C. Sinha).

Received 11 May 2021; accepted 20 July 2021

<https://doi.org/10.1016/j.bjane.2021.07.021>

0104-0014/ © 2021 Published by Elsevier Editora Ltda. on behalf of Sociedade Brasileira de Anestesiologia. This is an open access article under the CC BY-NC-ND license (<http://creativecommons.org/licenses/by-nc-nd/4.0/>).

Videolaryngoscopes: not only for endotracheal intubation



Dear Editor,

Advances in technology enable healthcare professionals to solve problems faster and more easily with lower complication rates. Following the introduction of videolaryngoscopes in clinical practice, increase in success and decrease in complication rates in the management of difficult endotracheal intubation were achieved within a short period, causing rapid popularization of these devices. Even though originally developed for difficult intubation, they quickly entered into routine practice due to their handling similarity to classic laryngoscopes, ease of use and their facilitative properties to 3D image adaptation.¹ Because of these features, videolaryngoscopes are frequently used in areas outside the operating room such as emergency services, ambulances, or intensive care units² as well as diagnosing

and/or solving various problems in the mouth, pharynx, and larynx.¹ Studies on the use of videolaryngoscopes for different purposes other than endotracheal intubation appear more frequently in the literature, such as intraoral examination and/or small interventions, placement of TEE probe, endoscope or nasogastric tube, assistance for flexible tracheoscopic intubation, providing exposure for laryngeal surgery or nasotracheal intubation.^{1–3} In this letter, we wanted to share the various uses of videolaryngoscopes in our clinical practice apart from routine endotracheal intubation, as shown below, and present the pictures of a case (Fig. 1) we considered most unusual.

- Assisting nasotracheal intubation
- Control of vocal cord movements after thyroid operations
- Securing the proper placement of electromyographic tube before thyroidectomy
- Control and removal of foreign bodies
- Placement or correcting malpositions of nasogastric tube

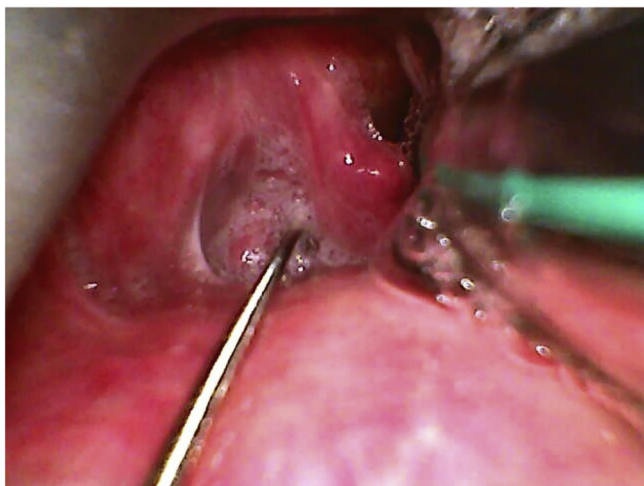


Figure 1 Videolaryngoscope-assisted guidewire insertion during esophageal dilatation in a 31-year-old case of colonic interposition.

- Guiding fiberoptic bronchoscopes/tracheoscopes, tracheal tube introducers, or bougies
- Laryngeal endoscopy and/or vocal cord injection
- Insertion of transesophageal echocardiography probes
- Assisting deep hypopharyngeal packing
- Diagnosing/recording of pathologies from upper airway to just below the vocal cords
- Guidewire placement during esophageal dilatation (Fig. 1)
- Help in advancing the tube when using the tube exchanger to protect the epiglottis

Videolaryngoscopes can provide wide-angle viewing and allow the soft tissue retraction simultaneously. These properties make these devices very useful for healthcare professionals for many procedures in the oropharyngeal cavity, especially in deep levels or in extraordinary anatomic conditions. In this letter, to emphasize the possible novel

uses of it, we present two cases in which the videolaryngoscope was used for indications other than endotracheal intubation. Although these devices are not yet widely available for financial reasons, videolaryngoscopes with various features seem to find a larger place in daily practice. Also, their previously mentioned properties, ease of use, and recording features seem to give them a special role in future anesthesiology practice.

Conflicts of interest

The authors declare no conflicts of interest.

References

1. Goranović T. IntechOpen, Special Considerations in Human Airway Managements Videolaryngoscopy, the Current Role in Airway Management. Special Considerations in Human Airway Managements; 2020. <http://dx.doi.org/10.5772/intechopen.93490>.
2. Aseri S, Ahmad H, Vallance H. Video laryngoscopy improves endotracheal intubation training for novices. *Br J Anaesth.* 2015;115:133.
3. Crosby ET. Early clinical experience with a new videolaryngoscope. *Can J Anesth.* 2014;61:485–8.

Coşkun Araz *, Zeynep Kayhan 

Baskent University Medical School, Department of Anesthesiology, Ankara, Turkey

*Corresponding author.

E-mail: arazcoskun@yahoo.com (C. Araz).

Received 8 July 2021; accepted 29 July 2021

<https://doi.org/10.1016/j.bjane.2021.07.024>

0104-0014/ © 2021 Sociedade Brasileira de Anestesiologia.

Published by Elsevier Editora Ltda. This is an open access article under the CC BY-NC-ND license (<http://creativecommons.org/licenses/by-nc-nd/4.0/>).

The quest for smooth extubation: I banned air from the ETT cuff for good...

Dear Editor,

It is known for a fact that tracheal extubation may be associated with the risk of some complications. The Difficult Airway Society (DAS) developed a guideline for the management of tracheal extubation in 2012.¹ While the DAS guideline provides an excellent starting point in developing strategies for achieving a successful extubation, it does not provide a distinction between successful extubation and “smooth” extubation. The concept of smooth emergence was mentioned in the DAS guideline as desirable for the success of certain surgical procedures, but it did not specify which procedures. Despite much of the discussion regarding extubation techniques in the literature, there is no precise definition of “smooth extubation”. Coughing during emer-



gence from general anesthesia is common among intubated patients (40 to 76%). Among the physiological consequences of peri-extubation coughing we can cite complications as neck hematoma after thyroidectomy or carotid endarterectomy, wound dehiscence after laparotomy, and intracerebral hemorrhage after intracranial surgery. As such, the quest for a “smooth extubation” has been pursued in the literature. Multiple medications have been shown to reduce emergence coughing, such as lidocaine (IV, intracuff, topical, laryngotracheal), dexmedetomidine, fentanyl, and remifentanyl. Beyond the humanitarian aspect, the “smooth” extubation should be a goal to be pursued even in ordinary anesthesia, because it is a potentially avoidable source of complications. It is uncertain; however, which combination of measures and/or medication is the most effective for reducing this adverse event. Studies are limited by small sample sizes and heterogenous interventions. These limitations are also reflected in the published systematic reviews and meta-analyses.² It should be noted that the COVID-19