








## CASE REPORT

# Ultrasound-guided popliteal sciatic nerve block in a pediatric patient with complex regional pain syndrome: a case report



Patrícia Milena Souza Vinent , Eduardo José Silva Gomes de Oliveira ,  
Caio Márcio Barros de Oliveira , Ed Carlos Rey Moura ,  
Elizabeth Teixeira Nogueira Servin , Lyvia Maria Rodrigues de Sousa Gomes ,  
Plinio da Cunha Leal \*

Universidade Federal do Maranhão (UFMA), São Luís, MA, Brazil

Received 23 October 2020; accepted 10 July 2021  
Available online 26 July 2021

### KEYWORDS

Complex regional  
pain syndrome;  
Pain;  
Nerve block;  
Case report

**Abstract** In the pediatric population, complex regional pain syndrome (CRPS) is a challenging condition that leads to chronic psychosocial dysfunction. This case is of a 12-year-old male patient, 50 kg, who, after twisting his right ankle, started to present intense pain. Without adequate diagnosis and treatment, his family sought a pain specialist. During the evaluation, a change in sensitivity and temperature was observed, besides hyperalgesia, allodynia, redness, edema, and motor dysfunction, being diagnosed with CRPS. Ultrasound-guided sciatic blocks were performed on the affected limb, increasing the interval between crises, reducing pain intensity, and promoting a return to daily activities.

© 2021 Published by Elsevier Editora Ltda. on behalf of Sociedade Brasileira de Anestesiologia. This is an open access article under the CC BY-NC-ND license (<http://creativecommons.org/licenses/by-nc-nd/4.0/>).

## Introduction

In the pediatric population, complex regional pain syndrome (CRPS) is often a challenging disorder that is closely associated with a prolonged course of psychosocial pain and dysfunction. Commonly, in this population, various forms

of approaches are needed for the adequate and universal treatment of the patient's symptoms.<sup>1</sup>

The treatment modalities of CRPS focus on the use of opioids, anticonvulsants, corticosteroids, and bisphosphonates, as well as interventional treatment with a sympathetic plexus blockade. There is still no proven superior therapy however an excellent clinical response to plexus blocks is observed.<sup>1</sup>

Popliteal sciatic nerve block (PSNB) promotes a sensory and sympathetic fiber block. It is a difficult technique to

\* Corresponding author.

E-mail: [pliniocunhaleal@hotmail.com](mailto:pliniocunhaleal@hotmail.com) (P.C. Leal).

perform that became popular with the use of ultrasound to assist in performing the technique.<sup>2</sup> Although there are few studies with this type of intervention in CRPS in the pediatric population, regional blocks are described as an alternative in cases presenting with dysautonomia and sympathetically mediated pain.<sup>3</sup>

This study presents a case report, according to the CARE guidelines,<sup>3</sup> of a pediatric patient with CRPS that received a sequence of PNSB. Due to the lack of reports on the subject, especially in pediatrics, its importance is emphasized, being one of the first studies with this type of approach in a difficult-to-manage pain.

## Case report

A 12-year-old male child, 50 kg, with CRPS in the right lower limb was submitted to a series of popliteal sciatic nerve blocks (PSNBs). The patient reported intense pain in the right foot after twisting the ankle during sports practice. The next day, he underwent a computed tomography scan of his right foot, showing slight joint effusion. The joint was immobilized for 11 days due to intense pain. After the removal of the immobilization, the patient presented pain during physical activities.

The child was accompanied by an orthopedist and a rheumatologist due to persistent pain and gradual worsening of the pain. After 3 months, he underwent 3 magnetic resonance images and several laboratory markers, which showed only mild diffuse bone edema without laboratory changes.

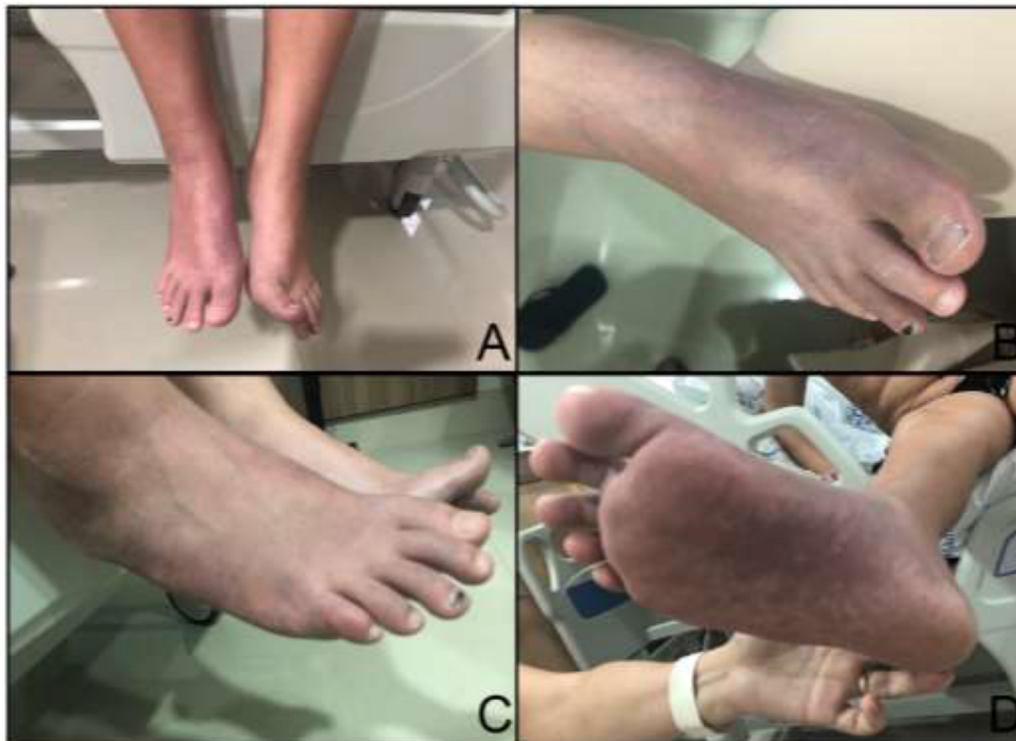The pain worsened and became continuous. After 4 months of the lesion, he continued with limitation, requir-

ing a wheelchair to move. Motor and analgesic physiotherapy were started without improvement.

Given the difficulty in pain control and frequent reports of foot shocks, the patient was referred to the pain specialist. During the physical examination, he reported pain disproportionate to the trigger event and a change in sensitivity and temperature in the right foot was observed, in addition to hyperalgesia, allodynia, redness, edema, pain in limb handling, and motor dysfunction (with decreased strength and tonus) (Fig. 1). A diagnosis of complex regional pain syndrome was made according to the criteria of the International Association for the Study of Pain (IASP), also called Budapest criteria. Through the evaluation, it was possible to classify CRPS in a dystrophic or subacute stage (second stage/grade).

He started treatment with gabapentin 300 mg every 8 hours, methadone 5 mg every 12 hours and amitriptyline 25 mg daily, which was later exchanged for duloxetine 60 mg daily, since with amitriptyline there was a complaint of dry mouth and dizziness that were not tolerated by the patient. Physiotherapy for pain control was also maintained.

After two weeks of treatment, the patient presented his first pain crisis and was hospitalized. He reported intense (10/10), continuous pain. Then, his first popliteal ischial nerve block (PSNB) was performed in June 2019, with significant pain improvement. Using ultrasonography, the ischial nerve was identified in the popliteal fossa, and 20 ml of ropivacaine 0.2% associated with betamethasone dipropionate 5 mg and betamethasone disodium phosphate 2 mg were injected. Another four PSNB procedures were performed monthly with 20 ml of 0.2% ropivacaine, with gradual improvement. The interventions were well tolerated by the



**Figure 1** A, Difference in the color of the right lower limb (cyanosis) compared to the left; B and C, Dorsal cyanosis of the right foot and dystrophy on the third finger; D, Plantar cyanosis of the right foot.

patient who once related a gradual and continuous improvement after the procedures.

Despite the important improvement in pain (2/10) and the patient's ability to move without help, the family members reported that the patient had a depressed mood and no motivation to perform the activities he usually liked to perform. One year after the injury, the patient started a psychiatric follow-up, was diagnosed with depression, and started treatment.

Until then, he used gabapentin 300 mg every 8 hours, methadone 5 mg every 12 hours, fluoxetine 20 mg daily and cannabidiol 4.2 mg every 8 hours, with good adherence to the treatment, reporting good pain control. Thus, through the positive results obtained after the combination of intervention and optimized pharmacological treatment, duloxetine and methadone were gradually withdrawn, maintaining fluoxetine 20 mg daily and cannabidiol 4.2 mg every 8 hours in the therapeutic plan.

After almost one year of his last PSNB, the patient presented a new pain crisis, and it was necessary to perform a new PSNB, in addition to reintroducing methadone 5 mg 12 hours daily, which had been gradually withdrawn. Additionally, he returned to his psychiatrist and, during the evaluation, the patient reported dreaming of his parents' death by COVID-19, which may have worsened his pain symptoms. With another PSNB intervention and adjustments to his therapeutic plan, the patient reported good control of symptoms, denying pain (0/10). Currently, the patient has returned to practicing sports and can perform his daily activities without hindrance.

## Discussion

CRPS is an autonomic pathology that usually appears after trauma in limb extremities, and it may or may not be associated with nerve injury. In the pediatric population, it is a challenging disorder that is often associated with a prolonged course of pain and psychosocial dysfunction for the patient, such as anxiety and depression. In comparison with adults, in pediatric patients, CRPS tends to affect the lower extremities and is more common in women between 11 and 12 years of age. In this affected population, several forms of approaches are necessary for adequate treatment.<sup>1,3,4</sup>

Randomized clinical trials for the treatment of CRPS are limited. In general, treatment with medications, including anticonvulsants, antidepressants, and anti-inflammatories, in association with physical, occupational, and psychological therapies is initiated. In specific cases, in the absence of improvement, interventional procedures are indicated, as in the case described.

Peripheral nerve blocks, such as sciatic nerve and saphenous nerve blocks can be performed singularly or in continuous infusion and are useful in the treatment of dysautonomia and sympathetically mediated pain in the lower limbs of patients with CRPS.<sup>3,4</sup> They provide unilateral analgesia, promote a restricted and localized sympathetic and sensory block, and have no effect on bladder or bowel function. Analgesia allows and facilitates the performance of physiotherapy, a fundamental component of the gradual rehabilitation of functional capacity in CRPS.<sup>1,4</sup> In the literature review, there was more emphasis on studies with

continuous blocks,<sup>1</sup> and this study is one of the first cases in which a series of singular blocks were used for pain management in pediatric CRPS, with beneficial results for the patient.

The beneficial effects and safety of glucocorticoids in analgesia are well established. However, controversy continues regarding whether perineurial glucocorticoids have a similar or better analgesic effect than intravenous glucocorticoids. A recent meta-analysis suggested that perineal glucocorticoids have a lower minimum dose and/or provide more effective analgesia than the same intravenous dose.<sup>5</sup>

Dexamethasone, a hydrophilic and nonparticle corticoid, is most commonly used with the effect of prolonging the blockade of peripheral nerves for 6 to 8 hours.<sup>5</sup> Lipophilic glucocorticoids and particulates, such as betamethasone, exhibit efficacy and safety similar to nonparticulates, but with longer durations.

Particulate glucocorticoids in peripheral nerve blocks have been described only in isolated studies that have a lack of safety data. However, the adverse events reported were mainly related to intrathecal injection or intravascular injection, and no complications were reported for peripheral nerve blocks.<sup>5</sup> Moreover, monthly applications may lead to the effects of chronic corticoid use, such as hypertension, insulin resistance, and adrenal insufficiency. In this way, repeating the blockade with the use of corticoids was avoided.

The approach with pharmacological treatment, associated with specific physiotherapy, did not present a satisfactory response in pain control. Only after a sequence of five PSNB in the right popliteal region was it possible to have a gradual improvement of its clinical scenario, changing the course of the disease and allowing the patient to return to his daily activities.

In summary, with the use of ultrasonography, the quality and safety of peripheral nerve blocks were greatly improved, allowing performance in anatomical areas of difficult access. Taking into consideration the possible adverse effects related to the chronic use of corticoids, the PSNB series with a solution of a local anesthetic and corticoids in association with conventional treatment for CRPS in acute and subacute stages is an alternative to be considered to obtain better pain control and facilitate adherence to conventional treatment. In addition, it is important to remember that psychiatric alterations that can be triggered by the condition<sup>4</sup> are fundamental to multidisciplinary follow-up.

## Disclosure

The authors did not receive any specific grants from funding agencies in the public, commercial or non-profit sectors, and did not declare any conflict of interest.

## Declaration of Ethical Approval

This study was approved by the Research and Ethics Committee of Hospital São Domingos (CAAE 35222920.8.0000.5085/Number 4.210.526).

## Informed assent and consent

The patient and his/her guardian have provided a written informed consent form and an informed consent form to present the case.

## Conflicts of interest

The authors declare no conflicts of interest.

## References

1. Everett A, Mclean B, Plunkett A, et al. A unique presentation of complex regional pain syndrome type I treated with a continuous sciatic peripheral nerve block and parenteral ketamine infusion: a case report. *Pain Med.* 2009;10:1136–9.
2. Barbosa FT, Barbosa TR, Cunha RM, et al. Anatomical basis for sciatic nerve block at the knee level. *Rev Bras Anesthesiol.* 2015;65:177–9.
3. Zernikow B, Wager J, Brehmer H, et al. Invasive treatments for complex regional pain syndrome in children and adolescents: a scoping review. *Anesthesiology.* 2015;122:699–707.
4. Logan DE, Williams SE, Carullo VP, et al. Children and adolescents with complex regional pain syndrome: more psychologically distressed than other children in pain? *Pain Res Manag.* 2013;18:87–93.
5. Zorrilla-Vaca A, Li J. Dexamethasone injected perineurally is more effective than administered intravenously for peripheral nerve blocks: a meta-analysis of randomized controlled trials. *Clin J Pain.* 2018;34:276–84.