

## Journal Pre-proof

Use of software to guide the management of intraoperative hemodynamic instability

Marcello Fonseca Salgado-Filho , Rafael Sachetto ,  
Maria José Carvalho Carmona

PII: S0104-0014(21)00393-6  
DOI: <https://doi.org/10.1016/j.bjane.2021.06.028>  
Reference: BJANE 744316



To appear in: *Brazilian Journal of Anesthesiology (English edition)*

Received date: 8 December 2020

Accepted date: 27 June 2021

Please cite this article as: Marcello Fonseca Salgado-Filho , Rafael Sachetto , Maria José Carvalho Carmona , Use of software to guide the management of intraoperative hemodynamic instability, *Brazilian Journal of Anesthesiology (English edition)* (2021), doi: <https://doi.org/10.1016/j.bjane.2021.06.028>

This is a PDF file of an article that has undergone enhancements after acceptance, such as the addition of a cover page and metadata, and formatting for readability, but it is not yet the definitive version of record. This version will undergo additional copyediting, typesetting and review before it is published in its final form, but we are providing this version to give early visibility of the article. Please note that, during the production process, errors may be discovered which could affect the content, and all legal disclaimers that apply to the journal pertain.

© 2021 Published by Elsevier Editora Ltda. on behalf of Sociedade Brasileira de Anestesiologia.  
This is an open access article under the CC BY-NC-ND license  
(<http://creativecommons.org/licenses/by-nc-nd/4.0/>)

BJAN-D-20-00357\_Short Communication

## Use of software to guide the management of intraoperative hemodynamic instability

Marcello Fonseca Salgado-Filho<sup>a,b,\*</sup>, Rafael Sachetto<sup>c</sup>, Maria José Carvalho Carmona<sup>d</sup>

<sup>a</sup> Universidade Federal Fluminense, Niterói, RJ, Brazil

<sup>b</sup> Universidade São Paulo, Faculdade de Medicina, Instituto do Coração, São Paulo, SP, Brazil

<sup>c</sup> Universidade Federal de São João Del-Rei, São João Del-Rei, MG, Brazil

<sup>d</sup> Universidade São Paulo, Faculdade de Medicina, São Paulo, SP, Brazil

### \*Corresponding author.

E-mail: mfonsecasalgado@hotmail.com (M.F. Salgado-Filho).

ORCID ID:

Marcello Fonseca Salgado-Filho –0000-0001-8285-0356

Received 8 December 2020; accepted 27 June 2021

Focused cardiac point-of-care ultrasound is a well-established tool for hemodynamic monitoring during the management of patients admitted to the emergency room, intensive care unit, and operating room.[1-5] The focused cardiac point-of-care ultrasound protocol[1,2,5] comprises the assessment of the preload and filling of the ventricle, the analysis of left ventricle systolic and diastolic function, and the evaluation of right ventricle function.[1-5] Therefore, the protocol assists the decision-making process during the management of hemodynamically unstable patients.

We developed a mobile application (app) for Android<sup>®</sup> platform aiming to facilitate and help anesthesiologists in training to learn how to make decisions during periods of intraoperative hemodynamic instability. The app, named iEcho<sup>®</sup>, is registered with the National Institute of Industrial Property (INPI) under the number: BR 512016001497-0. It is a software developed to facilitate the training of

Comment [RTR(1)]: forename

Comment [RTR(2)]: surname

Comment [RTR(3)]: forename

Comment [RTR(4)]: surname

Comment [RTR(5)]: forename

Comment [RTR(6)]: surname

anesthesiologists in point-of-care cardiac ultrasound, as well as to assist the decision-making process during intraoperative hemodynamic instability.

The app was developed based on flowcharts covering echocardiographic assessments and their clinical interpretations, and it uses pulsed Doppler and tissue Doppler to evaluate left atrial diastolic function and pressure; tissue Doppler to analyze left ventricle function; and the measurement of the left ventricle end-diastolic diameter to assess left ventricle end-diastolic volume. Therefore, it enables the analysis of the left ventricle volume, and its systolic and diastolic functions, and it also suggests treatment options for the hemodynamic unstable patient.

While using the iEcho<sup>®</sup>, the anesthesiologist must observe the following steps (Fig. 1A):

1. Register the patient on the app.
2. With Transthoracic Echocardiogram (TTE), capture the apical 4-chamber view;[1,5] or with Transesophageal Echocardiography (TEE), capture the mid esophageal 4-chamber view.[3] The pulsed Doppler should be positioned at the point of coaptation of the mitral valve leaflets to calculate the velocity of the E wave.[2-4]
3. With Transthoracic Echocardiogram (TTE), capture the apical 4-chamber view,[1,5] or with Transesophageal Echocardiography (TEE), acquire the mid esophageal 4-chamber view.[3] Then, the tissue Doppler is aligned to the lateral mitral annulus, and the velocity of both the lateral E' wave and the lateral S' wave is calculated.[2-4]
4. With the TTE on the parasternal short-axis view[1,5] or the TEE on the transgastric short-axis view,[3] calculate the Left Ventricle End-Diastolic Diameter (LVEDD).[2-4]

After acquiring E wave velocity, E' wave velocity, S wave velocity and LVEDD, the data must be entered on the app (Fig. 1A). Alongside where each parameter is entered, there is a question mark icon (Fig. 1A). When the icon is clicked, a page opens with the technical information required for accurately acquiring the echocardiographic measurements.

When this step is finished and all measurements entered, the app will automatically inform the user whether the left ventricle has normal or decreased contractility, the severity of diastolic dysfunction (normal, Grade 1, 2 or 3 diastolic dysfunction),[4] and will suggest the most appropriate therapy for the patient, depending on the data entered into the software (Figs. 1B and 1C).

The app aims to facilitate the learning process of anesthesiologists who are at the beginning of the learning curve of point-of-care cardiac ultrasound,[5] as well as to

promote clinical interface between the echocardiographic data obtained and the patient's hemodynamic instability, assisting the decision-making process to attain better clinical outcomes.

### **Conflict of Interests**

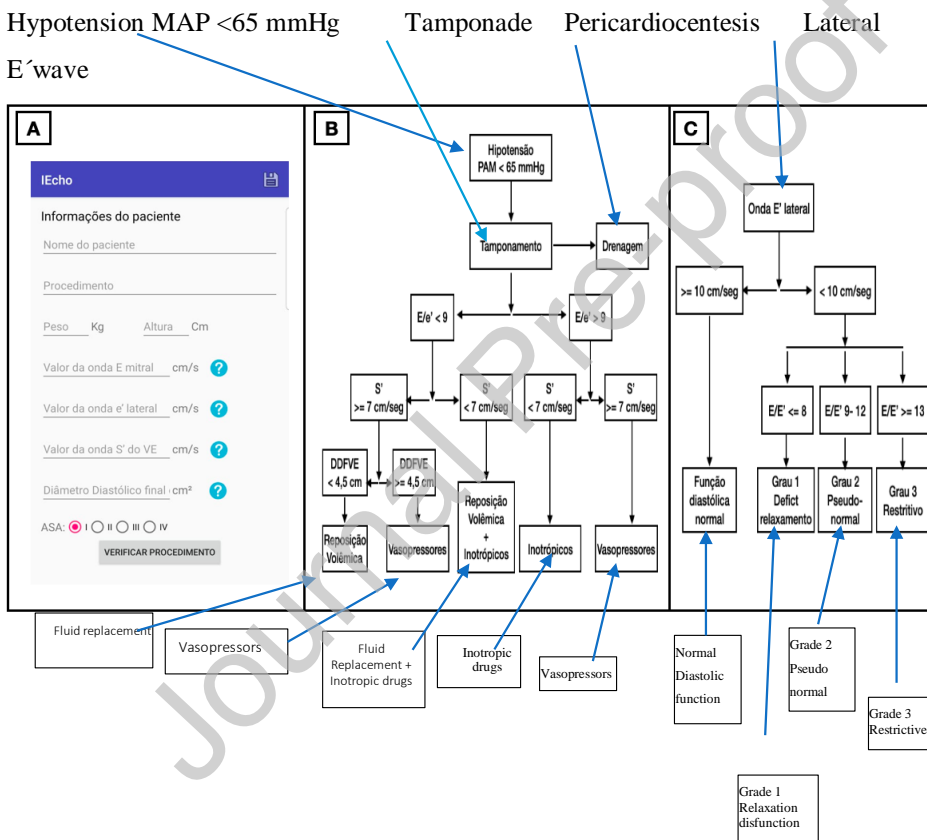
The authors declare no conflicts of interest.

### **References**

1. Holm JH, Frederiksen CA, Juhl-Olsen P, et al. Perioperative use of Focus Assessed Transthoracic Echocardiography (FATE). *Anesth Analg*. 2012;115:1029-32.
2. Porter TR, Shillcutt SK, Adams MS, et al. Guidelines for the use of echocardiography as a monitor for therapeutic intervention in adults: A report from the American Society of Echocardiography. *J Am Soc Echocardiogr*. 2015;28:40-56.
3. Salgado-Filho MF, Morhy SS, Vasconcelos HD, et al. Consenso sobre Ecocardiografia Transesofágica Perioperatória da Sociedade Brasileira de Anestesiologia e do Departamento de Imagem Cardiovascular da Sociedade Brasileira de Cardiologia. *Rev Bras Anesthesiol*. 2018;68:1-32.
4. Nicoara A, Whitener G, Swaminathan M. Perioperative diastolic dysfunction: A comprehensive approach to assessment by transesophageal echocardiography. *Semin Cardiothorac Vasc Anesth*. 2014;18:218-36.
5. Papa FV. Ultrassom cardíaco focado. *Rev Bras Anesthesiol*. 2020;70:288-94.

**Figure 1** A, iEcho<sup>®</sup> app home page with patient demographics to be filled out and the measurement of mitral E wave velocity, lateral mitral annulus E' wave velocity, lateral mitral annulus S' wave velocity, and left ventricular end-diastolic diameter. (B and C) Flowchart depicting the analysis of the diagnosis of hypotension and suggesting treatment automatically delivered by the application software. MAP, Mean Arterial Pressure; E/e', Ratio between mitral E wave velocity and mitral lateral annulus E' wave velocity; S', Velocity of left ventricular contraction represented at the lateral mitral annulus; LVEDD, Left Ventricular End-Diastolic Diameter.

[PLEASE CHANGE THE DISTICKS AS IDENTIFIED]



**A**

**Patient data**

Name of the patient

Procedure

Weight Kg Height cm

Measurement of mitral E wave cm/sec

Measurement of lateral E wave cm/sec

Measurement of LV S wave

End-diastolic diameter cm

ASA I II III IV

**CHECK THE PROCEDURE**

Journal Pre-proof