



CASE REPORT

Pudendal nerve block for circumcision of pediatric patient with Pierre Robin Sequence: case report

Munevver Kayhan, Pinar Kendigelen *, Ayse Cigdem Tutuncu, Guner Kaya

Istanbul University-Cerrahpasa, Cerrahpasa Medical Faculty, Department of Anesthesiology and Intensive Care, Istanbul, Turkey

Received 20 October 2020; accepted 27 June 2021

Available online 16 July 2021

KEYWORDS

Child;
Pierre Robin
syndrome;
Regional anesthesia;
Case report

Abstract Pierre Robin Sequence (PRS) is a congenital condition characterized by micrognathia, glossoptosis, and cleft palate that presents with airway obstruction and developmental delay with or without other congenital anomalies. These patients' anesthesia management is challenging because of difficult ventilation and intubation. Regional anesthesia methods should be considered for these patients on a case-by-case basis. This report presents primary use of regional anesthesia for circumcision of a 9-year-old boy with PRS.

© 2021 Sociedade Brasileira de Anestesiologia. Published by Elsevier Editora Ltda. This is an open access article under the CC BY-NC-ND license (<http://creativecommons.org/licenses/by-nc-nd/4.0/>).

Introduction

Pierre Robin Sequence (PRS) is a congenital condition characterized by micrognathia, glossoptosis, and cleft palate that presents with airway obstruction. This sequence of defects is often accompanied by impaired nutrition, developmental delay, and airway obstruction that is mostly prevalent in the second month of life causing respiratory failure.^{1,2} These features and limited mouth opening complicate each step of airway management, especially mask ventilation and intubation. Difficult airway management and airway obstruction may result in intra- and postoperative respiratory complications. These patients also may be more

sensitive to opioid due to chronic airway obstruction and hypoxia.² Due to an anticipated difficult airway and possibility of opioid sensitivity, possibility of regional anesthesia should be considered in these patients depending on the surgery.

Case report

The patient was a 9-year-boy with PRS who was scheduled for circumcision. The patient was born full-term and had a six-month-long pediatric care unit stay at 4 months of age due to severe respiratory distress, when he needed an emergence tracheostomy after several attempts at difficult intubation and ultimate failure. When he presented for circumcision, he was a 20 kg boy with adenomegaly, a large nose, glossoptosis, high-arched narrow palate, and significant micrognathia (Fig. 1). On preanesthetic exami-

* Corresponding author.

E-mail: pinarken@gmail.com (P. Kendigelen).

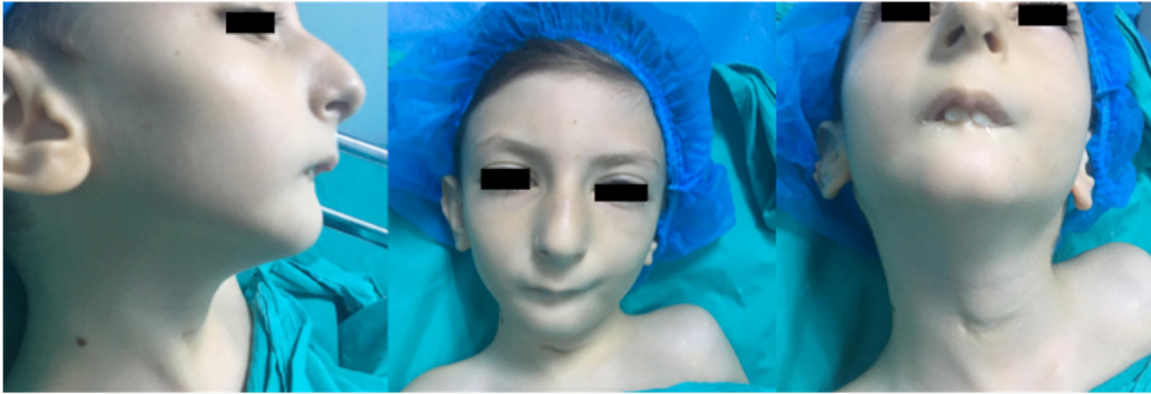


Figure 1 Tracheostomy history of a patient with Pierre Robin Sequence with micrognathia, high palate, mouth opening less than 2 cm.

nation, he had a mouth opening of less than 2 cm, normal neck mobility, and a Mallampati score of 1. The general examination and laboratory tests results were all normal. A high probability of difficult ventilation and intubation commanded an anesthetic plan with regional anesthesia. After discussion with the surgical team, it was planned to perform a pudendal nerve block. The patient, who already had a peripheral intravenous line placed in the ward, was taken to the operating room after premedication with 0.05 mg.kg⁻¹ intravenous midazolam. That dose provided adequate anxiolysis whilst minimizing unwanted airway depression. The patient had standard monitoring (SpO₂, ECG, NIBP) and bispectral index (BIS). The first BIS value was measured as 98. Propofol infusion 50 µg.kg⁻¹.min⁻¹ was started intravenously, and maintenance was based on BIS value between 60–80. The patient was put in lithotomy position and then bilateral pudendal block was performed with a neurostimulator. A total of 10 ml of 0.25% bupivacaine and 0.1 µg.kg⁻¹.min⁻¹ dexmedetomidine was injected. First, surgical incision was made 10 minutes after the block and the patient did not need any other analgesic throughout the operation. The patient received 4 L.min⁻¹ oxygen via Venturi mask. Spontaneous breathing was preserved, and no intervention for airway control was needed. Hemodynamic and respiratory parameters remained stable perioperatively. At the end of a 1-h surgery, the patient was taken to the recovery unit after he regained consciousness and his BIS value was 90. Pain evaluation was done with the FLACC Score at 5th, 15th, 30th, 60th, and 120th minutes and scores remained 0 for the first 2 hours postoperatively. He was then discharged to the ward for a 24-h postanesthetic follow-up and did not need any additional analgesia.

Discussion

Airway management makes the anesthetic plan for Pierre Robin Sequence patients very challenging. Preanesthetic airway evaluation must be done carefully with close attention to mouth opening, dental structures, Mallampati score, neck circumference, neck extension, tonsils, palate, and previous tracheostomy scars. Difficult airway management should be expected on the day of surgery. When the surgical plan is suitable, choosing regional anesthesia over

general anesthesia for patients with likely difficult airways can minimize anesthetic risks. Pediatric Regional Anesthesia Network (PRAN) emphasizes the rise in the use and safety of regional anesthesia in children in recent studies.³ Circumcision is one of the most frequent penile surgeries and is commonly performed as day surgery. Analgesia options for this painful procedure include intravenous analgesia, caudal block, penile block, and pudendal nerve block.⁴ Caudal block is a safe and commonly performed neuraxial anesthesia, however it carries the risk of requiring general anesthesia, though at a small rate. The success rate of penile block can vary and hence its use may require general anesthesia. It is preferred to perform pudendal nerve block due to its higher success rate compared to penile block and better safety profile compared to caudal block. Recent studies show that pudendal nerve block provides better analgesia in hypospadias surgery than caudal block.⁵ The pudendal nerve derives from second, third, and fourth roots of sacral plexus. Inside the pudendal canal, the nerve first gives off inferior rectal (anal) nerves, and then divides into perineal nerve and the dorsal nerve of the penis/clitoris. There are different anatomical approaches (transvaginal, transperineal, perirectal), and also different techniques (anatomical landmark, using nerve stimulator, and ultrasound guided) for performing pudendal nerve block. In this report, a perirectal approach with the nerve stimulator in the lithotomy position was chosen. Injection point and direction is more lateral from anus and rectum, therefore structural injury risk is low in this technique.^{4,5} Bleeding, hematoma, mucosal laceration, and infection are potential complications, especially with the transvaginal approach. As in the other blocks, there is a risk of intravascular local anesthetic injection and systemic local anesthetic toxicity. Motor block and sphincter functional dysfunction can be rarely observed after caudal block but has not been reported after pudendal block.⁵ Supplementary administration of propofol infusion with BIS monitoring allowed us to manage the surgical period without causing anxiety in the pediatric patient. Furthermore, not only did using dexmedetomidine as an additive for the block increased the analgesic time, but it may also have contributed to sedation intraoperatively and postoperatively. There was no need for opioids. Pudendal nerve block for circumcision provided a comfortable intraoperative and postoperative period for the patient with adequate

analgesia and no anxiety. In patients with anticipated difficult airway, such as Pierre Robin Sequence patients, regional anesthesia methods should be considered depending on the surgery.

Conflicts of interest

The authors declare no conflicts of interest.

References

1. Templeton TW, Goenaga-Díaz EJ, Runyan CM, et al. A generalized multistage approach to oral and nasal intubation in infants with Pierre Robin sequence: a retrospective review. *Pediatric Anesthesia*. 2018;28:1029–34.
2. Cladis F, Kumar A, Grunwaldt L, et al. Pierre Robin Sequence: a perioperative review. *Anesth Analg*. 2014;119:400–12.
3. Walker BJ, Long JB, Sathyamoorthy M, et al. Complications in pediatric regional anesthesia an analysis of more than 100,000 blocks from the pediatric regional anesthesia network. *Anesthesiology*. 2018;129:721–32.
4. Tutuncu AC, Kendigelen P, Ashyyeralyeva G, et al. Pudendal nerve block versus penile nerve block in children undergoing circumcision. *Urol J*. 2018;15:109–15.
5. Kendigelen P, Tutuncu AC, Emre S, et al. Pudendal versus caudal block in children undergoing hypospadias surgery: a randomized controlled trial. *Reg Anesth Pain Med*. 2016;41:610–5.