

## ORIGINAL INVESTIGATION

## Bilateral versus unilateral erector spinae plane block for postoperative analgesia in laparoscopic cholecystectomy: a randomized controlled study



Sevim Cesur <sup>b</sup>, Hadi Ufuk Yörükoğlu <sup>a,\*</sup>, Can Aksu<sup>b</sup>, Alparslan Kuş<sup>b</sup>

<sup>a</sup> Bitlis Tatvan State Hospital, Clinic of Anesthesiology and Reanimation

<sup>b</sup> Kocaeli University, School of Medicine, Department of Anesthesiology and Reanimation, Kocaeli, Turkey

Received 12 May 2020; accepted 2 April 2021

Available online 28 April 2021

### KEYWORDS

Nerve Block;  
Ultrasound Imaging;  
Erector Spinae Plane  
Block;  
Laparoscopic  
Cholecystectomy;  
Analgesia

### Abstract

**Introduction:** Laparoscopic cholecystectomy (LC) is the common surgical intervention for benign biliary diseases. Postoperative pain after LC remains as an important problem, with two components: somatic and visceral. Trocar entry incisions lead to somatic pain, while peritoneal distension with diaphragm irritation leads to visceral pain. Following its description by Forero et al., the erector spinae plane (ESP) block acquired considerable popularity among clinicians. This led to the use of ESP block for postoperative pain management for various operations.

**Materials and methods:** This study was conducted between January and June 2019. Patients aged between 18 and 65 years with an American Society of Anesthesiologists (ASA) physical status I–II, scheduled for elective laparoscopic cholecystectomy were included in the study. All the patients received bilateral or unilateral ESP block at the T8 level preoperatively according to their groups.

**Results:** There was no significant difference between the groups in terms NRS scores either at rest or while coughing at any time interval except for postoperative 6<sup>th</sup> hour ( $p = 0.023$ ). Morphine consumption was similar between the groups but was significantly lower in group B at 12 and 24 hours ( $p = 0.044$  and  $p = 0.022$ , respectively). Twelve patients in group A and three patients in group B had shoulder pain and this difference was statistically significant ( $p = 0.011$ ).

**Discussion:** In conclusion, bilateral ESP block provided more effective analgesia than unilateral ESP block in patients undergoing elective LC. Bilateral ESP block reduced the amount of opioid consumption and the incidence of postoperative shoulder pain.

© 2021 Sociedade Brasileira de Anestesiologia. Published by Elsevier Editora Ltda. This is an open access article under the CC BY-NC-ND license (<http://creativecommons.org/licenses/by-nc-nd/4.0/>).

\* Corresponding author.

E-mail: [ufukyurukoglu@gmail.com](mailto:ufukyurukoglu@gmail.com) (H.U. Yörükoğlu).

<https://doi.org/10.1016/j.bjane.2021.04.020>

© 2021 Sociedade Brasileira de Anestesiologia. Published by Elsevier Editora Ltda. This is an open access article under the CC BY-NC-ND license (<http://creativecommons.org/licenses/by-nc-nd/4.0/>).

## Introduction

Laparoscopic cholecystectomy (LC) is the common surgical intervention for benign biliary diseases. Postoperative pain after LC remains as an important problem,<sup>1</sup> with two components, somatic and visceral. Trocar entry incisions lead to somatic pain, while peritoneal distension with diaphragm irritation causes visceral pain.<sup>2</sup>

Following its description by Forero et al.,<sup>3</sup> the erector spinae plane (ESP) block acquired considerable popularity among clinicians for its effectiveness, ease of application, and relatively low risk of complications. This has led to the use of ESP block for postoperative pain management for various operations.<sup>4</sup>

In contrast to many other interfascial plane blocks, there is some evidence that the ESP block is effective both against visceral and somatic pain.<sup>5</sup> Several studies have shown that the ESP block provides adequate postoperative analgesia for LC.<sup>6,7</sup> However, it is unclear whether the block needs to be performed bilaterally, as some authors believe that the major component of postoperative pain after LC derives from the tissue trauma during gall bladder resection that can be prevented using a unilateral regional anesthesia technique.<sup>8</sup>

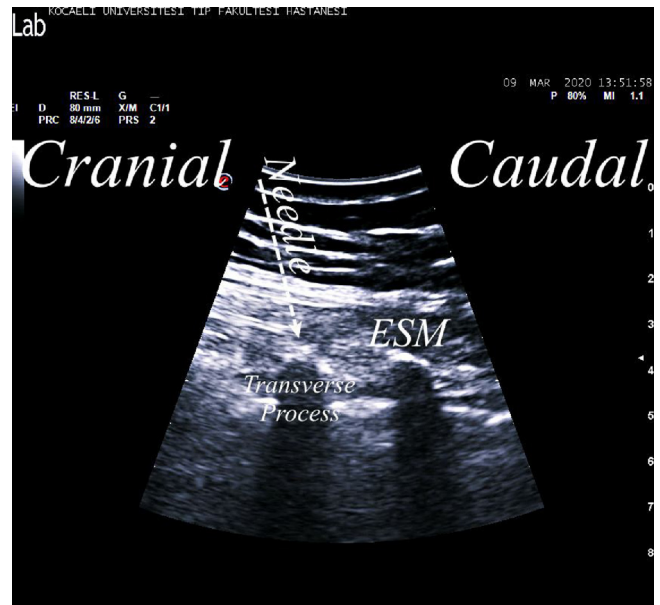The aim of the study was to compare the analgesic efficacy of unilateral versus bilateral ESP block in patients undergoing LC. The primary outcome measure was morphine consumption at the postoperative 24<sup>th</sup> hour. Secondary outcome measure was to compare pain scores, incidences of shoulder pain, nausea and vomiting, and patient's satisfaction.

## Methods

This study was conducted between January and June 2019. It was approved by the Kocaeli University Clinical Trials Ethical Committee (KIA 2018/488) and registered with clinicaltrials.gov (NCT03781687). Written informed consent was obtained from the patients.

Patients aged between 18 and 65 years, with an American Society of Anesthesiologists (ASA) physical status I–II, and scheduled for elective laparoscopic cholecystectomy were included in the study. Patients with obesity (body mass index > 35 kg.m<sup>-2</sup>), infection of the skin at the site of needle puncture area, known allergies to any of the study drugs, coagulopathy, recent use of opioid drugs, or inability to communicate with the investigators were excluded from the study.

Patients were randomly allocated to two groups: Group A (Unilateral) and Group B (Bilateral). The sequence was done using [www.random.org](http://www.random.org) and the allocation sequence was concealed in sealed opaque envelopes, which indicated the treatment to be assigned to the patient. All the patients received preoperative bilateral or unilateral ESP block at the T8 level preoperatively according to their groups. All the blocks have been done 20 minutes before the surgery in a separate block room. All blocks were performed by experienced anesthesiologists with no involvement in patients' perioperative follow-up and data collection processes.



**Figure 1** Ultrasound image of erector spinae plane block. ESM, erector spinae muscle.

## ESP technique

All patients were premedicated with midazolam 0.03 mg.kg<sup>-1</sup> IV (intravenous). Blocks were performed in the prone position with standard monitoring. An Esaote My Lab 6 US machine (Florence, Italy) with a convex probe (1–8 MHz) and a 22G, 80-mm, insulated facet type needle (B Braun Sonoplex, Melsungen, Germany) were used for all block applications.

After appropriate skin disinfection, the probe was placed longitudinally 3 cm lateral to the T8 level. Following identification of the transverse process and erector spinae muscle, the needle was inserted with in-plane approach from cranial to caudal direction (Fig. 1). Bupivacaine 0.25% (20 mL) was administered on the right side in group A patients and bilaterally at the T8 level in group B patients. The spread of the injectate beneath the erector spinae muscle was visualized in both the cranial and caudal directions.

## General anesthesia

Following monitoring of SpO<sub>2</sub>, ECG and noninvasive blood pressure, anesthesia was induced with propofol (2–3 mg.kg<sup>-1</sup>), fentanyl (1 mcg.kg<sup>-1</sup>) and rocuronium (0.6 mg.kg<sup>-1</sup>). Desflurane in combination with nitrous oxide in oxygen at a ratio of 2:1 was used for anesthesia maintenance. Pneumoperitoneum was created with carbon-dioxide and maintained at a range of 10–12 mm Hg. At the end of the surgery, tramadol 100 mg and paracetamol 1 g IV were administered. Ondansetron 8 mg IV was also administered to prevent postoperative nausea and vomiting.

Patients were also provided with a patient controlled analgesia (PCA) device containing 0.5 mg.mL<sup>-1</sup> morphine set to deliver a 1 mg bolus dose, with an 8-minute lock out time and an 1-hour limit of 6 mg. Rescue analgesia using tenoxicam 20 mg IV was planned if NRS was > 3.

**Table 1** Demographic data.

	Group A (n = 45)	Group B (n = 45)	p
Age (year)	52.2 ± 12.5	53.31 ± 10.17	0.868
Sex (M/F)	13/32	14/31	0.819
Height (cm)	163.68 ± 8.44	163.35 ± 8.25	0.977
Weight (kg)	77.17 ± 15.26	81.2 ± 14.15	0.242
ASA status (I/II)	24/21	23/22	0.834
Duration of surgery (min)	64.55 ± 15.44	69 ± 21.91	0.420

Data are presented as mean ± SD and patient numbers.

**Table 2** NRS scores in rest and while coughing at the postoperative 1<sup>st</sup>, 6<sup>th</sup>, 12<sup>th</sup>, 24<sup>th</sup> hour.

	Group A (n = 45)	Group B (n = 45)	p <sup>a</sup>
NRS scores in rest			
1 <sup>st</sup> hour	2.00 (0.00-4.00)	2.00 (1.00-4.00)	0.889
3 <sup>rd</sup> hour	2.00 (0.00-2.00)	1.00 (0.00-2.00)	0.334
6 <sup>th</sup> hour	1.00 (0.00-2.00)	1.00 (0.00-2.00)	0.643
12 <sup>th</sup> hour	0.00 (0.00-1.00)	0.00 (0.00-1.50)	0.505
24 <sup>th</sup> hour	0.00 (0.00-1.00)	0.00 (0.00-1.00)	0.809
NRS scores while coughing			
1 <sup>st</sup> hour	2.00 (1.00-5.00)	3.00 (2.00-4.00)	0.440
3 <sup>rd</sup> hour	2.00 (1.00-4.00)	2.00 (0.00-2.50)	0.228
6 <sup>th</sup> hour	1.00 (0.00-2.00)	0.00 (0.00-1.50)	<b>0.048<sup>a</sup></b>
12 <sup>th</sup> hour	0.00 (0.00-2.00)	0.00 (0.00-2.00)	0.442
24 <sup>th</sup> hour	0.00 (0.00-1.00)	0.00 (0.00-1.00)	0.909

Data are presented as median (25–75 percentile).

<sup>a</sup>  $p < 0.05$ , (Mann-Whitney U test).

Morphine consumptions and NRS scores both at rest and while coughing were recorded at postoperative hours 1, 3, 6, 12 and 24. The incidences of shoulder pain, nausea, and vomiting in the postoperative first 24 hours were also recorded. Patients were asked if they were satisfied with the anesthesia technique using a 6-point satisfaction score system (0 = not at all satisfied, 5 = very satisfied) and whether or not they would choose this technique again. A blinded pain nurse performed postoperative follow-up of patients and collected the data. Analyses of all data were performed by other researchers that were blinded to the groups.

### Statistical analysis

In a previous study conducted in our clinic, mean morphine consumption among patients undergoing unilateral ESP block for LC at the T8 level was  $7.5 \pm 5.8$  mg (6). We calculated that for 80% power and an error of 0.05, the required sample size to detect a 40% difference in morphine consumption at 24 hours after the surgery would be 43 patients per group. We finally included 46 patients in each group in case of dropouts.

All statistical analyses were performed using the IBM SPSS for Windows version 20.0 (IBM Corp., Armonk, NY, USA) software. Kolmogorov-Smirnov test was used to assess the assumption of normality.

Continuous variables were presented depending on normal distribution with either mean ± standard deviation or (in case of no normal distribution) median (25<sup>th</sup>–75<sup>th</sup>

percentile). Categorical variables were summarized as counts (percentages). Comparisons of continuous variables between groups were carried out using independent samples *t*-test/ Mann-Whitney U test, whichever was appropriate. Association between two categorical variables was examined by Chi-square test. A value of  $p < 0.05$  was considered statistically significant.

### Results

Figure 2 shows the Consort diagram of enrollment for this study. Ninety-two patients were randomly assigned to either group A or B. Two patients were excluded from the study. One patient refused to undergo block after the enrollment and one patient was excluded due to conversion to open cholecystectomy.

The groups were comparable in terms of demographic data and duration of surgery (Table 1).

There was no significant difference between the groups in terms of NRS scores either at rest or while coughing at any time interval except for the postoperative 6<sup>th</sup> hour ( $p = 0.023$ ) (Table 2). Morphine consumption was similar between the groups but was significantly lower in group B at 12 and 24 hours ( $p = 0.044$  and  $p = 0.022$ , respectively) (Table 3). Twelve patients in group A and three patients in group B had shoulder pain, and this difference was statistically significant ( $p = 0.011$ ) (Table 4). Nausea and vomiting were similar between the groups (Table 4).

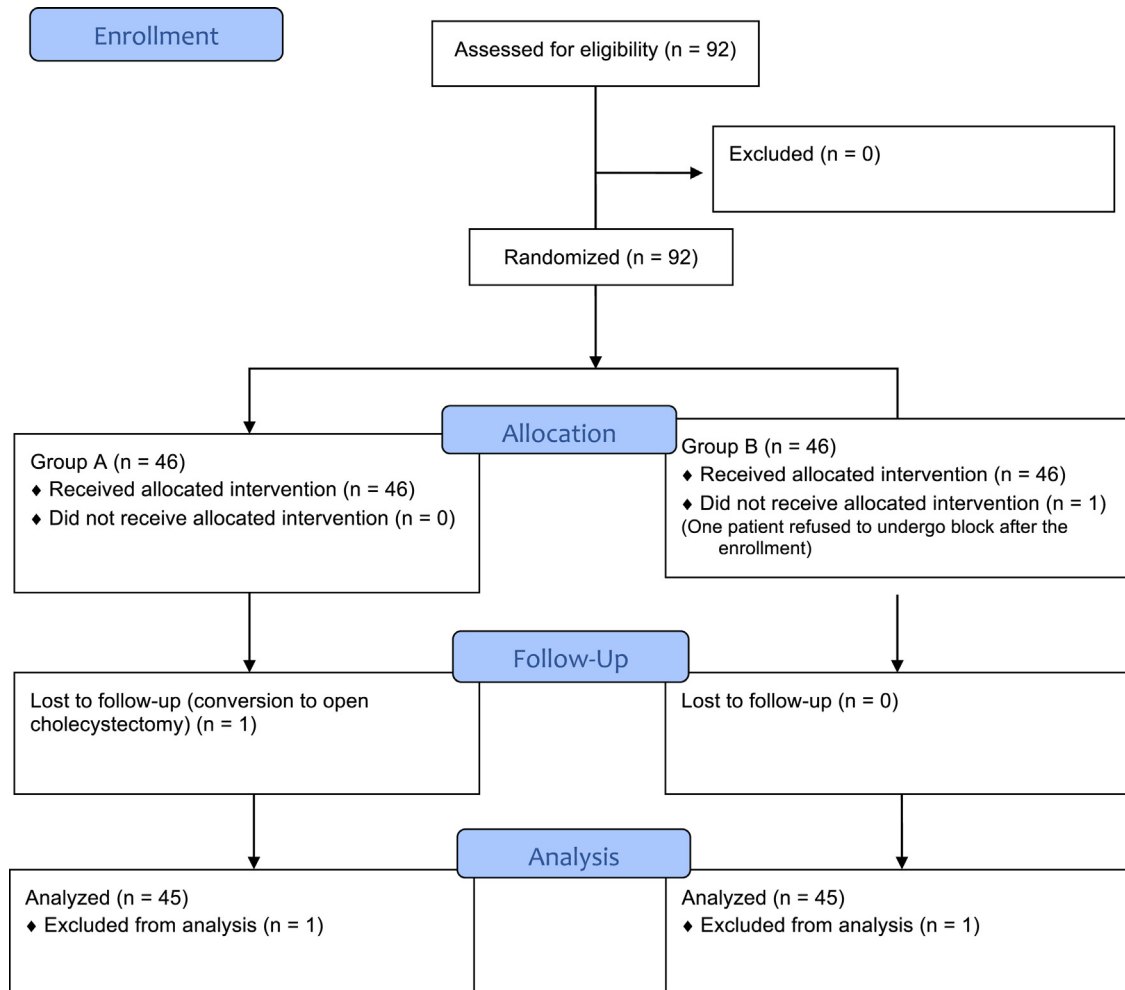


Figure 2 Consort flow diagram.

Table 3 Morphine consumptions at the postoperative 1<sup>st</sup>, 6<sup>th</sup>, 12<sup>th</sup>, 24<sup>th</sup> hour.

	Group A (n = 45)	Group B (n = 45)	p
Morphine consumption (mg)			
1 <sup>st</sup> hour	1.11 ± 0.57	1.15 ± 0.79	0.280
3 <sup>rd</sup> hour	2.77 ± 1.67	2.73 ± 2.01	0.617
6 <sup>th</sup> hour	4.95 ± 3.32	3.82 ± 2.87	0.431
12 <sup>th</sup> hour	6.68 ± 4.86	5.08 ± 3.37	<b>0.044*</b>
24 <sup>th</sup> hour	8.28 ± 5.79	6.08 ± 3.66	<b>0.022*</b>

Data are presented as mean ± SD.

\* 0.05, (Mann-Whitney U test).

No complications related to block procedures were observed.

## Discussion

The study findings showed that the bilateral ESP block reduced total morphine consumption at postoperative hours 12 and 24, while total morphine consumption decreased by 26% compared to the unilateral block. Furthermore, bilat-

eral ESP block reduced the incidence of shoulder pain ( $p = 0.011$ ).

Laparoscopic technique for cholecystectomy is becoming more popular than open technique as it leads to less surgical trauma, better tissue healing, and faster recovery. Although it is a minimally invasive surgery, pain after LC still stands as a problem to solve and has multiple components like surgical manipulations, visceral pain, subdiaphragmatic irritation.<sup>9</sup> There is also a somatic component due to abdominal thoracars. The PROSPECT Working Group recommends the use of non-steroidal inflammatory drugs (NSAIDs), paracetamol

**Table 4** Incidences of shoulder pain, nausea and vomiting, and patients' satisfaction scores.

	Group A (n = 45)	Group B (n = 45)	p
Shoulder pain, n (%)			
Yes	12 (80.0)	3 (20.0)	0.011 <sup>a</sup>
No	33 (44.0)	42 (56.0)	
Nausea, n (%)			
Yes	11 (57.9)	8 (42.1)	0.441
No	34 (47.9)	37 (52.1)	
Vomiting, n (%)			
Yes	7 (58.3)	5 (41.7)	0.756
No	38 (48.7)	40 (51.3)	
Satisfaction scores, n (%)			
0	0 (0.0)	0 (0.0)	0.955
1	2 (4.4)	2 (4.4)	
2	2 (4.4)	0 (0.0)	
3	4 (8.9)	6 (13.3)	
4	8 (17.9)	8 (17.9)	
5	29 (64.4)	29 (64.4)	
Total	45 (100.0)	45 (100.0)	

Data are presented number of patients and %.

<sup>a</sup>  $p < 0.05$ , (Chi-square test).

and local anesthetic infiltration to the port insertion site for routine analgesia, and opioid drugs for rescue analgesia.<sup>10</sup> However, according to the results of a recently published meta-analyses about the pharmacological methods used for analgesia after LC, effectiveness of paracetamol and NSAIDs has low quality of evidence while intravenous ketamine, opioids and pregabalin has moderate to high quality evidence.<sup>9</sup> Either way, regional anesthesia techniques should be performed as a component of multimodal analgesia to prevent inadequate treatment of postoperative pain, if possible.<sup>10</sup> Studies have investigated the use of the transversus abdominis plane (TAP) block with different techniques in LC.<sup>11,12</sup> However, the results are inconsistent. With the TAP block, cutaneous fibers and sometimes also parietal components of the parietal peritoneum are blocked. This technique is therefore not effective for visceral pain, and its use is still controversial.

Thoracic paravertebral block (TPVB) may be another alternative regional anesthesia technique for postoperative analgesia. Studies have reported the successful use of bilateral TPVB with both US guidance and nerve stimulation in LC.<sup>13,14</sup> However, TPVB is an advanced technique, either with US guidance or with nerve stimulation, because of the proximity of the pleura to the paravertebral space and the potential risk of hemodynamic complications. This particularly accounts for the popularity of the ESP block and its use by many clinicians as a replacement for TVPB. The ESP block affects both visceral and somatic pain fibers.<sup>5</sup> On the other hand, lower potential risks of complications make this technique preferable for LC. Tulgar et al.<sup>7</sup> reported that bilateral ESP block at the T9 level provided effective analgesia in LC. Similarly, a previous study from our clinic, showed that adequate analgesia was provided with unilateral ESP block at

the T8 level.<sup>6</sup> Additionally, effective analgesia with bilateral ESP block after LC in pediatric patients has also been reported in literature.<sup>15</sup>

In laparoscopic abdominal surgeries, nerve fibers responsible for the somatic pain arises from T6–L2, and visceral pain derives from the structures involved in the surgery.<sup>2</sup> According to cadaver studies of ESP block, the injection of 20 mL of drug may result in a widespread from T1 to L1.<sup>16,17</sup> De Cassai et al.<sup>18</sup> reported that the injection spread in the ESP block requires different volumes of injection according to the site of injection. In the thoracic region 3.3 (radiological studies) and 3.5 (cadaveric dissection) mL were needed when ESP block was performed, 5 mL of injectate was needed to cover a vertebral level in the lumbar region.

It is expected that performing ESP block at T8 with 20 mL of local anesthetic will be sufficient for laparoscopy. However, the major component of postoperative pain after LC may be tissue trauma during gall bladder resection that can be prevented with a unilateral regional anesthesia technique.<sup>8</sup> In this study, patients were satisfied with the analgesia provided by unilateral injection. Nevertheless, bilateral ESP block was more effective than unilateral injection. Bilateral block may be painful for some patients, but bilateral ESP block can be performed with a single needle entry from the midline to reduce this pain.<sup>19</sup>

High pneumoperitoneum pressures may increase the incidence of postoperative shoulder pain.<sup>10</sup> Aspirating residual gas at the end of the operation has also been shown to reduce postoperative shoulder pain.<sup>10</sup> In this study, pneumoperitoneum was maintained at a range of 10–12 mm Hg. Pneumoperitoneum gas was aspirated after completion of the operative procedures. A previous study from our clinic,<sup>6</sup> reported that unilateral ESP block reduced postoperative shoulder pain, and the present study shows that bilateral ESP block is more effective in reducing postoperative shoulder pain.

There are a number of limitations to this study. No sham block was performed on at the contralateral side in the unilateral group patients, and the placebo effect is unclear. As discussed previously, the mechanism of the ESP block still remains unclear. It has also been reported that unilateral ESP block may result in bilateral sensory blockade,<sup>20</sup> and performing sham block on the contralateral side would have affected the drug spread or concentration.

In conclusion, bilateral ESP block provided more adequate analgesia than unilateral ESP block in patients undergoing elective LC. Bilateral ESP block also reduced the amount of opioid consumption and the incidence of postoperative shoulder pain.

## Conflicts of interest

The authors declare no conflicts of interest.

## Acknowledgements

Informed consent was obtained from all individual participants included in the study.

All procedures involving human participants were performed in accordance with the ethical standards of the institute-ional and/or national research committee and with

the 1964 Helsinki Declaration and its later amendments or comparable ethical standards.

## References

- Rosero EB, Joshi GP. Hospital readmission after ambulatory laparoscopic cholecystectomy: incidence and predictors. *J Surg Res.* 2017;219:108–15.
- Chin KJ, McDonnell JG, Carvalho B, et al. Essentials of our current understanding: abdominal wall blocks. *Reg Anesth Pain Med.* 2017;42:133–83.
- Forero M, Adhikary SD, Lopez H, et al. The erector spinae plane block: a novel analgesic technique in thoracic neuropathic pain. *Reg Anesth Pain Med.* 2016;41:621–7.
- De Cassai A, Bonvicini D, Correale C, et al. Erector spinae plane block: a systematic qualitative review. *Minerva Anesthesiol.* 2019;85:308–19.
- Chin KJ, Adhikary S, Sarwani N, et al. The analgesic efficacy of pre-operative bilateral erector spinae plane (ESP) blocks in patients having ventral hernia repair. *Anaesthesia.* 2017;72:452–60.
- Aksu C, Kus A, Yorukoglu HU, et al. The effect of erector spinae plane block on postoperative pain following laparoscopic cholecystectomy: a randomized controlled study. *Anestezi Derg.* 2019;27:9–14.
- Tulgar S, Kapakli MS, Senturk O, et al. Evaluation of ultrasound-guided erector spinae plane block for postoperative analgesia in laparoscopic cholecystectomy: a prospective, randomized, controlled clinical trial. *J Clin Anesth.* 2018;49:101–6.
- Ekstein P, Szold A, Sagie B, et al. Laparoscopic surgery may be associated with severe pain and high analgesia requirements in the immediate postoperative period. *Ann Surg.* 2006;141:41–6.
- Eftekhariyazdi M, Ansari M, Darvishi-Khezri H, et al. Pharmacological methods of postoperative pain management after laparoscopic cholecystectomy: a review of meta-analyses. *Surg Laparosc Endosc Percutan Tech.* 2020;30:534–41.
- Barazanchi AWH, MacFater WS, Rahiri JL, et al. Evidence-based management of pain after laparoscopic cholecystectomy: a PROSPECT review update. *Br J Anaesth.* 2018;121:787–803.
- Ortiz J, Suliburk JW, Wu K, et al. Bilateral transversus abdominis plane block does not decrease postoperative pain after laparoscopic cholecystectomy when compared with local anesthetic infiltration of trocar insertion sites. *Reg Anesth Pain Med.* 2012;37:188.
- Ma N, Duncan JK, Scarfe AJ, et al. Clinical safety and effectiveness of transversus abdominis plane (TAP) block in post-operative analgesia: a systematic review and meta-analysis. *J Anesth.* 2017;31:432–52.
- Aydin G, Aydin O. The efficacy of ultrasound-guided paravertebral block in laparoscopic cholecystectomy. *Medicina.* 2018;54:75.
- Naja ZM, El-Rajab M, Ziade F, et al. Preoperative vs. postoperative bilateral paravertebral blocks for laparoscopic cholecystectomy: a prospective randomized clinical trial. *Pain Pract.* 2011;11:509–15.
- Aksu C, Gurkan Y. Ultrasound-guided bilateral erector spinae plane block could provide effective postoperative analgesia in laparoscopic cholecystectomy in paediatric patients. *Anaesth Crit Care Pain Med.* 2019;38:87–8.
- Adhikary SD, Bernard S, Lopez H, et al. Erector spinae plane block versus retrolaminar block: a magnetic resonance imaging and anatomical study. *Reg Anesth Pain Med.* 2018;43:756–62.
- Ivanusic J, Konishi Y, Barrington MJ. A Cadaveric Study Investigating the mechanism of action of erector spinae blockade. *Reg Anesth Pain Med.* 2018;43:567–71.
- De Cassai A, Andreatta G, Bonvicini D, et al. Injectate spread in ESP block: a review of anatomical investigations. *J Clin Anesth.* 2020;61:109669.
- Yorukoglu HU, Aksu C, Kılıc CT, et al. Bilateral erector spinae plane block with single injection. *J Clin Monit Comput.* 2019;33:1145–6.
- Tulgar S, Selvi O, Ahiskalioglu A, et al. Can unilateral erector spinae plane block result in bilateral sensory blockade? *Can J Anesth.* 2019;66:1001–2.