

LETTERS TO THE EDITOR

Blood-soft tissue barrier breach and soft tissue recoil pressure on local anesthetic: two physiological mechanisms for local anesthetic systemic toxicity



Dear Editor,

Local Anesthetics (LA) are safe when limited to the site of therapy, such as tissue infiltration near a nerve or a plexus. However, if a large amount of LA reaches the systemic circulation, supra-therapeutic blood levels can cause Local Anesthetic Systemic Toxicity (LAST). Variables that increase the risk of toxicity include the type and dose of LA, site of injection, patient's age and comorbidities, and muscle mass.¹ The transit of LA into the blood may be due to inadvertent intravascular injection or vascular uptake from local spread.

We hypothesize two physiological mechanisms which may contribute to LAST.

- 1 Breach of blood–soft tissue barrier due to multiple needle punctures.

Regional anesthesia may require multiple needle punctures to confirm proper needle placement. This may breach the blood–soft tissue barrier due to direct microvascular injury leading to opening of low-pressure vessels (capillaries, venules, and veins). The vascular uptake from local spread gets exaggerated following breach in blood-soft tissue barrier.

- 2 Elastic recoil force of soft tissue builds a pressure surrounding the capillaries after injection of the LA (Fig. 1).

Injection of the fluid into soft tissue creates a small pocket of free fluid, the pressure in this isolated pocket of fluid is measured as interstitial fluid pressure. Brace et al.² used the needle technique to detect negative pressure in the tissue space if no fluid was injected. However, positive pressure was detected when fluid was injected. This changes in interstitial fluid pressures were in accordance with Starling's hypothesis. This pressure corresponds to the total tissue pressure, which is the sum of fluid and solid pressure. There is a constant absorption of the fluid from the created pocket of free fluid into the surrounding tissues,

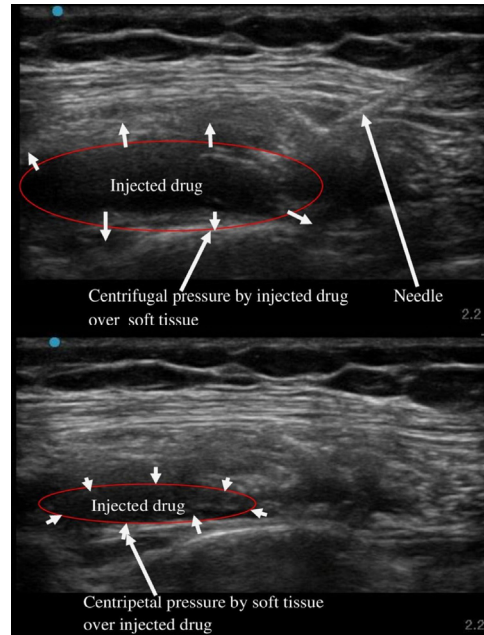


Figure 1 Soft tissue recoil force over the injected LA.

indicating that the fluid pressure in the surrounding tissues is more negative than in the pocket of free fluid.² The recoil pressure depends upon volume and site of injection, besides the elastance of tissue near the nerve. Whenever pressure surrounding the capillaries after injection of the LA exceeds the capillary pressure, then it would cause increased convective flux of LA due to increased inward interstitial fluid pressure gradient.

The two mechanisms above might also explain the mechanism of LAST despite negative blood aspiration before drug injection even at submaximal doses. Aydin³ detected unexpected LAST during the Ultrasonography-Guided (USG) peripheral nerve block despite negative blood aspiration before injecting the drug. The exact cause of LAST in this case was not found out. The possible cause behind rapid absorption of LA into the system circulation could have been multiple needle punctures while using peripheral nerve stimulator before USG drug injection. The maneuver of aspiration prior to injection can yield a false negative result in 2% of the population.¹

We would require contrast-enhanced ultrasound LA spread,⁴ ultrasound microbubble behavior and sonoporation study or targeted microbubbles for molecular imaging study

to validate our hypothesis.⁵ There is no facility to do contrast enhanced local anesthetic spread in the animal or human models at our centre. Hence, further studies might be required to validate our hypothesis.



Conflicts of interest

The authors declare no conflicts of interest.

References

1. Wolfe JW, Butterworth JF. Local anesthetic systemic toxicity: update on mechanisms and treatment. *Curr Opin Anaesthesiol.* 2011;24:561–6.
2. Brace RA, Guyton AC, Taylor AE. Reevaluation of the needle method for measuring interstitial fluid pressure. *Am J Physiol.* 1975;229:603–7.
3. Aydin G. Unexpected local anesthesia toxicity during the ultrasonography-guided peripheral nerve block. *J Clin Anesth.* 2018;50:26.

4. Sasaki H, Yamauchi M, Ninomiya T, Tatsumi H, Yamakage M. Possible utility of contrast-enhanced ultrasonography for detecting spread of local anesthetic in nerve block. *J Anesth.* 2017;31:365–73.
5. Lee H, Kim H, Han H, et al. Microbubbles used for contrast enhanced ultrasound and theragnosis: a review of principles to applications. *Biomed Eng Lett.* 2017;7:59–69.

Amarjeet Kumar ^a, Chandni Sinha ^{b,*}, Ajeet Kumar^b

^a *Department of Trauma & Emergency, All India Institute of Medical Sciences, Patna, India*

^b *Department of Anaesthesiology, All India Institute of Medical Sciences, Patna, India*

* Corresponding author.

E-mail: drchandnis@aiimspatna.org (C. Sinha).

Received 26 February 2021; accepted 17 April 2021

<https://doi.org/10.1016/j.bjane.2021.04.016>

0104-0014/ © 2021 Sociedade Brasileira de Anestesiologia.

Published by Elsevier Editora Ltda.

Quadratus lumborum block in supine position for postoperative pain management in acetabular fracture surgeries: cadaveric and clinical experience

Dear Editor,

We read with interest the case report by Sandeep Diwan et al on supine coronal midaxillary approach to anterior quadratus lumborum block (SCAQLB).¹ Acetabular fractures are usually painful medical conditions. Positioning the patient for regional anesthesia is challenging due to the localiza-



tion of the fracture and severe pain. Quadratus lumborum block (QLB) in supine position gives advantageous in acetabular fracture surgeries for being both easily applicable and potentially effective in postoperative pain management.

In our clinical practice we started to utilize QLB in supine position for acetabular fracture surgeries with a methodology explained by Blanco et al. since 2019 in caesarean section cases.² After seeing the effectiveness of it first in four clinical cases, we investigated the distribution of local anesthetic in a fresh cadaver.³ According to the results of cadaver dissection, we observed that there was no dyeing in the sacral plexus region. On contrast the branches of the lumbar plexus which are femoral nerve, ilioinguinal nerve, lateral femoral cutaneous were dyed (Fig. 1). This spread of methylene blue dye may explain the mechanism of effectiveness of QLB in acetabular region.

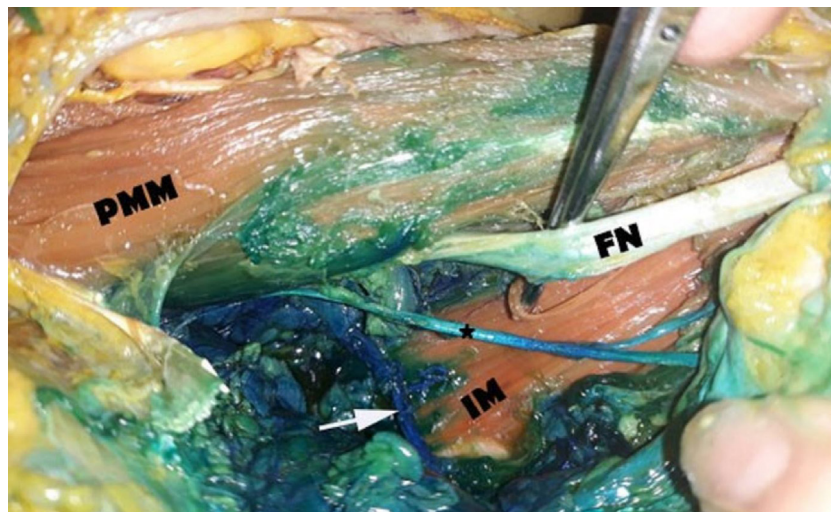


Figure 1 Distribution of the methylene blue in supine QLB. PMM, Major Psoas Muscle; FN, Femoral Nerve; IM, Iliac Muscle. White Arrow, Ilioinguinal Nerve; *, Lateral Femoral Cutaneous Nerve.