

CASE REPORTS

Near ideal anesthetic technique for tracheal stenting in central airway obstruction with dexmedetomidine-ketamine infusion: a case report



Sakshi Thakore ^{a,*}, Nishkarsh Gupta^a, Karan Madan^b, Sushma Bhatnagar^a

^a Department of onco-Anesthesiology, DRBRAIRCH, AIIMS, New Delhi

^b Department of Pulmonary and critical care medicine, AIIMS, New Delhi

Received 17 January 2020; accepted 19 March 2021

Available online 22 April 2021

KEYWORDS

Ketamine;
Dexmedetomidine;
Central airway
obstruction;
Rigid bronchoscopy;
Case report

Abstract Central airway obstruction presents as an emergency with dyspnea and stridor. Anesthetic management of rigid bronchoscopy-guided tracheal stenting is highly stimulating procedure requiring general anesthesia. But it may lead to life threatening airway obstruction and cardiovascular collapse after induction. Total intravenous anesthesia based on propofol-remifentanyl is an optimal anesthetic technique, but remifentanyl is not available in many countries. Although dexmedetomidine-ketamine has been used for procedural sedation, its use for rigid bronchoscopy in the setting of central airway obstruction has not been described in literature. We describe near ideal anesthetic technique for management of central airway obstruction using dexmedetomidine-ketamine combination.

© 2021 Sociedade Brasileira de Anestesiologia. Published by Elsevier Editora Ltda. This is an open access article under the CC BY-NC-ND license (<http://creativecommons.org/licenses/by-nc-nd/4.0/>).

Introduction

Anesthetic management of Rigid Bronchoscopy (RB) guided tracheal stenting in patients with Central Airway Obstruction (CAO) poses unique challenges because the patient

present as an emergency with high grade dyspnea and stridor with impaired oxygenation which provides us minimal time for optimization. It is a highly stimulating procedure and requires General Anesthesia (GA). But it may lead to life-threatening airway obstruction and cardiovascular collapse after induction of anesthesia. Total Intravenous Anesthesia (TIVA) based on propofol and remifentanyl combination (intermittent boluses or continuous infusion)^{1–3} is an optimal anesthetic technique but remifentanyl is not available in many countries like ours. Remifentanyl and propofol both cause hypotension and bradycardia and the effect

* Corresponding author.

E-mails: drsakshiarora88@gmail.com

(S. Thakore), drnishkarsh@rediffmail.com

(N. Gupta), sushmabhatnagar1@gmail.com (S. Bhatnagar).

<https://doi.org/10.1016/j.bjane.2021.03.019>

© 2021 Sociedade Brasileira de Anestesiologia. Published by Elsevier Editora Ltda. This is an open access article under the CC BY-NC-ND license (<http://creativecommons.org/licenses/by-nc-nd/4.0/>).

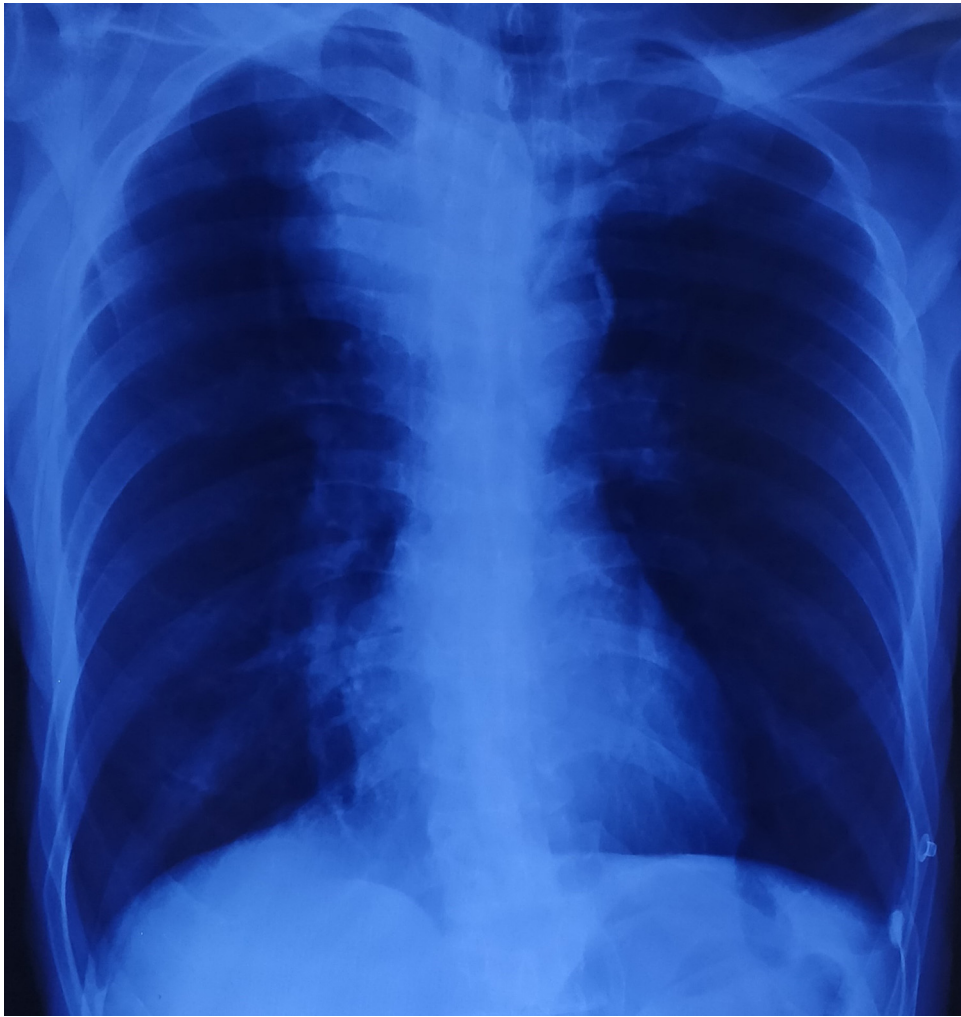


Figure 1

of their combination on hemodynamics can be synergistic. Ketamine, on the other hand, increases blood pressure and heart rate and is a good bronchodilator and analgesic but causes delirium, hallucinations, and increased salivation. Dexmedetomidine (DXM) reduces the side effects of ketamine and their combination provides hemodynamic stability. There are a few reports on the use of ketamine and DXM combination for procedural sedation.⁴ DXM-ketamine infusion has not been reported to be utilized for GA in the setting of rigid bronchoscopy. We describe the use of combination of DXM-ketamine infusions for RB guided tracheal stenting in a patient with CAO.

Case report

A 55-year-old American Society of Anesthesiologists (ASA) physical status II patient weighing 56 kg presented to the emergency with cough, breathlessness (modified medical research council Grade 3)^{5,6} and stridor. He was in respiratory distress with tachypnea (respiratory rate 22/minute) and usage of accessory muscles for respiration. On auscultation, patient had decreased air entry with bilateral inspiratory crackles with expiratory wheeze and audi-

ble stridor. Hemodynamic parameters were stable except tachycardia (pulse rate 120/min). Arterial Blood Gas (ABG) exhibited pH 7.31, PaO₂ 63 mmHg, PaCO₂ 58 mmHg, and oxygen saturation (SpO₂) 89% on room air. Chest X-ray revealed mediastinal mass with tracheal compression and homogenous opacity in right middle lobe (Fig. 1). Computed Tomography (CT) scan demonstrated a large conglomerated lymph nodal mass in right paratracheal location (7 × 5 cm) infiltrating into tracheal lumen with significant narrowing of tracheal lumen with minimum diameter 3.5 mm (Grade 3 tracheal stenosis)⁷ (Fig. 2). He was posted for RB-guided tracheal stenting under GA.

After confirming fasting status (6 hours) and obtaining written informed consent, the patient was taken to operation theatre. Preoperative counselling was done, and anesthesia risks related to loss of airway control, need of intubation and mechanical ventilation, need of intensive care unit, and perioperative pulmonary complications were explained to relatives. He was started on nebulization with salbutamol (2 mL, 2.5 mg) and budesonide (2 mL, 0.5 mg), and standard ASA monitors including Bispectral Index (BIS) monitor were attached. Preoxygenation was done with 10 L of 100% oxygen for 5 minutes in head-up position.

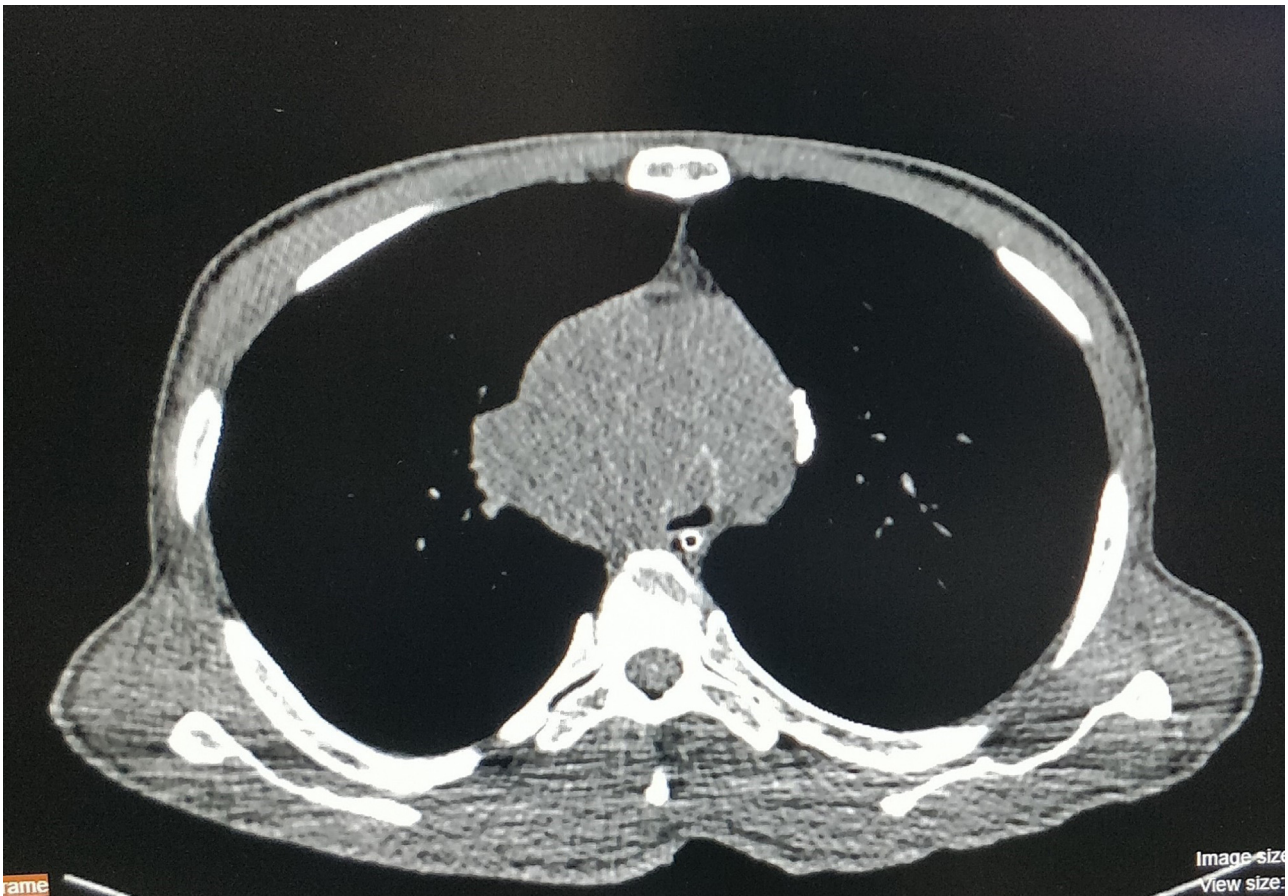


Figure 2

He received 0.2 mg glycopyrrolate, 8 mg dexamethasone and 75 μg fentanyl Intravenously (IV). Thereafter, 0.5 $\mu\text{g}\cdot\text{kg}^{-1}$ DXM was given over 10 minutes, and anesthesia was induced with 75 mg IV ketamine. Subsequently, 1 $\text{mg}\cdot\text{kg}^{-1}$ intravenous (IV) succinylcholine was given and RB (Karl storz, size 11) was introduced in the trachea 60 seconds later. During maintenance phase, DXM (0.2–0.5 $\text{mcg}\cdot\text{kg}^{-1}\cdot\text{h}^{-1}$) and ketamine (0.5–1 $\text{mg}\cdot\text{kg}^{-1}\cdot\text{h}^{-1}$) infusions were titrated to achieve a BIS between 40–60. The patient was ventilated intermittently through anesthesia circuit attached to the ventilating port of the RB. Intraoperative ABG revealed improvement in oxygenation (PaO_2 75 mm) with slight increase in PaCO_2 (63 mm). The procedure lasted for 30 minutes and the patient was hemodynamically stable throughout the procedure. After the stent was placed, bronchoscope was removed, and I-gel size 4 was inserted. The infusion of DXM and ketamine was stopped, and the patient was extubated after ensuring good respiratory efforts with BIS of 80 after about 6 minutes of stopping the infusions. Postoperative ABG revealed Ph 7.37, PaO_2 80 mm, PaCO_2 52 mm, and SpO_2 95%. He was conscious, oriented, pain free and was following commands. He was shifted to post anesthesia care unit for one day. Patient remained stable while maintaining SpO_2 95–96% on room air with normal neurocognition in the postoperative period. He was discharged the next day. His immediate postoperative period and follow up at one week was uneventful.

Discussion

Tracheal stenting in CAO is an emergency procedure and may not give enough time for preoperative optimization. It can lead to life threatening respiratory complications due to nature of disease, decreased oxygen reserve, or sudden airway collapse after anesthesia induction.

Propofol and remifentanyl based TIVA is preferred technique over inhalational anesthesia.^{2,8} Propofol is an IV hypnotic agent with short context sensitive half-life but it is painful on injection and does not provide analgesia. It may also cause suppression of airway reflexes, apnea, and hemodynamic instability due to vasodilatation and negative inotropy. Ketamine is an IV anesthetic agent with N-Methyl-D-Aspartate (NMDA) receptor blockade as the primary mechanism of action. Ketamine is a good analgesic with rapid onset of action (30s) and causes bronchodilatation. But its usefulness is limited as it may cause delirium, hallucinations, emergence reactions, increased salivary secretions and hemodynamic instability (tachycardia and hypertension) due to sympathetic stimulation.⁸

DXM is a centrally acting alpha-2 adrenergic receptor agonist and produces sedation, anxiolysis and analgesia without respiratory depression. It enhances anesthesia produced by other anesthetic drugs, preserves airway reflexes and reduces delirium.^{9–11} However, it may cause bradycardia and hypotension and has slow onset of action when used

as sole agent. A combination of DXM and ketamine may provide ideal anesthetic conditions like rapid onset, sedation, analgesia, amnesia, bronchodilation, hemodynamic stability, and maintenance of spontaneous respiration with minimal side effects. It may be an alternative to propofol and remifentanyl in countries where remifentanyl is not available. Moreover, it obviates the need of additional opioids and opioid related side effects.

DXM-ketamine combination has been used for procedural sedation with minimal cardiorespiratory adverse effects in patients undergoing esophago-gastro-duodenoscopy, in children undergoing minor cardiac procedures, and in pediatric dentistry.^{11–13} Tobias has demonstrated descriptive accounts of reports from literature regarding the use of this combination for procedural sedation.⁴ Apart from sedation, the effective and safe use of this combination has also been described for anesthesia in patients with uncorrected congenital cyanotic heart disease presenting for non-cardiac surgery.¹⁴

DXM-ketamine combination provided adequate sedation and comfort¹⁵ with better hemodynamic stability than DXM alone¹⁶ for awake fiberoptic intubation. RB procedure is associated with greater hemodynamic response for a longer time and optimum depth of anesthesia should be maintained throughout the procedure. Our patient presented in CAO with severe dyspnea and had low oxygen saturation that did not improve with any bronchodilators or steroids. As insertion of RB is highly stimulating, therefore depolarizing muscle relaxant was used for providing relaxation¹⁷ due to its rapid onset, short duration, low cost, and better intubating conditions. So, emergency tracheal stenting was planned under general anesthesia with short acting neuromuscular block for induction followed by continuous infusion of DXM-ketamine combination that provided good anesthetic depth (objectively measured by BIS values) and hemodynamic stability without the need of additional doses of muscle relaxants. Further randomized studies are required to validate these findings in such category of patients.

Conclusion

DXM-ketamine based total intravenous anesthesia provides good analgesia, anesthesia, and hemodynamic stability with rapid, smooth induction, and emergence with minimal side effects. Hence it can be an ideal anesthetic technique for rigid bronchoscopic guided tracheal stenting.

Conflicts of interest

The authors declare no conflicts of interest.

References

1. Bakan M, Topuz U, Umutoglu T, et al. Remifentanyl-based total intravenous anesthesia for pediatric rigid bronchoscopy: comparison of adjuvant propofol and ketamine. *Clinics*. 2014;69(6):372–7.
2. Morita S, Akasaka N, Sakamoto M, Tateda T. Anesthetic management with remifentanyl for tracheobronchial stent insertion. *Masui*. 2010;59:183–7.
3. Prakash N, McLeod T, Gao Smith F. The effects of remifentanyl on haemodynamic stability during rigid bronchoscopy. *Anaesthesia*. 2001;56(June (6)):576–80.
4. Tobias JD. Dexmedetomidine and ketamine: an effective alternative for procedural sedation? *Pediatr Crit Care Med*. 2012;13:423.
5. Ban WH, Lee JM, Ha JH, et al. Dyspnea as a prognostic factor in patients with non-small cell lung cancer. *Yonsei Med J*. 2016;57:1063–9.
6. Munari AB, Gulart AA, dos Santos K, Venâncio RS, Karloh M, Mayer AF. Modified medical research council dyspnea scale in gold classification better reflects physical activities of daily living. *Respiratory Care*. 2018;63:77–85.
7. Freitag L, Ernst A, Unger M, Kovitz K, Marquette CH. A proposed classification system of central airway stenosis. *Eur Respir J*. 2007;30:7–12.
8. Conacher ID. Anaesthesia and tracheobronchial stenting for central airway obstruction in adults. *BJA Br J Anaesth*. 2003;90:367–74.
9. Naaz S, Ozair E. Dexmedetomidine in current anaesthesia practice—a review. *J Clin Diagn Res JCDR*. 2014;8. GE01–4.
10. Kaur M, Singh PM. Current role of dexmedetomidine in clinical anesthesia and intensive care. *Anesth Essays Res*. 2011;5:128–33.
11. Seybold JL, Ramamurthi RJ, Hammer GB. The use of dexmedetomidine during laryngoscopy, bronchoscopy, and tracheal extubation following tracheal reconstruction. *Pediatr Anesth*. 2007;17:1212–4.
12. Joshi VS, Kollu SS, Sharma RM. Comparison of dexmedetomidine and ketamine versus propofol and ketamine for procedural sedation in children undergoing minor cardiac procedures in cardiac catheterization laboratory. *Ann Card Anaesth*. 2017;20:422–6.
13. Jaikaria A, Thakur S, Singhal P, Chauhan D, Jayam C, Syal K. A comparison of oral midazolam-ketamine, dexmedetomidine-fentanyl, and dexmedetomidine-ketamine combinations as sedative agents in pediatric dentistry: a triple-blinded randomized-controlled trial. *Contemp Clin Dent*. 2018;9:5197–203.
14. Goyal R, Singh S, Bangi A, Singh SK. Case series: dexmedetomidine and ketamine for anesthesia in patients with uncorrected congenital cyanotic heart disease presenting for non-cardiac surgery. *J Anaesthesiol Clin Pharmacol*. 2013;29:543–6.
15. Scher CS, Gitlin MC. Dexmedetomidine and low-dose ketamine provide adequate sedation for awake fiberoptic intubation. *Can J Anaesth*. 2003;50:607–10.
16. Sinha SK, Joshiraj B, Chaudhary L, Hayaran N, Kaur M, Jain A. A comparison of dexmedetomidine plus ketamine combination with dexmedetomidine alone for awake fiberoptic nasotracheal intubation: a randomized controlled study. *J Anaesthesiol Clin Pharmacol*. 2014;30:514.
17. Hung O, McKeen D, Huitink J. Our love-hate relationship with succinylcholine: is sugammadex any better? Succinylcholine, nous t'aimons, nous te haïssons: et toi, sugammadex, es-tu mieux loti? *Can J Anaesth*. 2016;63:905–10.