

## CLINICAL RESEARCH

### Comparison of low dose intravenous fentanyl and morphine infusion for postoperative analgesia in spine fusion surgeries – a randomized control trial



Rajagopalan Venkatraman , Anand Pushparani \*, Ramamurthy Balaji , Prabhuvél Nandhini 

SRM Medical College Hospital and Research Centre, Department of Anaesthesia, Tamilnadu, India

Received 12 December 2019; accepted 14 July 2020  
Available online 28 December 2020

#### KEYWORDS

Fentanyl;  
Morphine;  
Spine surgery;  
Postoperative pain

#### Abstract

**Background and aims:** Post-operative analgesia for Spine surgeries is difficult without patient control analgesia (PCA) and inadequate monitoring facilities. The objective was to study the effectiveness of analgesia of intravenous administration of low dose fentanyl and morphine for postoperative analgesia following spine fusion surgeries.

**Methods:** One hundred adult patients undergoing spine instrumentation surgeries were randomly allotted into two groups: Group M (morphine) or Group F (fentanyl). The patients received either 0.02 mg.kg<sup>-1</sup>.h<sup>-1</sup> of morphine or 0.3 mcg.kg<sup>-1</sup>.h<sup>-1</sup> of fentanyl infusion postoperatively. If the patient had pain, additional bolus dose of 0.04 mg.kg<sup>-1</sup> and 0.6 mcg.kg<sup>-1</sup> bolus for morphine and fentanyl respectively were given and noted. The additional analgesic consumption was recorded. The Ramsay sedation score (RSS), visual analogue score (VAS), vital parameters and complications were observed.

**Results:** The demographic characteristics did not reveal significant difference among the two groups. In morphine group, 32 patients did not require any additional bolus dose, 15 patients needed one bolus dose and one patient each required two and three boluses. In fentanyl group, two, 24, 20 and four patients required 0, 1, 2 and 3 bolus doses respectively. There were no statistically significant variations in hemodynamic features like heart rate, blood pressure and oxygen saturation, RSS and VAS. The complication rate was not significant among the groups.

**Conclusion:** Low dose continuous infusion of morphine is more effective than fentanyl with fewer requirements of rescue analgesics for postoperative analgesia. Both drugs are safe without any serious complications.

© 2020 Sociedade Brasileira de Anestesiologia. Published by Elsevier Editora Ltda. This is an open access article under the CC BY-NC-ND license (<http://creativecommons.org/licenses/by-nc-nd/4.0/>).

\* Corresponding author.

E-mail: [drvenkat94@gmail.com](mailto:drvenkat94@gmail.com) (A. Pushparani).

## Introduction

Spine fusion surgeries are major surgeries resulting in varying pain intensity after surgery.<sup>1</sup> The inadequate treatment of pain after surgery can lead to severe emotional disturbance along with autonomic hyperactivity and reduced mobility.<sup>2</sup> An inefficiently managed pain can result in sensitization of central and peripheral nervous system.<sup>3</sup> The pain severity following spine surgery is directly proportional to the invasiveness of the procedure and the number of vertebrae operated.<sup>4</sup> The severity of pain is not different among different levels and remains the same from cervical to lumbar spine surgeries.<sup>5</sup>

The pain following spine instrumentation is usually managed with patient control analgesia (PCA).<sup>6</sup> Morphine remains the gold standard drug of choice to be used in PCA. However, several other agents like fentanyl, tramadol have also been used in PCA.<sup>7</sup> But in developing countries, the PCA pump may not be available in all the hospitals. The continuous opioid infusions are rarely being used in these hospitals because of inadequate monitoring facilities and fear of complications like respiratory depression, nausea, vomiting, and pruritus. The patients are inadequately treated for pain postoperatively which can lead to severe emotional disturbances. Hence, we decided to perform this study to analyze the efficacy and safety of continuous morphine or fentanyl infusion for postoperative analgesia following spine instrumentation surgeries.

The primary objective of our study was to study the efficacy of morphine and fentanyl administration for postoperative analgesia following spine fusion surgeries. The secondary objectives were to assess visual analog scale (VAS), sedation score and complications.

## Patients and methods

We registered our study in the Clinical Trial Registry India (CTRI/2017/11/010629). (The study can be accessed in the following link in the study registry: <http://ctri.nic.in/Clinicaltrials/showallp.php?mid1=21232&EncHid=&userName=2017/11/010629>). The first patient was enrolled on December 1<sup>st</sup>, 2017 and the study was completed on May 31, 2019. After obtaining approval from the institutional ethical committee, this randomized, prospective, double-blinded study was done on 100 patients who underwent lumbar spine fusion surgeries in a tertiary care hospital linked to medical college. Patients of the American Society of Anesthesiologists (ASA) I, II or III posted for lumbar spine instrumentation surgeries for spondylolisthesis were recruited in the study. The patients between 18–60 years and weighing from 50 to 100 kg were included. Patients with cardiac, renal or hepatic disease, allergic to opioids, pregnant patients and with history of obstructive sleep apnea were excluded from the study. The participants were informed about the study and consent was obtained from all patients. They were randomly divided into two groups: Group M (morphine) or Group F (fentanyl) infusion by computer-generated random numbers method. The printout was taken and kept in a sealed envelope.<sup>9</sup> The general anesthesia was standardized in both the groups with propofol as an induction agent, vecuronium as a

muscle relaxant and maintained with nitrous oxide, oxygen, and sevoflurane. Fentanyl 2 mcg.kg<sup>-1</sup> was used as the intraoperative analgesic with further bolus 0.5 mcg.kg<sup>-1</sup> given hourly. The patient was shifted to the post anesthetic care unit after recovery. The number of spinal segments involved in fusion surgeries and the duration of surgery was noted.

The envelope was opened at this stage and the first anesthesiologist prepared the solution according to the group involved. Morphine was prepared as 1 mg.ml<sup>-1</sup> and fentanyl as 15 mcg.ml<sup>-1</sup> solution in an identical looking 50 mL syringes.

The amount of infusion and bolus dose for breakthrough pain was decided by the first anesthesiologist based on body weight in mL.h<sup>-1</sup> to be infused in a syringe pump. He documented it and handed it to the second anesthesiologist. The first anesthesiologist took no further part in the study. The second anesthesiologist administered the solution as per the dose suggested by the first anesthesiologist. He was not aware of the group involved and did the monitoring and further management of the patient. Group M patients received morphine 0.02 mg.kg<sup>-1</sup>.h<sup>-1</sup> continuous infusion with 0.04 mg.kg<sup>-1</sup> as bolus for breakthrough pain. Group F patients received fentanyl in a dose of 0.3 mcg.kg<sup>-1</sup>.h<sup>-1</sup> continuous infusion with a bolus of 0.6 mcg.kg<sup>-1</sup> bolus for breakthrough pain. If the patient had pain after 15 minutes, the bolus dose was repeated. The total number of additional bolus doses utilized were noted. If the pain was persistent for more than 30 minutes, then the study was stopped, and the pain was treated with morphine in titrated doses. Both groups received infusion for the first 24 hours postoperatively. The patients were followed up for a further 24 hours to observe for complications.

VAS was explained to the patient and was used to assess the pain.<sup>8</sup> The patients were given an additional bolus dose when VAS > 3. The sedation was assessed using the Ramsay sedation scale (RSS) and was given as follows: 1 – patient is agitated, and anxious or restless, or both, 2 – patient is oriented, cooperative, and tranquil, 3 – patient responding to command only, 4 – a brisk response to a light glabellar tap or a loud auditory stimulus, 5 – a sluggish response to a light glabellar tap or a loud auditory stimulus, 6 – no response to a light glabellar tap or a loud auditory stimulus.<sup>10</sup> The patients were monitored continuously for vital parameters like heart rate, oxygen saturation (SPO<sub>2</sub>) and non-invasive blood pressure and values were recorded fourth hourly for 24 hours. The patients were observed for adverse events like pruritus, nausea, bradypnea, vomiting, and respiratory depression characterized by a fall in SPO<sub>2</sub>. The total consumption of bolus doses, VAS, RSS, oxygen supplementation and any adverse effects were recorded.

To find out at least 20% difference in additional bolus opioid requirement with the power of 80% and an alpha error of 0.05 a minimum of 44 patients will be required in each group. We included 50 patients in each group to compensate for the possible dropout. Chi-square test and Fischer Exact Test were used for non-parametric data and student t-test was used to analyze parametric data. Statistical significance was considered if *p*-value is < 0.05 and < 0.001 as highly significant. Statistical Package for Social Science (SPSS) 20.0 was used to perform statistical analysis.

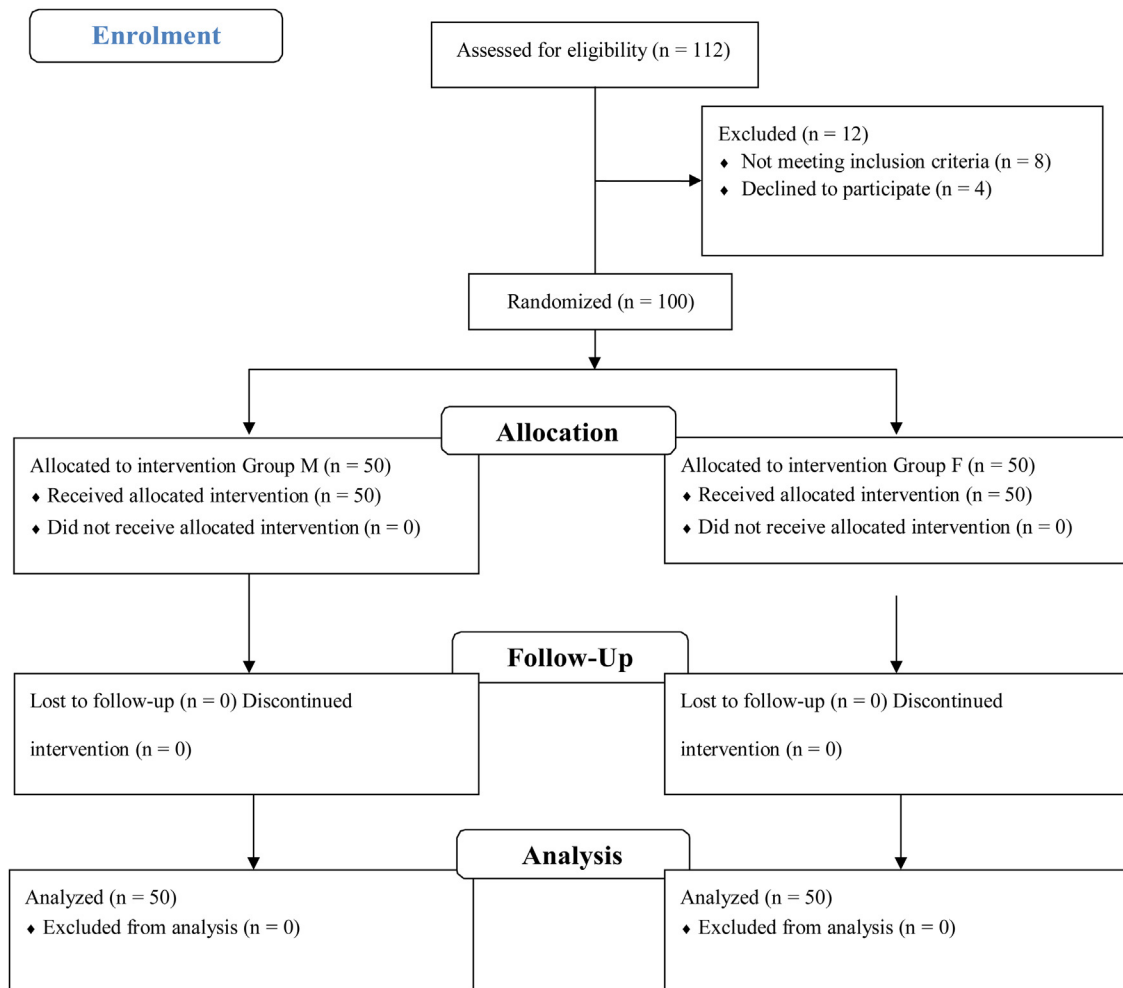


Figure 1 CONSORT Flow chart.

## Results

The data analysis was published in online repository Mendeley with the following link Rani, Pushpa (2020), "Comparison of Low Dose Intravenous Fentanyl and Morphine Infusion for Postoperative Analgesia in Spine Fusion Surgeries – A Randomised Control Trial", Mendeley Data, v1 <http://dx.doi.org/10.17632/msw2rg4xgb.1>. Of the 112 patients enrolled for the study, 12 were excluded before randomization due to not meeting inclusion criteria (n=8) and four patients declined to participate. One hundred participants were randomly divided into two groups of 50 each and no patient was lost to follow-up. The Consolidated Standards of Reporting Trials (CONSORT) flow chart was shown in Fig. 1.

The patients who underwent lumbar spine instrumentation surgeries for spondylolisthesis were included in the study. Both the groups were similar in terms of demographic profile, smoking history, duration of surgery and number of spinal segments involved in fusion with no statistical significance. (Table 1) Thirty-three patients in morphine (Group M) did not require any additional bolus dose for postoperative analgesia and VAS was maintained at < 4 throughout the first 24 hours of the postoperative period. Only two patients

in the fentanyl group were having VAS < 4 and others required additional bolus doses for adequate pain relief. In the morphine group, 15 patients required one bolus; one patient had two boluses and one patient needed three additional bolus doses. In the fentanyl group, 24 patients required one additional bolus dose; 20 patients needed two doses and four patients had three additional doses to achieve VAS < 4. There was no loss to follow-up as no patient had persistent pain beyond thirty minutes. The results were summarized in Fig. 2. The RSS was similar between the two groups (Table 2). There was no difference in VAS between the two groups and was maintained at less than 4 until 12 hours. After 12 hours, it was significant (Table 3).

There was no significant difference in heart rate, mean arterial pressure and saturation among the two groups (Fig. 3). However, one patient in the morphine group experienced a fall in saturation and required oxygen supplementation through a nasal cannula. Eleven patients in Group M had nausea while three patients in Group F had nausea and it was statistically significant ( $p=0.04$ ). The vomiting was observed in five patients in morphine and one in fentanyl group and it was statistically not significant ( $p=0.206$ ). The pruritus was observed in six patients in Group M and one in the Group F ( $p=0.104$ ). But there was no statistical signif-

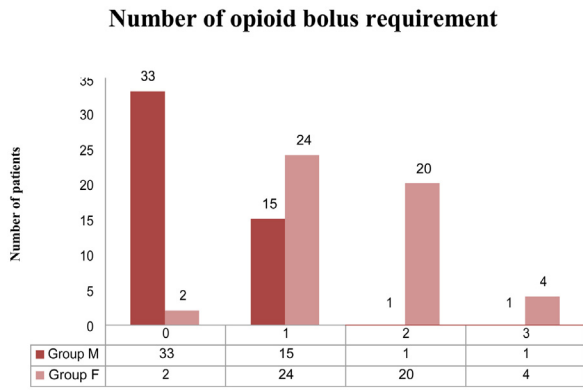


Figure 2 Number of additional bolus doses required.

incance. The reduction in respiratory rate to less than eight and apnea was not reported in any of the patients.

### Discussion

The spine fusion surgeries are major surgeries resulting in severe postoperative pain. This pain is often inadequately treated in hospitals where the PCA pump is not available. The patients are frequently managed with paracetamol and non-steroidal anti-inflammatory agents which are not adequate in most of these patients. The opioid-like morphine and fentanyl are hardly used because of inadequate monitoring facilities and the fear of respiratory depression. Hence, we designed this study to test the effectiveness and safety of low dose morphine and fentanyl infusion for postoperative analgesia following lumbar spine fusion surgeries.

Multimodal pain management strategies have been demonstrated to be the most effective treatment modality for spinal fusion surgeries. Several agents like dextromethor-

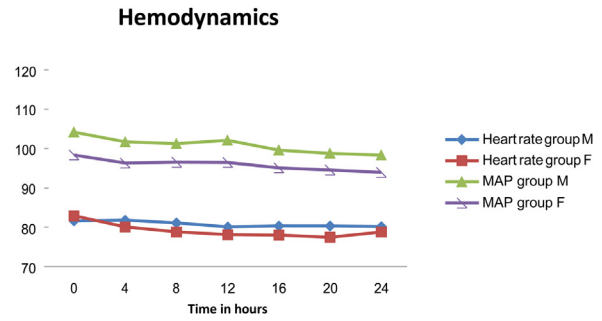


Figure 3 Variations in heart rate (beats/min) and mean arterial pressure (mm Hg).

phan, ketorolac, or gabapentin have all been tried to reduce pain after surgery and opioid use, with varying results.<sup>11-13</sup> PCA forms the cornerstone for treatment either alone or as part of multimodal treatment. Morphine is usually used in PCA with a bolus dose of 1 mg and a lockout interval of 5-10 minutes. Hence patients may use up to 12 mg in one hour. There is a potential to cause respiratory depression in these doses, hence monitoring by trained staff with a multiparameter monitor including pulse oximeter is mandatory when using a PCA pump. PCA pump and adequate monitoring may not be available in all the hospitals in developing countries.

The narcotics morphine and fentanyl can be used in various routes like intravenously, intramuscular, epidurally, intrathecally, orally (morphine) and transdermally (fentanyl).<sup>14</sup> Guinard et al.<sup>15</sup> studied three different doses of analgesics with fentanyl and demonstrated both intravenous (IV) as well as epidural fentanyl had the same efficacy in pain relief after thoracotomy. Loper et al.<sup>16</sup> proved that epidural infusion continuously was not able to provide any significant clinical advantage over continuous IV infusion of fentanyl.

Table 1 Demography.

	Group M	Group F	p-value
Age	47.62 ± 9.477	46 ± 10.6	0.379
Sex (Male/Female)	39/11	37/13	0.64
ASA (I/II/III)	26/22/2	25/21/4	0.701
Duration of surgery (minutes)	128.63 ± 18.92	122.73 ± 16.27	0.097
Number of spinal segments involved (1/2/3)	12/35/3	9/37/4	0.731
Smoking (Yes/No)	28/22	25/25	0.548

Values are in Mean ± Standard deviation (SD) or number of patients.

Table 2 Ramsay sedation score.

Time in hours	Group M	Group F	U value	Z Score	p-value
0	1 (2-1)	2 (2-1)	1103.5	0.84682	0.395
4	2 (2-2)	2 (2-2)	1110.5	0.79783	0.423
8	2 (2-2)	2 (2-2)	1203.5	-0.31373	0.756
12	2 (2-2)	2 (2-2)	1200.5	-0.16797	0.865
16	2 (2-2)	2 (2-2)	1200.5	0.3378	0.727
20	2 (2-2)	2 (2-2)	1173	-0.36042	0.718
24	2 (2-2)	2 (2-2)	1200.5	-0.16797	0.865

Values are in median (Inter Quartile Range).

**Table 3** Visual analog score.

Time in hours	Group M	Group F	U value	Z Score	p-value
0	2 (3-2)	2 (5-1)	1137	-0.61237	0.541
4	2 (3-2)	2 (5-1)	1133	-0.64037	0.522
8	2 (2-2)	2 (5-1)	1046	-1.24924	0.211
12	2 (2.5-2)	2 (5-1)	1105.5	-0.83283	0.406
16	2 (2-2)	1.5 (2-1)	809	-2.90789	0.003 <sup>a</sup>
20	2 (2-2)	2 (2-1)	743.5	-3.3663	< 0.001 <sup>a</sup>
24	2 (2-2)	2 (2-1)	644	-4.06265	< 0.001 <sup>a</sup>

Values are in median (Inter Quartile Range).

<sup>a</sup> p-value statistically significant.

Fentanyl is a short-acting opioid that is used for both intraoperative and postoperative analgesia. Fentanyl has a quick onset with the duration of action less than morphine. The number of patients requiring additional rescue bolus dose was more in Group F than the Group M. Russo et al retrospectively compared analgesia after gynecological surgeries with intravenous infusion of morphine with fentanyl continuously. They compared 0.3 mcg.kg<sup>-1</sup>.h<sup>-1</sup> fentanyl with 0.02 mg.kg<sup>-1</sup>.h<sup>-1</sup> morphine for total intravenous analgesia for gynecologic surgeries. The dosage used is similar to the dose used in our study. The primary endpoint of that study was taken as a requirement for rescue analgesia postoperatively and the time to gastrointestinal bowel recovery was also measured. They found that both fentanyl and morphine infusion was effective in providing adequate pain relief and fentanyl was more effective than morphine in the requirement of rescue analgesic therapy, faster bowel recovery time and shorter hospital stay.<sup>17</sup> But the inference of our study was in contrast to this study and we found that morphine was associated with a lower requirement of rescue analgesia.

RSS remained same between the two groups with no difference statistically. Pain scores as assessed by VAS were also not different between fentanyl and morphine. VAS was kept under four in both the groups and rescue analgesics were used when it was exceeded. Russo et al demonstrated that the fentanyl group achieved significant sedation at first postoperative hour than morphine with no statistically significant variations after one hour between the two groups. The RSS in the fentanyl group gradually decreased over 12 hours and remained stable after that period. However, in the morphine group, it gradually increased from first to the sixth hour and remained relatively stable after six hours. In our study, the maximum sedation score was achieved at four hours for the fentanyl group and at eight hours for the morphine group.

There were no significant variations in heart rate, blood pressure and saturation between groups statistically. Heart rate was lower and mean arterial pressure was higher in the fentanyl (F) group than in Group M, with no statistical significance. The complications like nausea, vomiting, and pruritus were reported more frequently with morphine than the fentanyl group. One patient in the morphine group had a fall in saturation to 88% and required oxygen by nasal cannula. None of the patients developed apnea or required assisted ventilation showing the safety of both fentanyl and morphine when used in low dose continuous intravenous infusion.

The present study has few limitations: first, we were able to demonstrate the requirement of rescue analgesics was less in morphine than the fentanyl group; we did not encounter any serious complications like respiratory depression with this sample size. The sample sizes needed to be larger to confirm the safety profile. Secondly, we did not study urinary retention as all the patients were catheterized. Bowel disturbance was also not studied. There was not much literature evidence available regarding the comparison of intravenous infusion of opioids. Finally, we did not study the risk factors for postoperative nausea and vomiting. Hence, we cannot comment with certainty about the significance of increased incidence of nausea and vomiting in the morphine group.

To conclude, continuous low dose infusion of morphine is more effective than fentanyl with fewer requirements of rescue analgesics for postoperative analgesia following spine fusion surgeries. Both drugs are safe and are devoid of any serious complications.

## Conflict of interest

The authors declare no conflict of interest

## References

- Rudra A, Chatterjee S, Ray S, Ghosh S. Pain Management after Spinal Surgery. *Indian Journal of Pain*. 2015;29:14.
- Sinatra R. Cause and consequences of inadequate management of acute pain. *Pain Med*. 2010;11:1859–71.
- Coley KC, Williams BA, DaPos SV, et al. Retrospective evaluation of unanticipated admissions and readmissions after surgery and associated costs. *J Clin Anesth*. 2002;14:349–53.
- Ortiz-Cardona J, Bendo AA. Perioperative pain management in the neurosurgical patient. *Anesthesiol Clin*. 2007;25:655–74.
- Bernard JM, Surbled M, Lagarde D, et al. Analgesia after surgery of the spine in adults and adolescents. *Can Anesthesiol*. 1995;43:557–64.
- Reynolds RA, Legakis JE, Tweedie J, et al. Postoperative pain management after spinal fusion surgery: An analysis of the efficacy of continuous infusion of local anesthetics. *Global Spine J*. 2013;3:7–14.
- Javed T, Ahad B, Singh P, et al. A prospective randomized study to compare tramadol and morphine for postoperative analgesia in spine surgeries using intravenous patient controlled analgesia. *Int J Res Med Sci*. 2017;5:3350–4.
- Venkatraman R, Abhinaya RJ, Sakthivel A, et al. Efficacy of ultrasound-guided transversus abdominis plane block for post-



- operative analgesia in patients undergoing inguinal hernia repair. *Local Reg Anesth.* 2016;9:7–12.
9. Kim J, Shin W. How to do random allocation (randomization). *Clin Orthop Surg.* 2014;6:103–9.
  10. Ramsay MA, Savege TM, Simpson BR, et al. Controlled sedation with alphaxalone-alphadolone. *Br Med J.* 1974;2:656–9.
  11. Horn PL, Wrona S, Beebe AC, et al. A retrospective quality improvement study of ketorolac use following spinal fusion in pediatric patients. *Orthop Nurs.* 2010;29:342–3.
  12. Suski M, Bujak-Gizycka B, Madej J, et al. Co-administration of dextromethorphan and morphine: reduction of post-operative pain and lack of influence on morphine metabolism. *Basic Clin Pharmacol Toxicol.* 2010;107:680–4.
  13. Rusy LM, Hainsworth KR, Nelson TJ, et al. Gabapentin use in pediatric spinal fusion patients: a randomized, double-blind, controlled trial. *Anesth Analg.* 2010;110:1393–8.
  14. Poe-Kochert C, Tripi PA, Potzman J, Son-Hing JP, et al. Continuous intravenous morphine infusion for postoperative analgesia following posterior spinal fusion for idiopathic scoliosis. *Spine.* 2010;35:754–7.
  15. Guinard JP, Mavrocordatos P, Chiolero R, et al. A randomized comparison of intravenous versus lumbar and thoracic epidural fentanyl for analgesia after thoracotomy. *Anesthesiology.* 1992;77:1108–15.
  16. Loper KA, Ready LB, Downey M, et al. Epidural and intravenous fentanyl infusion are clinically equivalent after knee surgery. *Anesth Analg.* 1990;70:72–5.
  17. Russo A, Grieco DL, Bevilacqua F, et al. Continuous intravenous analgesia with fentanyl or morphine after gynecological surgery: a cohort study. *J Anesth.* 2017;31:51–7.