

CLINICAL RESEARCH

Perineural dexamethasone in ultrasound-guided interscalene brachial plexus block with levobupivacaine for shoulder arthroscopic surgery in the outpatient setting: randomized controlled trial*



Mateus Meira Vasconcelos^a, João Paulo Jordão Pontes^{a,b,c,*}, Alexandre de Menezes Rodrigues^a, Demócrito Ribeiro de Brito Neto^{a,b}, Rodrigo Rodrigues Alves^{a,b}, Fernando Cássio do Prado Silva^{a,b,d}, Denis Fabiano de Souza^{e,f}

^a Hospital Santa Genoveva, Uberlândia, MG, Brazil

^b Sociedade Brasileira de Anestesiologia (TSA – SBA), Rio de Janeiro, RJ, Brazil

^c European Diploma in Anaesthesiology and Intensive Care (EDAIC), European Society of Anaesthesiology, Brussels, Belgium

^d Hospital Santa Genoveva, CET, Uberlândia, MG, Brazil

^e Instituto do Coração do Triângulo (ICT), Uberlândia, MG, Brazil

^f Universidade Federal de Uberlândia (UFU), Ciências da Saúde, MG, Brazil

Received 3 December 2018; accepted 11 July 2020

Available online 10 October 2020

KEYWORDS

Dexamethasone;
Brachial plexus block;
Ultrasonography;
Anesthesia,
conduction;
Arthroscopy

Abstract

Background and objectives: In shoulder arthroscopy, on an outpatient basis, the patient needs a good control of the postoperative pain that can be achieved through regional blocks. Perineural dexamethasone may prolong the effect of these blocks. The aim of this study was to evaluate the effect of perineural dexamethasone on the prolongation of the sensory block in the postoperative period for arthroscopic shoulder surgery in outpatient setting.

Methods: After approval by the Research Ethics Committee and informed consent, patients undergoing arthroscopic shoulder surgery under general anesthesia and ultrasound-guided interscalene brachial plexus block were randomized into Group D – blockade performed with 30 mL of 0.5% levobupivacaine with vasoconstrictor and 6 mg (1.5 mL) of dexamethasone and Group C – 30 mL of 0.5% levobupivacaine with vasoconstrictor and 1.5 mL of 0.9% saline. The duration of the sensory block was evaluated in 4 postoperative moments (0, 4, 12 and 24 hours) as well as the need for rescue analgesia, nausea and vomiting incidence, and Visual Analog Pain Scale (VAS).

* Institution: Complexo Hospitalar Santa Genoveva, Uberlândia, MG, Brazil.

* Corresponding author.

E-mail: pontes_ufu@yahoo.com.br (J.P. Pontes).

PALAVRAS-CHAVE

Dexametasona;
Bloqueio de plexo
braquial;
Ultrassonografia;
Anestesia por
condução;
Artroscopia

Results: Seventy-four patients were recruited and 71 completed the study (Group C, n = 37; Group D, n = 34). Our findings showed a prolongation of the mean time of the sensitive blockade in Group D (1440 ± 0 min vs. 1267 ± 164 min, $p < 0.001$). It was observed that Group C had a higher mean pain score according to VAS (2.08 ± 1.72 vs. 0.02 ± 0.17 , $p < 0.001$) and a greater number of patients (68.4% vs. 0%, $p < 0.001$) required rescue analgesia in the first 24 hours. The incidence of postoperative nausea and vomiting was not statistically significant.

Conclusion: Perineural dexamethasone significantly prolonged the sensory blockade promoted by levobupivacaine in interscalene brachial plexus block, reduced pain intensity and rescue analgesia needs in the postoperative period.

© 2020 Sociedade Brasileira de Anestesiologia. Published by Elsevier Editora Ltda. This is an open access article under the CC BY-NC-ND license (<http://creativecommons.org/licenses/by-nc-nd/4.0/>).

Dexametasona perineural em bloqueio de plexo braquial interescalênico com levobupivacaína guiado por ultrassonografia para artroscopia de ombro em regime ambulatorial: ensaio clínico controlado e randomizado**Resumo**

Justificativa e objetivos: Na artroscopia de ombro em regime ambulatorial, o paciente necessita de um bom controle da dor pós-operatória, que pode ser conseguido por meio de bloqueios regionais. A dexametasona perineural pode prolongar o efeito desses bloqueios. O objetivo deste estudo foi avaliar o efeito da dexametasona perineural quanto ao prolongamento do bloqueio sensitivo no período pós-operatório para cirurgia artroscópica de ombro em regime ambulatorial.

Métodos: Após aprovação do Comitê de Ética em Pesquisa e consentimento informado, foram incluídos no estudo pacientes submetidos a cirurgia artroscópica de ombro sob anestesia geral e bloqueio de plexo braquial interescalênico guiado por ultrassonografia. Eles foram randomizados nos Grupo D – bloqueio com 30 mL de levobupivacaína 0,5% com vasoconstritor e 6 mg (1,5 mL) de dexametasona, e Grupo C – bloqueio com 30 mL de levobupivacaína 0,5% com vasoconstritor e 1,5 mL solução salina. A duração do bloqueio sensitivo foi avaliada em quatro momentos pós-operatórios (0, 4, 12 e 24 horas), assim como a necessidade de analgesia de resgate, incidência de náuseas e vômitos e Escala Visual Analógica de Dor (EVA).

Resultados: Setenta e quatro pacientes foram randomizados e 71 completaram o estudo (Grupo C, n = 37; Grupo D, n = 34). Observou-se um prolongamento do tempo médio de bloqueio sensitivo no Grupo D (1440 ± 0 min vs. 1267 ± 164 min; $p < 0,001$). Pacientes do Grupo C apresentaram maior média de escore de dor de acordo com a EVA ($2,08 \pm 1,72$ vs. $0,02 \pm 0,17$; $p < 0,001$) e um maior número de pacientes solicitou analgesia de resgate nas primeiras 24 horas (68,4% vs. 0%; $p < 0,001$). A incidência de náuseas e vômitos não foi estatisticamente significante.

Conclusão: A dexametasona perineural prolongou significativamente o bloqueio sensitivo da levobupivacaína no bloqueio de plexo braquial interescalênico, reduziu a intensidade de dor e a necessidade de analgesia de resgate pelo paciente no período pós-operatório.

© 2020 Sociedade Brasileira de Anestesiologia. Publicado por Elsevier Editora Ltda. Este é um artigo Open Access sob uma licença CC BY-NC-ND (<http://creativecommons.org/licenses/by-nc-nd/4.0/>).

Introduction

Shoulder arthroscopy is currently one of the most frequent orthopedic procedures and is mostly performed in the outpatient setting. Roughly 30% of patients submitted to shoulder arthroscopy report strong intensity pain on the first postoperative day, frequently requiring opioids for analgesia.¹⁻⁴ It is, therefore, a challenge to anesthesiologists, given appropriate pain management during the initial postoperative period is essential for the success of surgical outpatient treatment.¹

Regional blockades with local anesthetics are usually used to reduce moderate to strong intensity post-

operative pain,^{5,6} providing efficacious analgesia with minimum side effects when compared to opioids,^{2,7} albeit limited duration when given in single injections.^{2,3,6,7} Several drugs such as single injection block adjuvants like epinephrine,^{8,9} opioids,^{10,11} ketamine,^{11,12} and clonidine have been studied aiming to extend the analgesic effect.^{13,14}

Dexamethasone, a long-action and highly potent glucocorticoid, has been shown to prolong the effects of peripheral nerve blocks when added to local anesthetics.^{2-7,9,15-23} This effect seems to be mediated by several mechanisms of action, such as local vasoconstriction and/or direct effect on peripheral nerves,⁴ although, its use in outpatient surgery

has not been well established, given most studies assessed patients during longer inpatient stay periods.^{7,20}

The assumption of the present study was that dexamethasone changes the duration of interscalene brachial plexus block when added to local anesthetics. Thus, the objective of the study was to assess the effect of perineural dexamethasone on extending the duration of the sensorial block in the postoperative period of outpatient arthroscopic shoulder surgery in comparison to placebo.

Method

The prospective, randomized, parallel, double blind and controlled clinical trial was approved by the local Research Ethics Committee, and was conducted according to the Declaration of Helsinki and registered on Plataforma Brasil with the Ethical Appreciation Presentation Certificate (CAAE n° CAAE57509616.7.0000.5704). The study was also registered on the Brazilian Clinical Trials Registry (ReBEC) with protocol n° RBR-5yv2xr. All participating patients signed a consent form. Data were collected between January and July 2017 at Complexo Hospitalar Santa Genoveva and at the Uberlândia Medical Center, both located in the city of Uberlândia, Minas Gerais. The study protocol, design, and report followed the recommendations established by the Consolidated Standards of Reporting Trials – CONSORT).

Inclusion and exclusion criteria

Patients submitted to shoulder arthroscopy to repair rotator cuff tear in the outpatient setting were recruited for the study. Additional inclusion criteria were adult age group (aged between 18 and 65 years), American Society of Anesthesiology physical status 1 and 2 (ASA P1 and P2), Body Mass Index (BMI) < 30 kg.m⁻², and both genders.

Patients were excluded from the study if they presented one or more of the following criteria: skin infection on the puncture site, coagulopathy, brachial plexus neuropathy, use of systemic corticoids, routine use of opioids, diabetes, severe lung disease, psychiatric disorder and intolerance to one or more of the study drugs.

Randomization and masking

The Microsoft Excel® 2016 software Mersenne Twister (MT19937) algorithm was used to create random numbers to randomize the sequence between Group C (control) and D (dexamethasone) in the ratio of 1:1. Each number was printed and put into an opaque and sealed envelope.

The allocation to each group was determined upon admission to the operating room after the envelope was opened. All patients participating in the study were registered on a confidential table, in which each line was represented by one patient and pertaining medical record number, study allocation number and group to which he or she belonged to. The anesthesiologist responsible for admission, opening the envelope, and filling out the registration form was the same who prepared study medication. The anesthesiologist who performed the block was not aware of the group to which each patient belonged to and also was

responsible for assessing the outcomes of the study. Patient participants were not aware to which group they belonged to.

Intervention protocol

Patients were monitored with 5-lead electrocardiography, pulse oximetry, non-invasive arterial pressure, gas analyzer, capnography and anesthesia depth monitoring using bispectral index (BIS™, Medtronic, MN, US). General anesthesia was induced with 2 mg.kg⁻¹ propofol, 2 mcg.kg⁻¹ fentanyl, 0.6 mg.kg⁻¹ rocuronium and 1 mg.kg⁻¹ lidocaine without vasoconstrictor. Target-controlled infusion of propofol was maintained (plasma concentration between 1 and 4 mcg.mL⁻¹), as was continuous infusion of remifentanyl (0.1 to 0.3 mcg.kg⁻¹.min⁻¹). Patients were intubated and ventilated with an oxygen/nitrous oxide mixture (50/50), with 1 L.min⁻¹ fresh gas flow.

After induction of general anesthesia, antisepsis of puncture site was performed with 2% alcohol chlorhexidine. Ultrasound-guided location of interscalene brachial plexus was performed with a 13 MHz linear transducer (SonoSite NanoMaxx®, Bothel, WA – US), puncture with a 22G A50 needle (Stimuplex®, B. Braun, Melsungen AG – Germany), and injection of 30 mL of perineural anesthetic solution (2) and 1.5 mL of the study drug prepared in a separate 3 mL syringe according to randomization. In Group D, 30 mL of 0.5% levobupivacaine (Novabupi®, Laboratório Cristália, RJ, Brazil) was injected with vasoconstrictor (adrenaline 1:200.000) + 6 mg (1.5 mL) of dexamethasone (Decadron®, Aché Laboratórios Farmacêuticos S.A., SP, Brazil), and in Group C 30 mL of 0.5% levobupivacaine with vasoconstrictor (adrenaline 1:200.000) + 1.5 mL of 0.9% saline.

In order to perform shoulder arthroscopy, patients were placed in the beach chair position. During the intraoperative period, patients were medicated with 4 mg of dexamethasone and 4 mg of ondansetron for nausea and vomiting prophylaxis. To provide multimodal postoperative pain control, we associated the regional block with 2 g of dipyron and 100 mg of ketoprofen administered via systemic route. After finishing the arthroscopic procedure, patients were extubated and sent to the Post-Anesthesia Care Unit (PACU).

Postoperative and outcome assessment

Patients were assessed four times during the postoperative period: in the Postoperative Care Unit (PACU) and 4, 12 and 24 hours after the procedure, and upon hospital discharge. The duration of the sensorial block (in minutes) was established as the primary outcome and tested with cotton soaked in alcohol solution. Tactile or temperature sensations at the shoulder area were tested, and an affirmative answer to at least one of them led to considering the sensorial block had ended. When there were complaints of pain in the interval between assessments, this time was considered as the end of the sensorial block. The end of the local anesthetic solution injection was the starting time for the assessment of block duration.

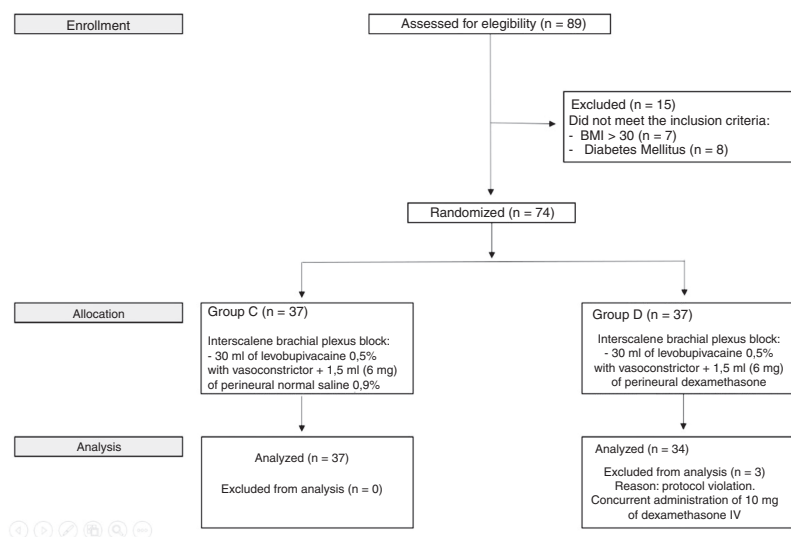


Figure 1 CONSORT flow diagram.

The secondary outcomes assessed were: intensity of pain measured by the Visual Analogical Scale (VAS), incidence of Postoperative Nausea and Vomiting (PONV), need for rescue analgesia in the initial 24 hours (beginning with dipyrone and ketoprofen and, if required, tramadol), and rate of block failure index, characterized by complaint of pain or unchanged sensitivity on the limb operated on at the PACU. Patients were oriented to ask for analgesics as soon as they began feeling pain.

The surgeon saw patients seven days after the procedure when the presence of any neurological alteration that could be attributed to regional anesthesia was assessed.

Sample calculation and statistical analysis

The sample was calculated considering the mean duration of the block as 730 minutes with long action local anesthetic, and a prolongation effect of 75% of the sensorial block with the addition of dexamethasone, according to findings in a previous publication,⁴ and alpha error of 5% and test power of 80%. Toward that end, 34 participants per group were required for bicaudal analysis. Taking into account losses and withdrawals of 10% of participants, the sample was calculated as 74 participants.

The D'Agostino test was used to assess the normality of the distribution of the variables studied. We used the Student *t*-test for independent samples to compare the duration of the sensorial block, weight, age and body mass index. For VAS, comparison between groups was performed using the adjustment in a generalized linear model with Poisson distribution, followed by the Wald multiple comparison test. The Chi-Square or exact Fisher test were used to compare sex ratio, ASA classification, incidence of PONV and rescue analgesia. Quantitative variables are presented as means \pm standard deviation. Nominal categorical variables are presented in absolute figures (valid percentages). We considered $p < 0.05$ as the significant statistical level. SAS software, version 9.3, was used for statistical analysis of data.

Results

Seventy-four patients were randomized and 71 completed the study, 34 patients in Group D and 37 patients in Group C. Three patients of Group D were excluded from the analysis due to protocol violation. The details of the conduction of the study are presented in Figure 1. Patient baseline demographic data are presented in Table 1 and there were no differences between groups.

Univariate analysis was performed, and we used multivariate analysis for variables that presented significance ($p < 0.01$). The procedure was aimed at controlling possible result confounders. In the model studied, the only significant variable was duration of sensorial block ($r^2 = 0.56$, $p < 0.001$). We calculated the Odds Ratio of 0.008 with a Confidence Interval (CI) of 0.0005–0.1408 ($p < 0.001$) to assess dexamethasone as a protective factor for pain.

The findings of the study showed an extension of the mean duration of sensorial block in Group D ($p < 0.001$) (Table 2; Fig. 2). Group C presented a higher pain score mean at the 24-hour assessment ($p < 0.001$) (Table 2; Fig. 3). No patients complained of pain at the 0, 4 and 12-hour assessments. The incidence of PONV was higher in Group C, but not statistically significant ($p = 0.16$) (Table 2). In Group C, 24 patients (68.4%) required at least one dose of rescue analgesia, while in Group D, none of the patients asked for postoperative analgesia ($p < 0.001$) (Table 2).

There were no block failures among patients in both Groups. After seven days, at the surgeon follow-up appointment, none of the patients had neurological abnormalities or complaints that could be attributed to regional anesthesia.

Discussion

The results of the present study have shown that perineural dexamethasone extends significantly mean duration of sensorial block promoted by levobupivacaine for interscalene brachial plexus block, which corroborates similar findings of

Table 1 Baseline characteristics of the population studied.

Variables	Group C (n = 37)	Group D (n = 34)	p-value
Age (years)	47.2 ± 13	50.7 ± 11	0.25 ^a
Gender (F/M) %	46/54	59/41	0.70 ^b
Weight (kg)	70.4 ± 11	65.4 ± 11	0.16 ^a
BMI	27.2 ± 4.0	27.4 ± 5.2	0.73 ^a
ASA Physical Status			0.97 ^b
I	23 (62.1)	21 (61.7)	
II	14 (37.9)	13 (38.3)	

Values presented as means ± standard deviation and numbers (%). BMI, Body Mass Index; ASA, American Society of Anesthesiologists; F, female; M, male; Group C, Control Group; Group D, Dexamethasone Group.

^a Student *t*-Test for independent samples was used to compare groups.

^b Chi-square test was used to compare groups.

Table 2 Distribution of outcomes studied among groups.

Outcomes	Group C (n = 37)	Group D (n = 34)	p-value
Sensorial Block Time (min)	1267 ± 164	1440 ± 0	< 0.001 ^a
24-hour VAS	2.08 ± 1.72	0.02 ± 0.17	< 0.001 ^b
Rescue analgesia	24 (68.4)	0 (0)	< 0.001 ^c
PONV	2 (5.4)	0 (0)	0.16 ^d

Values presented as means ± standard deviation and numbers (%). VAS, Pain Visual Analog Scale; PONV, postoperative nausea and vomiting; Group C, Control Group; Group D, Dexamethasone Group.

^a Student *t*-Test for independent samples was used to compare groups.

^b Multiple comparison Wald Test was used to compare groups.

^c Chi-square test was used to compare groups.

^d Fisher Exact Test was used to compare groups.

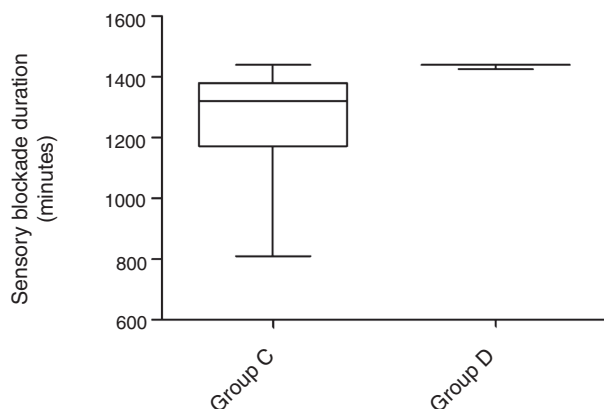


Figure 2 Postoperative duration of sensorial block. Group C, Control Group; Group D, Dexamethasone Group. Student *t*-test was used for independent samples to compare groups ($p < 0.001$).

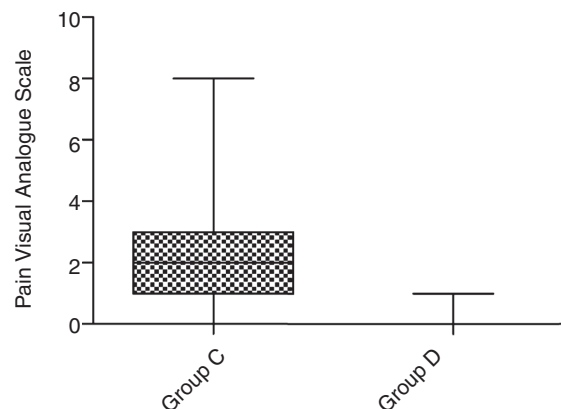


Figure 3 Pain Visual Analog Scale (VAS) in the initial 24 hours. Group C, Control Group; Group D, Dexamethasone Group. Comparison between groups was performed using the adjustment in a generalized linear model with Poisson distribution, followed by the Wald multiple comparison test ($p < 0.001$).

the literature^{2,9,15-23} in which dexamethasone prolonged in up to 720 minutes the effect of local anesthetic.⁷

Glucocorticoids are believed to yield modest local vasoconstriction that in turn could reduce the absorption of local anesthetics and consequently extend the contact time of the local anesthetic with the nerve and, thus, prolong the duration of the sensorial block.¹⁵ Another theory is that the analgesic effects of dexamethasone are mediated by increase in the activity of inhibitory potassium channels on nociceptive C fibers.¹⁵

We also observed reduction in pain intensity, assessed by VAS, and lower consumption of rescue analgesia in the dexamethasone group during inpatient stay. These findings are in agreement with the literature, in which the use of dexamethasone was associated with reduction in the cumulative use of opioid^{5,7} and lower pain scores^{5,7,22} during the initial 24 postoperative hours.

Improvement in analgesia with dexamethasone for shoulder surgery^{2-7,9,15-24} has been observed regardless of

intravenous^{2,3,17,19,21,24} or perineural administration route of the drug.^{4-7,9,15,16,18,20,22,23} In the present study, the lower intensity pain scores in the dexamethasone Group may be attributed both to the higher cumulative dose of dexamethasone used in the group and the increased duration of the sensorial block. However, the increased duration of the sensorial block, tested by the tactile and thermal test, cannot be explained by possible systemic effects of dexamethasone, underscoring an actual effect of the drug in prolonging the effect of local anesthetics.

To date, dexamethasone seems to be the best adjuvant method to prolong the duration of sensorial blocks, superior to clonidine, epinephrine or midazolam.^{9,25} Moreover, its safety profile is promising, with a low risk of neurotoxicity.²² Perineural use in diabetic patients does not significantly change blood glucose levels, given hyperglycemia induced by steroids has only been confirmed in high dose regimens of intravenous dexamethasone.²² None of the patients in our study presented signs or symptoms of neurotoxicity attributed to dexamethasone, although the sample size was insufficient to detect rare results, and patients were not followed-up beyond seven days, date of the last surgeon follow-up assessment.

Regarding PONV, studies have shown that after 24 postoperative hours, the complication is reduced in patients in whom dexamethasone was used as a perineural adjuvant.^{5,22} In the present study, the incidence of PONV in Group D was lower, in agreement with the literature, albeit there was no statistical significance due to its low occurrence. The effect can be attributed to a higher cumulative dose of dexamethasone in the intervention group, although the study was not designed to detect such a difference.

The major limitation of the study was restricting patient outcome follow-up to a 24-hour period because of the outpatient nature of the surgical procedure. In this scenario, all patients in the dexamethasone group still presented the sensorial block when discharged, totaling a period of 1,440 minutes (24 hours). The fact prevented the assessment of the actual duration of the sensorial block in patients who received perineural dexamethasone, which could have been lengthier than the observed. Another limitation of the study was the concomitant use of a 4-mg intravenous dose of dexamethasone in both groups as a strategy to reduce nausea and vomiting. The management may have increased the duration of analgesia in the control group and, consequently, falsely increased the mean duration of the sensorial block in the same group, given that, within the interval between assessments, the sensorial block was considered extinguished at the time when the patient asked for rescue analgesia.

In addition to extending the duration of the sensorial block, the present study showed that adding perineural dexamethasone to single-shot block techniques is an interesting strategy to avoid using rescue analgesics in outpatient surgery, given that none of the patients of the perineural dexamethasone group required medication to control pain during inpatient stay. The absence of signs of neurotoxicity or complications associated with dexamethasone corroborates the safety of its use in this scenario. This study also tested 6 mg, a novel dose of perineural dexamethasone, which had not been described in the literature until the time of our study, and that also enabled to administer a dimin-

ished prophylactic intravenous dose of dexamethasone to patients for nausea and vomiting.

Despite the short follow-up, the present study is a baseline for future investigations in outpatient surgery, to determine exactly how long the sensorial block duration is prolonged by perineural dexamethasone, the reduction in costs associated with less consumption of rescue analgesia and the incidence of possible side effects, such as late neurotoxicity.

Conclusion

Perineural dexamethasone, as an adjuvant to levobupivacaine, proved to be capable of prolonging the duration of the sensorial component of the brachial plexus block for outpatient shoulder arthroscopy surgery. Perineural dexamethasone reduced pain intensity and patient requirement for rescue analgesia during the postoperative period.

Conflicts of interest

The authors declare no conflicts of interest.

References

- Hughes M, Matava M, Wright R, et al. Interscalene brachial plexus block for arthroscopic shoulder surgery: a systematic review. *J Bone Joint Surg Am.* 2013;95:1318-24.
- Desmet M, Braems H, Reynvoet M, et al. I.V. and perineural dexamethasone are equivalent in increasing the analgesic duration of a single-shot interscalene block with ropivacaine for shoulder surgery: a prospective, randomized, placebo-controlled study. *Br J Anaesth.* 2013;111:445-52.
- Kawanishi R, Yamamoto K, Tobetto Y, et al. Perineural but not systemic low-dose dexamethasone prolongs the duration of interscalene block with ropivacaine: a prospective randomized trial. *Local Reg Anesth.* 2014;7:5-9.
- Choi S, Rodseth R, McCartney C. Effects of dexamethasone as a local anaesthetic adjuvant for brachial plexus block: a systematic review and meta-analysis of randomized trials. *Br J Anaesth.* 2014;112:427-39.
- Albrecht E, Kern C, Kirkham K. A systematic review and meta-analysis of perineural dexamethasone for peripheral nerve blocks. *Anaesthesia.* 2015;70:71-83.
- De Oliveira G, Castro Alves L, Nader A, et al. Perineural dexamethasone to improve postoperative analgesia with peripheral nerve blocks: a meta-analysis of randomized controlled trials. *Pain Res Treat.* 2014;2014:179029.
- Tandoc M, Fan L, Kolesnikov S, et al. Adjuvant dexamethasone with bupivacaine prolongs the duration of interscalene block: a prospective randomized trial. *J Anesth.* 2011;25:704-9.
- Song J, Shim H, Lee T, et al. Comparison of dexmedetomidine and epinephrine as an adjuvant to 1% mepivacaine in brachial plexus block. *Korean J Anesthesiol.* 2014;66:283-9.
- El-Baradei G, Elshmaa N. The efficacy of adding dexamethasone, midazolam, or epinephrine to 0.5% bupivacaine in supraclavicular brachial plexus block. *Saudi J Anaesth.* 2014;8 Suppl. 1:578-83.
- Nagpal V, Rana S, Singh J, et al. Comparative study of systemically and perineurally administered tramadol as an adjunct for supraclavicular brachial plexus block. *J Anaesthesiol Clin Pharmacol.* 2015;31:191-5.

11. Senel A, Ukinc O, Timurkaynak A. Does the addition of tramadol and ketamine to ropivacaine prolong the axillary brachial plexus block? *Biomed Res Int.* 2014;2014:686287.
12. Lashgarinia M, Naghibi K, Honarmand A, et al. Effect of ketamine as an adjuvant in ultrasound-guided supraclavicular brachial plexus block: a double-blind randomized clinical trial study. *Adv Biomed Res.* 2014;3:232.
13. Ali Q, Manjunatha L, Amir S, et al. Efficacy of clonidine as an adjuvant to ropivacaine in supraclavicular brachial plexus block: a prospective study. *Indian J Anaesth.* 2014;58:709–13.
14. Gupta K, Tiwari V, Gupta P, et al. Clonidine as an adjuvant for ultrasound guided supraclavicular brachial plexus block for upper extremity surgeries under tourniquet: a clinical study. *J Anaesthesiol Clin Pharmacol.* 2014;30:533–7.
15. Knezevic N, Anantamongkol U, Candido K. Perineural dexamethasone added to local anesthesia for brachial plexus block improves pain but delays block onset and motor blockade recovery. *Pain Physician.* 2015;18:1–14.
16. Kumar S, Palaria U, Sinha A, et al. Comparative evaluation of ropivacaine and ropivacaine with dexamethasone in supraclavicular brachial plexus block for postoperative analgesia. *Anesth Essays Res.* 2014;8:202–8.
17. Abdallah F, Johnson J, Chan V, et al. Intravenous dexamethasone and perineural dexamethasone similarly prolong the duration of analgesia after supraclavicular brachial plexus block: a randomized, triple-arm, double-blind, placebo-controlled trial. *Reg Anesth Pain Med.* 2015;40:125–32.
18. Jadon A, Dixit S, Kedia S, et al. Interscalene brachial plexus block for shoulder arthroscopic surgery: Prospective randomised controlled study of effects of 0.5% ropivacaine and 0.5% ropivacaine with dexamethasone. *Indian J Anaesth.* 2015;59:171–6.
19. Chun E, Kim Y, Woo J. Which is your choice for prolonging the analgesic duration of single-shot interscalene brachial blocks for arthroscopic shoulder surgery? Intravenous dexamethasone 5 mg vs. perineural dexamethasone 5 mg randomized, controlled, clinical trial. *Medicine (Baltimore).* 2016;95:e3828.
20. Cummings KR, Napierkowski D, Parra-Sanchez I, et al. Effect of dexamethasone on the duration of interscalene nerve blocks with ropivacaine or bupivacaine. *Br J Anaesth.* 2011;107:446–53.
21. Holland D, Amadeo R, Wolfe S, et al. Effect of dexamethasone dose and route on the duration of interscalene brachial plexus block for outpatient arthroscopic shoulder surgery: a randomized controlled trial. *Can J Anaesth.* 2018;65:34–45.
22. Sakae T, Marchioro P, Schuelter-Trevisol F, et al. Dexamethasone as a ropivacaine adjuvant for ultrasound-guided interscalene brachial plexus block: a randomized, double-blinded clinical trial. *J Clin Anesth.* 2017;38:133–6.
23. Woo J, Kim Y, Kim D, et al. Dose-dependency of dexamethasone on the analgesic effect of interscalene block for arthroscopic shoulder surgery using ropivacaine 0.5%: a randomised controlled trial. *Eur J Anaesthesiol.* 2015;32:650–5.
24. Chalifoux F, Colin F, St-Pierre P, et al. Low dose intravenous dexamethasone (4 mg and 10 mg) significantly prolongs the analgesic duration of single-shot interscalene block after arthroscopic shoulder surgery: a prospective randomized placebo-controlled study. *Can J Anaesth.* 2017;64:280–9.
25. Shah DM, Arora M, Trikha A, et al. Comparison of dexamethasone and clonidine as an adjuvant to 1.5% lignocaine with adrenaline in infraclavicular brachial plexus block for upper limb surgeries. *J Anaesthesiol Clin Pharmacol.* 2015;31:354–9.