


## CASE REPORTS

# Hydatid cyst in the cervical spinal cord complicated by potentially life-threatening difficult airway: a case report



Dmitriy Viderman <sup>a,c,\*</sup>, Aisa Nurpeisov<sup>b</sup>, Omirzhan Balabayev<sup>b</sup>,  
Yermek Urunbayev<sup>c</sup>, Guilherme de Almeida<sup>d</sup>, Federico Bilotta<sup>d</sup>

<sup>a</sup> Nazarbayev University School of Medicine (NUSOM), Department of Biomedical Sciences, Astana, Kazakhstan

<sup>b</sup> National Neurosurgery Center, Department of Anesthesiology and Critical Care, Astana, Kazakhstan

<sup>c</sup> National Neurosurgery Center, Department of Spinal Neurosurgery, Astana, Kazakhstan

<sup>d</sup> UniversityLa Sapienza, Department of Anesthesia and Intensive Care, Rome, Italy

Received 6 July 2019; accepted 1 August 2020

Available online 7 September 2020

### KEYWORDS

Airway management;  
Intratracheal  
intubation;  
Airway obstruction;  
Cystic echinococcosis

### PALAVRAS-CHAVE

Manuseio das vias  
aéreas;  
Intubação  
intratraqueal;  
Obstrução das vias  
respiratórias;  
Equinococose

**Abstract** Hydatid cyst in the cervical region is an extremely rare condition that can create challenges for anesthesiologists. Timely recognition of difficult airway and preparing the management plan is crucial to avoid life-threatening complications such as hypoxic brain damage. We describe a case of difficult airway management in a patient with massive cervical hydatid cyst. We used a low-dose ketamine-propofol sedation and lidocaine spray for local oropharyngeal anesthesia. Muscular relaxants were not used, and spontaneous breathing was maintained during intubation. Recognition, assessment, and perioperative planning are essential for difficult airway management in patients with cervical hydatid cyst.

© 2020 Sociedade Brasileira de Anestesiologia. Published by Elsevier Editora Ltda. This is an open access article under the CC BY-NC-ND license (<http://creativecommons.org/licenses/by-nc-nd/4.0/>).

### Cisto hidático na medula cervical complicada por via aérea difícil com potencial risco de vida: relato de caso

**Resumo** O cisto hidático na região cervical é uma condição extremamente rara que pode criar desafios para os anesthesiologistas. O reconhecimento oportuno das vias aéreas difíceis e a preparação do plano de manejo são cruciais para evitar complicações com risco de vida, como danos cerebrais hipóxicos. Descrevemos um caso de difícil controle das vias aéreas em um paciente com cisto hidático cervical maciço. Utilizamos sedação com cetamina-propofol

\* Corresponding author.

E-mail: [dmitriy.viderman@nu.edu.kz](mailto:dmitriy.viderman@nu.edu.kz) (D. Viderman).

em baixa dose e spray de lidocaína para anestesia local orofaríngea. Relaxantes musculares não foram utilizados e a respiração espontânea foi mantida durante a intubação. O reconhecimento, a avaliação e o planejamento perioperatório são essenciais para o manejo difícil das vias aéreas em pacientes com cisto hidático cervical.

© 2020 Sociedade Brasileira de Anestesiologia. Publicado por Elsevier Editora Ltda. Este é um artigo Open Access sob uma licença CC BY-NC-ND (<http://creativecommons.org/licenses/by-nc-nd/4.0/>).

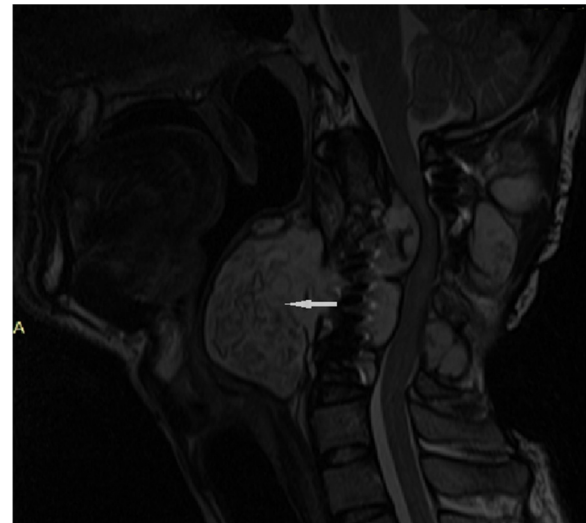
## Introduction

Hydatid disease is an infection caused by *Echinococcus granulosus*, which is most prevalent in South America, South East Asia, New Zealand, Australia, Middle East.<sup>1</sup> Spinal hydatid cysts occur in 1% of all cases and are most frequently located in the dorsal part of the spine.<sup>2</sup> In the initial stages, the hydatid disease is usually asymptomatic and the definite diagnosis is made by imaging methods, such as ultrasonography, Computed Tomography (CT), Magnetic Resonance Imaging (MRI) and immune diagnostics.<sup>3</sup> Cervical location of hydatid cyst can create challenges for neurosurgeons and anesthesiologists. Failure to provide an adequate airway management might lead to dangerous, potentially lethal consequences. Timely recognition of difficult airway and preparing the management plan is crucial to avoid life-threatening complications such as hypoxic brain damage and death. The purpose of this case report is to present our insights regarding the management of a patient with giant hydatid cyst in the cervical spinal cord which caused the obstruction of the airway from the anesthesiology perspective.

## Case presentation

A 25-year-old male patient was admitted to the spinal neurosurgery department at the National Neurosurgery Center with a history of recurrence of hydatid cyst in the cervical spinal cord. He was previously hospitalized in our hospital three years before for hydatid cyst removal at the level of C3-C4-C5, resection of vertebral bodies of C3-C4-C5, spondylodesis C2-C6. During a period of 3 years, the disease recurred and led to severe obstruction of the airway. On admission, MRI showed a progressive growth of hydatid cyst in the cervical spinal cord region with outgrowth to the paravertebral region, compression of the spinal cord, myelomalacia at the level of C3-C4 (Fig. 1).

On a routine preanesthetic examination, it was revealed that there was no neck extension due to spondylodesis and there was grade IV Score on a modified Mallampati classification. The pharynx was almost completely obstructed by the displaced posterior pharyngeal wall due to hydatid cyst growth. He was slightly agitated, most likely due to mild hypoxia and hypercapnia. His SpO<sub>2</sub> was 89%–92%–94%, pO<sub>2</sub> was 81 mm.Hg; while receiving 3 liters of oxygen per minute via nasal cannulae, pCO<sub>2</sub> was 48 mm. Hg, noninvasive blood pressure was 140/90 mm.Hg and pulse rate was



**Figure 1** Cervical MRI sagittal section of the head and neck shows progressive growth of hydatid cyst (arrow), compression of cervical spinal cord, esophagus, and airway (trachea, larynx, pharynx).

88 per minute. The patient was emergently delivered to the operating room.

In the operation room, we applied the standard anesthetic monitoring, including peripheral hemoglobin saturation, pulse, ECG, noninvasive blood pressure and temperature monitoring. After peripheral vein catheterization with na 18G intravenous cannula, we began infusion of normal saline. Since difficult intubation was expected, we invited an endoscopist, brought a difficult airway cart and set for establishing a surgical airway. We failed to perform the preoperative airway endoscopy (as an advanced method of airway assessment) because it was impossible to pass the endoscope through the compressed pharyngeal, laryngeal and tracheal areas. Since the patient was agitated and not fully cooperative, we did not consider awake intubation under the regional block and decided to perform tracheal intubation under minimal-to-moderate sedation and topical oropharyngeal anesthesia on spontaneous breathing.

We used the following intubation technique: conscious preoxygenation with 100% oxygen for 6 minutes followed by minimal sedation, which included intravenous administration of propofol 0.5 mg.kg<sup>-1</sup> for sedation and a sub-hypnotic dose of ketamine (0.7 mg.kg<sup>-1</sup>) for analgesia, 10% lidocaine spray for topical oropharyngeal anesthesia, with no muscular blocking agents; spontaneous breathing was preserved. Prior

to laryngoscopy, 10% lidocaine was sprayed in the pharynx for local oropharyngeal anesthesia. After the direct laryngoscopy, a fiberoptic bronchoscope was inserted into the trachea and the endotracheal tube was railroaded over it under visual control. The correct location was confirmed by fiberoptic visualization, EtCO<sub>2</sub>, bilateral auscultation of the lungs. This method allowed us to preserve high oxygen status, minimize the risk of respiratory depression and shorten induction-to-intubation time while providing adequate analgesia. Arterial saturation did not fall below 90% during the period of induction and intubation. The surgery lasted three hours and was completed successfully. After the surgery, the patient was transferred to the Post-Anesthesia Care Unit (PACU) and uneventfully extubated after complete emergence from anesthesia.

## Discussion and conclusion

Preparation for difficult airway management should include equipment for the management of difficult airways, informing and inviting assistants for difficult airway management, pre-oxygenation with 100% oxygen, administration of oxygen during airway management.<sup>4</sup> Cervical hydatid cysts might be recognized as a potential cause of difficult airway. Since such patients can present with airway obstruction, it might be impossible to use some options of difficult airway management, such as laryngeal mask. The difficult airway strategy should be planned in advance: the choice of hypnotics, its dose, and depth of sedation might play a crucial role, and even a minor error can lead to tragic consequences. Our patient had several risk factors for difficult airway. First, he was admitted to the hospital in the advanced stage of the disease, with severe narrowing of the pharynx, larynx and trachea which led to difficulties in breathing. It could have resulted in severe respiratory failure if he was admitted even several days later. Second, since he was performed cervical spondylodesis recently, neck flexions and extensions were absent, which caused additional difficulties in airway management. Prior to the surgery, he became agitated and it was difficult to maintain cooperation, therefore, we did not use regional anesthesia for awake intubation. We decided to perform intubation on spontaneous breathing. We slowly titrated a combination of subhypnotic dose of ketamine (0.7 mg.kg<sup>-1</sup>) and propofol (0.5 mg.kg<sup>-1</sup>). The massive spraying of the oropharyngeal area with lidocaine seemed to provide additional topical anesthesia. The patient was adequately sedated, and the spontaneous breathing was preserved. An alternative to low dose ketamine and propofol could be dexmedetomidine,

which has been used for "conscious induction" although there are just a few cases published to date.<sup>5</sup>

Although the method we used was successful, the following methods could be also considered in this situation: 1) Conscious sedation with dexmedetomidine + regional anesthesia and topical oropharyngeal anesthesia with lidocaine spray followed by orotracheal intubation; 2) Establishing a surgical airway under regional anesthesia with the assistance of an ENT surgeon. However, since cervical anatomy in our patient was distorted (due to the hydatid cyst), surgical airway could be also difficult to establish. Although this single case cannot account for reliability, we believe that it can be useful for practicing anesthesiologists.

In conclusion, this case highlights difficult airway management in a patient with hydatid cyst in the cervical spinal cord. Hydatid cyst in the cervical spinal cord can cause life-threatening complications, and the most fearful of them is airway obstruction leading to difficult airway. Recognition, assessment, and preoperative planning of difficult airway management is essential for surgical treatment of cervical hydatid cyst.

## Conflicts of interest

D. Viderman, A. Nurpeisov, O. Balabayev, Y. Urumbayev, G. de Almeida, F. Bilotta declare that they have no competing interests. This article does not contain any studies with human participants or animals performed by any of the authors. For images or other information within the manuscript which identify patients, written informed consent was obtained from the legal guardian of the patient for publication of this case report.

## References

1. Jarboui S, Hlel A, Daghfous A, et al. Unusual location of primary hydatid cyst: soft tissue mass in the supraclavicular region of the neck. *Case reports in medicine*. 2012.
2. Pamir MN, Akalan N, Özgen T, et al. Spinal hydatid cysts. *Surgical neurology*. 1984;21:53–7.
3. Zhang W, McManus DP. Recent advances in the immunology and diagnosis of echinococcosis. *FEMS Immunol Med Microbiol*. 2006;47:24–41.
4. Apfelbaum JL, Hagberg CA, Caplan RA, et al. Practice guidelines for management of the difficult airway updated report by the American Society of Anesthesiologists task force on management of the difficult airway. *Anesthesiology*. 2013;118:251–70.
5. Bergese SD, Khabiri B, Roberts WD, et al. Dexmedetomidine for conscious sedation in difficult awake fiberoptic intubation cases. *Journal of clinical anesthesia*. 2007;19:141–4.