



# REVISTA BRASILEIRA DE ANESTESIOLOGIA

Publicação Oficial da Sociedade Brasileira de Anestesiologia  
[www.sba.com.br](http://www.sba.com.br)



## SCIENTIFIC ARTICLE

# Ultrasound-guided transversus abdominis plane block in patients undergoing laparoscopic cholecystectomy: comparison of efficacy of bupivacaine and levobupivacaine on postoperative pain control



Arzu Yıldırım Ar<sup>a,\*</sup>, Dilek Erdoğan Arı<sup>a</sup>, Yıldız Yiğit Kuplay<sup>a</sup>, Yalın İşcan<sup>b</sup>,  
Firdevs Karadoğan<sup>a</sup>, Damla Kırım<sup>a</sup>, Fatma Nur Akgün<sup>a</sup>

<sup>a</sup> Fatih Sultan Mehmet Educational and Research Hospital, Anesthesiology and Reanimation Department, Istanbul, Turkey

<sup>b</sup> Fatih Sultan Mehmet Educational and Research Hospital, General Surgery Department, Istanbul, Turkey

Received 18 July 2017; accepted 11 February 2018

Available online 17 March 2018

### KEYWORDS

Bupivacaine;  
Cholecystectomy;  
Laparoscopic surgery;  
Levobupivacaine;  
Postoperative  
analgesia

### Abstract

**Background and objective:** The use of transversus abdominis plane block with different local anesthetics is considered as a part of multimodal analgesia regimen in laparoscopic cholecystectomy patients. However no studies have been published comparing bupivacaine and levobupivacaine for transversus abdominis plane block. We aimed to compare bupivacaine and levobupivacaine in ultrasound-guided transversus abdominis plane block in patients undergoing laparoscopic cholecystectomy.

**Methods:** Fifty patients (ASA I/II), undergoing laparoscopic cholecystectomy were randomly allocated into two groups. Following anesthesia induction, ultrasound-guided bilateral transversus abdominis plane block was performed with 30 mL of bupivacaine 0.25% in Group B ( $n=25$ ) and 30 mL of levobupivacaine 0.25% in Group L ( $n=25$ ) for each side. The level of pain was evaluated using 10 cm visual analog scale (VAS) at rest and during coughing 1, 5, 15, 30 min and 1, 2, 4, 6, 12 and 24 h after the operation. When visual analogue scale  $> 3$ , the patients received IV tenoxicam 20 mg. If visual analogue scale remained  $> 3$ , they received IV tramadol 1 mg.kg<sup>-1</sup>. In case of inadequate analgesia, a rescue analgesic was given. The analgesic requirement, time to first analgesic requirement was recorded.

**Results:** Visual analogue scale levels showed no difference except first and fifth minutes post-operatively where VAS was higher in Group L ( $p < 0.05$ ). Analgesic requirement was similar in both groups. Time to first analgesic requirement was shorter in Group L ( $4.35 \pm 6.92$  min vs.  $34.91 \pm 86.26$  min,  $p = 0.013$ ).

\* Corresponding author.

E-mail: [dr.arzuyildirim@hotmail.com](mailto:dr.arzuyildirim@hotmail.com) (A. Yıldırım Ar).

**PALAVRAS-CHAVE**

Bupivacaína;  
 Colectistectomia;  
 Cirurgia  
 laparoscópica;  
 Levobupivacaína;  
 Analgesia  
 pós-operatória

**Conclusions:** Bupivacaine and levobupivacaine showed similar efficacy at TAP block in patients undergoing laparoscopic cholecystectomy.

© 2018 Sociedade Brasileira de Anestesiologia. Published by Elsevier Editora Ltda. This is an open access article under the CC BY-NC-ND license (<http://creativecommons.org/licenses/by-nc-nd/4.0/>).

### Bloqueio do plano abdominal transversal guiado por ultrassom em pacientes submetidos à colecistectomia laparoscópica: comparação da eficácia de bupivacaína e levobupivacaína no controle da dor pós-operatória

**Resumo**

**Justificativa e objetivo:** O uso do bloqueio do plano transversal abdominal com diferentes anestésicos locais é considerado como parte do regime de analgesia multimodal em pacientes submetidos à colecistectomia laparoscópica. No entanto, nenhum estudo comparando bupivacaína e levobupivacaína para bloqueio do plano transversal abdominal foi publicado. Nosso objetivo foi comparar bupivacaína e levobupivacaína em bloqueio do plano transversal abdominal guiado por ultrassom em pacientes submetidos à colecistectomia laparoscópica.

**Métodos:** Cinquenta pacientes (ASA I/II), submetidos à colecistectomia laparoscópica foram alocados aleatoriamente em dois grupos. Após a indução da anestesia, o bloqueio do plano transversal abdominal bilateral guiado por ultrassom foi realizado com 30 mL de bupivacaína a 0,25% no Grupo B ( $n = 25$ ) e 30 mL de levobupivacaína a 0,25% no Grupo L ( $n = 25$ ) para cada lado. O nível de dor foi avaliado usando a escala visual analógica de 10 cm em repouso e durante a tosse em 1, 5, 15, 30 minutos e em 1, 2, 4, 6, 12 e 24 horas após a operação. Quando a escala visual analógica  $> 3$ , os pacientes receberam 10 mg de tenoxicam por via intravenosa (IV). Se a escala visual analógica permanecesse  $> 3$ , os pacientes recebiam tramadol IV ( $1 \text{ mg} \cdot \text{kg}^{-1}$ ). Em caso de analgesia inadequada, um analgésico de resgate foi administrado. A necessidade de analgésico e o tempo até a primeira solicitação de analgésico foram registrados.

**Resultados:** Os escores da escala visual analógica não mostraram diferença, exceto no primeiro e quinto minutos de pós-operatório, onde a escala visual analógica foi maior no Grupo L ( $p < 0,05$ ). A necessidade de analgésico foi semelhante em ambos os grupos. O tempo até a primeira solicitação de analgésico foi menor no Grupo L ( $4,35 \pm 6,92 \text{ min}$  vs.  $34,91 \pm 86,26 \text{ min}$ ,  $p = 0,013$ ).

**Conclusões:** Bupivacaína e levobupivacaína apresentaram eficácia similar no bloqueio TAP em pacientes submetidos à colecistectomia laparoscópica.

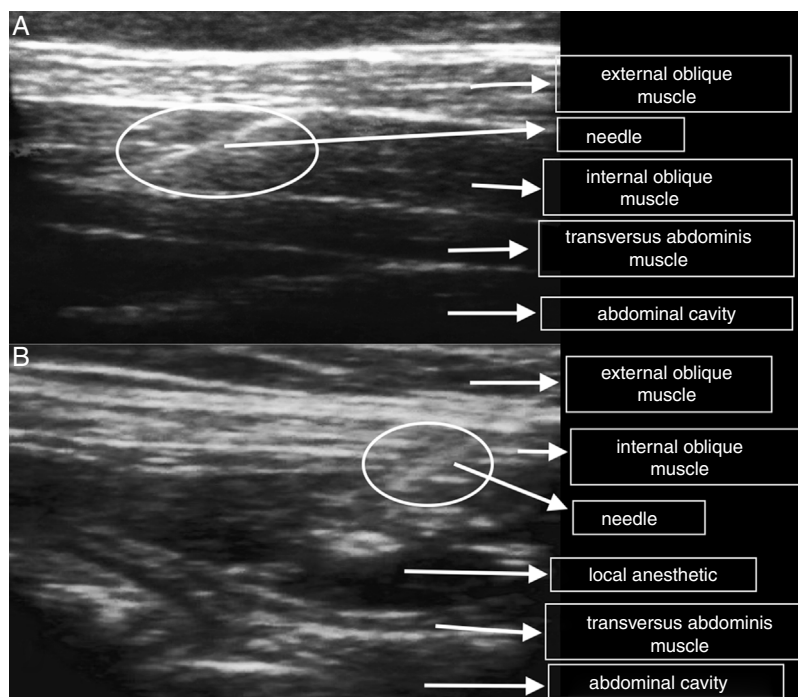
© 2018 Sociedade Brasileira de Anestesiologia. Publicado por Elsevier Editora Ltda. Este é um artigo Open Access sob uma licença CC BY-NC-ND (<http://creativecommons.org/licenses/by-nc-nd/4.0/>).

**Introduction**

Although laparoscopic cholecystectomy is a minimally invasive procedure, moderate level pain is observed in the early postoperative period, especially in the first 24 h due to various reasons.<sup>1,2</sup> Management of the postoperative pain is important as it increases the length of stay in the hospital and the risk of morbidity. Multimodal analgesia management is utilized for pain observed in the postoperative period. For this purpose, Nonsteroidal Anti-Inflammatory Drugs (NSAIDs), paracetamol, opioids, gabapentinoids and other similar medications are utilized. Transversus Abdominis Plane (TAP) block is accepted as another constituent of multimodal analgesia.<sup>3,4</sup> Use of opioids, a traditional mode of treatment for pain management, is restricted by nausea, vomiting, constipation, urinary retention, sedation and resulting respiratory depression.<sup>3</sup> Thoracic epidural analgesia for postoperative pain has been found to be more effective than patient controlled intravenous analgesia,

however epidural anesthesia is associated with risks of dural puncture, high level epidural block, epidural hematoma, and epidural infection.<sup>5</sup> Precaution should also be taken with NSAID use due to possible side effects in elderly patients, patients with renal, cardiac, hematopoietic and liver failure, and in patients with positive history of gastrointestinal bleeding.<sup>6</sup>

Currently transversus abdominis plane block is used for the management of pain in the postoperative period after various surgical procedures, namely open/laparoscopic appendectomy, cesarean section, total abdominal hysterectomy, laparoscopic cholecystectomy, open prostatectomy, renal transplantation, and abdominoplasty among others.<sup>1,4,7-9</sup> Hebbard et al. later described ultrasound guided TAP block in 2007.<sup>10</sup> The use of ultrasound imaging allows correct localization of injection site and visualization of local anesthetic distribution, thereby leading to increased success and reduced complication rate.<sup>10</sup> A considerable amount of studies show TAP block to be a good



**Figure 1** Ultrasound image of local anesthetic injection. (A) Before injection and (B) after injection.

choice of postoperative analgesia in laparoscopic cholecystectomy cases.<sup>1,7,8,11</sup> Its use with different local anesthetics are already published.<sup>7,8,11–16</sup> However no studies have been published comparing bupivacaine and levobupivacaine for TAP block. Therefore in our study we aimed to compare postoperative analgesic efficacies of bupivacaine and levobupivacaine in ultrasound guided TAP block in conventional four-port laparoscopic cholecystectomy cases.

## Materials and method

After approval of Fatih Sultan Mehmet Research and Training Hospital Ethical Board (reg. n° 2013/53) and with patients' informed consents, 52 ASA I and ASA II patients scheduled for elective laparoscopic cholecystectomy after diagnosis of symptomatic cholelithiasis were included in this double-blind study. By an anesthetist who was not involved in the study, the patients were randomly allocated into two groups with sealed envelope system. Exclusion criteria were body mass index  $>35 \text{ kg}\cdot\text{m}^{-2}$ , known allergy to study drugs, chronic hepatic or renal failure, and preoperative opioid or nonsteroidal anti-inflammatory drug treatment for chronic pain. If the laparoscopic surgery was switched to open procedure, the patient was excluded from the study.

The patients were not premedicated. Inside the operating room patients were monitored with electrocardiogram, non-invasive blood pressure and peripheral oxygen saturation ( $\text{SpO}_2$ ) measurements. Heart Rate (HR) and Mean Arterial Pressure (MAP) levels were recorded at 15 min intervals, as well as operative times.  $\text{NaCl } 0.9\%$  infusion at rate of  $7 \text{ mL}\cdot\text{kg}^{-1}\cdot\text{h}^{-1}$  was administered throughout the operation. Anesthesia induction was carried out with propofol  $2\text{--}2.5 \text{ mg}\cdot\text{kg}^{-1}$ , fentanyl  $1 \mu\text{g}\cdot\text{kg}^{-1}$ , rocuronium  $0.6 \text{ mg}\cdot\text{kg}^{-1}$ , followed by sevoflurane 1–2% and remifentanyl

$0.025\text{--}0.75 \mu\text{g}\cdot\text{kg}^{-1}\cdot\text{min}^{-1}$  for maintenance. In all the patients, four-port laparoscopic cholecystectomy was performed by the same surgeon.

Following anesthesia induction and before initiation of surgery, all of the fifty-two patients were imaged with bilateral linear ultrasound probes (Famio 8; Toshiba, Ootawarashi, Japan) placed transverse on the midaxillary line between the iliac crest and the costal margin. External oblique, internal oblique, and transversus abdominis muscles were detected (Fig. 1A). 10 cm Braun (21 gauge, 100 mm, Melsungen, Germany) needle was inserted from the anterior with in-plane approach. After confirming needle localization with 2 mL of  $\text{NaCl } 0.9\%$ , Group B ( $n=26$ ) patients received 30 mL of bupivacaine 0.25%, and Group L ( $n=26$ ) patients received 30 mL of levobupivacaine 0.25% on each side (Fig. 1B). The local anesthetics were administered by an anesthesiologist without knowledge of injected drug for TAP block. Paracetamol 1 g was given intravenously just before the end of the operation. All patients were preoperatively educated on the 10 cm Visual Analog Scale (VAS) (0: no pain, 10: worst imaginable pain). 1, 5, 15, 30 minutes and 1, 4, 6, 12, and 24 h after the operation hemodynamic recordings (HR, MAP) were made and intensity of pain at rest and during coughing were evaluated with VAS. If VAS level was higher than 3 in the postoperative period, 20 mg of tenoxicam was given intravenously. If VAS score remained above 3 regardless,  $1 \text{ mg}\cdot\text{kg}^{-1}$  of intravenous tramadol was added. In cases where VAS level still remained above 3, rescue analgesics were administered.

Time to first analgesic (tenoxicam) requirement, time to first tramadol requirement, need for rescue analgesia, level of postoperative nausea (none, mild, moderate, severe, very severe), presence of vomiting, and patient satisfaction levels (5: very satisfied, 4: satisfied, 3: uncertain,

2: unsatisfied, 1: very unsatisfied) were recorded. Possible complications of TAP block, such as vertigo after IV injection, tinnitus, perioral numbness, lethargy, seizures, peritoneal perforation or intestinal perforation were tracked. The anesthesiologist recording postoperative data as well as the patients themselves had no knowledge about the group allocation.

### Power analysis

With a power of 90% and alpha error of 5%, for a 1.5 cm difference in VAS score at rest, the sample size calculation determined that 24 patients were required for each group. The total number of patients required for the study was determined to be 50. Data were analyzed using the Number Cruncher Statistical System (NCSS) 2007 & Power Analysis and Sample Size (PASS) 2008 Statistical Software (Utah, USA). Convenience of parameters to the normal distribution was assessed with Shapiro Wilks test while assessing the study data. Student *t* test was used in comparing quantitative data, for comparing parameters that showed normal distribution between the two groups, while Mann Whitney *U* test was used comparing data that did not show a normal distribution between the two groups. For within group comparison, paired sample *t*-test was used in comparing parameters that showed normal distribution, and Wilcoxon signed-rank test was used in comparing parameters that did not show normal distribution. Chi-square test and Continuity (Yates) correction were used in comparing qualitative parameters.  $p \leq 0.05$  was considered statistically significant.

### Results

A total of 52 patients were included in the study. Two patients (one for each group) were excluded from the study because of switch to open surgery. Forty-four (88%) female, 6 (12%) male patients, with ASA I ( $n = 25$ ) and ASA II ( $n = 25$ ) scores were included in the study from September 2013 to July 2014. Groups were similar for age, BMI, operative times, gender and ASA distributions (Table 1).

VAS levels at rest at postoperative minute 1 and 5 were higher in Group L ( $p = 0.049$ ) (Fig. 2A). VAS levels during coughing at 1 min was higher in Group L ( $p = 0.048$ ) (Fig. 2B).

Time to first analgesia (tenoxicam) requirement and time to first tramadol requirement were shorter in Group L compared to Group B ( $p < 0.05$ ). Rescue analgesic requirement did not show difference between groups (Table 2).

Postoperative nausea level, vomiting rate and patient satisfaction were similar in both groups (Table 3). No patients experienced complication due to TAP block. Heart rate was similar between groups, and MAP recordings at postoperative 30 min was higher in Group B ( $p = 0.036$ ).

### Discussion

In our study we compared postoperative analgesic efficacy of bupivacaine and levobupivacaine in patients receiving ultrasound guided TAP block after general anesthesia induction in laparoscopic cholecystectomy. Group B ( $n = 25$ ) received 30 mL of bupivacaine 0.25% and Group L ( $n = 25$ ) received 30 mL of levobupivacaine 0.25% bilaterally. We found the analgesic efficacy of the two agents to be similar.

Chronic pain follows 10–60% of cases after various surgical procedures such as thoracotomy, mastectomy, amputation, inguinal hernia repair, and cholecystectomy.<sup>17</sup> The risk of chronic postoperative pain has been reported to be 10–40% after laparoscopic or traditional open cholecystectomy.<sup>17,18</sup> Preoperative pain, nerve damage during surgery, insufficient early postoperative pain management are among the risk factors for chronic pain after surgery.<sup>17,19–21</sup> Bisgaard et al.,<sup>18</sup> in their prospective study with 150 patients undergoing laparoscopic cholecystectomy followed up for 1 year, found that the risk of significant chronic pain is associated with the intensity of acute postoperative pain.<sup>18</sup>

Despite laparoscopic cholecystectomy being a minimally invasive procedure, management of postoperative pain remains important. TAP block has been frequently used in the recent years as a constituent of multimodal analgesia in the postoperative period.<sup>3</sup> TAP block with ultrasound guidance is also increasing in popularity.<sup>1,7–9</sup> TAP block provides analgesic effect up to 24 h after laparoscopic surgeries.<sup>1</sup>

El Dawlatly et al.<sup>7</sup> in their study on laparoscopic cholecystectomy cases found less requirement of preoperative sufentanil and morphine within 24 hours of surgery in the group receiving a total of 30 mL of 5 mg.mL<sup>-1</sup> of bupivacaine bilaterally with ultrasound guidance compared to

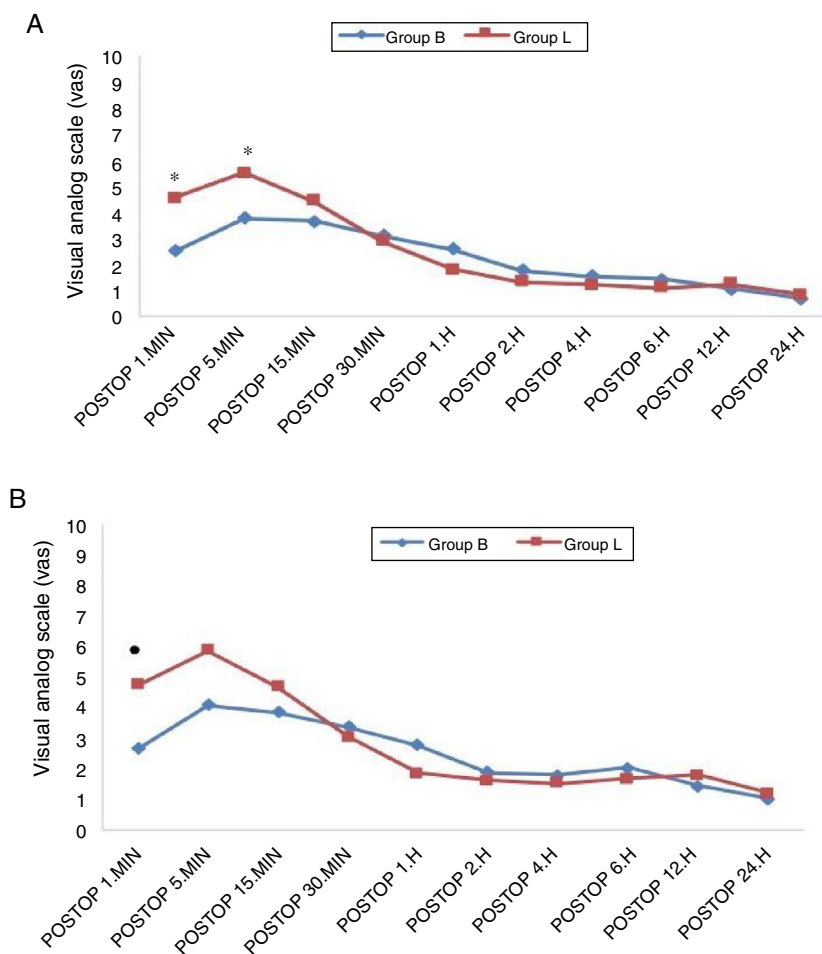
**Table 1** Demographic data, operative times and ASA distributions.

		Group B ( $n = 25$ )	Group L ( $n = 25$ )	<i>p</i>
Age (years) Mean $\pm$ SD		45.68 $\pm$ 13.38	48.8 $\pm$ 11.64	0.384 <sup>a</sup>
BMI (Kg.m <sup>-2</sup> ) Mean $\pm$ SD		31.43 $\pm$ 5.58	29.03 $\pm$ 4.80	0.109 <sup>a</sup>
Sex <i>n</i> (%)	Female	23(92)	21(84)	0.667 <sup>c</sup>
	Male	2(8)	4(16)	
ASA ( <i>n</i> )	1	13	12	1.0 <sup>c</sup>
	2	12	13	
Operative time (min) Mean $\pm$ SD	51.53 $\pm$ 20.45		52.08 $\pm$ 16.81	0.661 <sup>b</sup>

<sup>a</sup> Student-*t* test.

<sup>b</sup> Mann Whitney *U* test.

<sup>c</sup> Fischer's exact test.



**Figure 2** Comparison of groups for VAS levels. (A) At rest and (B) during coughing; \* $p=0.049$ ; ● $p=0.048$ .

**Table 2** Comparison of groups for time to first analgesia requirement, time to first tramadol requirement and rescue analgesia requirement.

	Bupivacaine		Levobupivacaine		$p^a$
	N	Mean $\pm$ SD	N	Mean $\pm$ SD	
Time to first analgesia (min) (Tenoxicam)	18	34.91 $\pm$ 86.26	20	4.35 $\pm$ 6.92	0.013 <sup>c</sup>
Time to first tramadol (min)	14	35.36 $\pm$ 60.65	16	10.94 $\pm$ 7.12	0.034 <sup>c</sup>
Rescue analgesia Requirement	Yes	7	5		0.742 <sup>b</sup>
	No	18	20		

<sup>a</sup> Mann Whitney *U* test.  
<sup>b</sup> Fischer's exact test.  
<sup>c</sup>  $p < 0.05$ .

control group. However, in their study, all trocar sites in the laparoscopic procedures are below the umbilicus, and pain scores are not evaluated. Ra et al.<sup>8</sup> compared TAP block with two different concentrations (0.25 and 0.5%) of total 30 mL levobupivacaine and a control group. They investigated intraoperative remifentanyl use with target controlled infusion. Postoperative verbal numerical rating scale (VNRS) levels and supplemental analgesia requirements were found to be lower in both levobupivacaine groups than in the control group, with no difference between the two TAP block

groups.<sup>8</sup> Providing same analgesic efficacy at lower local anesthetic concentrations is important for prevention of local anesthetic toxicity.

Koch et al.<sup>22</sup> found equivalent postoperative analgesic profiles for levobupivacaine 0.5% and bupivacaine 0.5% in a multicenter study on epidural anesthesia for hip replacement surgery. Cox et al.,<sup>23</sup> in this study on elective hand surgery, compared 0.25% and 0.5% concentrations of S(-) bupivacaine and RS-bupivacaine 0.5%, and found no difference in onset time, dermatomal spread, and motor and

**Table 3** Comparison of groups for postoperative nausea, vomiting and patient satisfaction.

		Bupivacaine n (%)	Levobupivacaine n (%)	p <sup>a</sup>
Nausea	None	12 (48)	11 (44)	0.485 <sup>a</sup>
	Mild	6 (24)	7 (28)	
	Moderate	3 (12)	6 (24)	
	Severe	2 (8)	1 (4)	
	Very Severe	2 (9)	0 (0)	
Vomiting	No	20 (80)	21 (84)	1.000 <sup>b</sup>
	Yes	5 (20)	4 (16)	
Patient satisfaction	Uncertain	1 (4)	2 (8)	0.760 <sup>b</sup>
	Satisfied	4 (16)	5 (20)	
	Very satisfied	20 (80)	18 (72)	

<sup>a</sup> Chi-square.

<sup>b</sup> Fisher's exact test.

sensory block durations among the three groups. In our study we compared 0.25% concentrations of levobupivacaine and bupivacaine.

Different volumes of local anesthetics are used for TAP block. Most appropriate volume is yet to be determined.<sup>24</sup> We used a total of 60 mL of local anesthetic as TAP block is a space block and the volume of anesthetic is significant for block efficacy. At 0.25% concentration, we encountered no local anesthetic toxicity in our study with levobupivacaine and bupivacaine.

There are various causes for pain after laparoscopic cholecystectomy: visceral pain due to resection of the gallbladder, abdominal wall pain due to gas insufflation, and pain at trocar site incisions. Despite all these known reasons, the primary reason for is not evident.<sup>6</sup> Ortiz et al.<sup>13</sup> compared TAP block with local infiltration at trocar site, not finding TAP block to be superior for postoperative analgesia. The authors applied a total of 30 mL of ropivacaine 0.5%. We consider the total volume of 30 mL may have been insufficient although a 0.5% concentration of ropivacaine was used. Kadam et al.<sup>14</sup> compared local infiltration to trocar site with 20 mL of bupivacaine 0.25% and subcostal TAP block with total 40 mL of ropivacaine 0.5% in their retrospective study, finding no difference among groups regarding postoperative pain scores. However, in the TAP block group, fentanyl use in the recovery room was significantly lower. Bava et al.<sup>11</sup> compared ultrasound guided TAP block with total 30 mL of ropivacaine 0.375% and local infiltration with 10 mL of bupivacaine 0.25% prior to incision for their effect on perioperative analgesia in single-incision laparoscopic cholecystectomy, finding significantly higher VAS levels at rest and during coughing, as well as intraoperative additional fentanyl requirement, in the local infiltration group.

Most frequent side effect of opioid use is nausea and vomiting. TAP block, in addition to lowering postoperative pain scores, also decreases need for and risk of possible side effects of opioid use.<sup>11,14,24</sup> Our study had similar postoperative nausea levels, vomiting rates, and patient satisfaction levels.

As in numerous other studies that evaluated postoperative pain after laparoscopic cholecystectomy, we used VAS score that is prone to subjective results.<sup>15,16</sup> We recorded higher early postoperative resting and coughing VAS scores in the levobupivacaine group. As patients may be in a confused

mental state in the early postoperative period, VAS recordings may be unreliable.<sup>6</sup> As we found higher VAS scores in the early postoperative period, consequentially time to first analgesia and time to tramadol requirement were shorter in the levobupivacaine group. Although this is the first comparing analgesic efficacies of bupivacaine and levobupivacaine for TAP block in laparoscopic cholecystectomy, our study has some limitations. We have not evaluated intraoperative remifentanyl use, sensory block distribution and drug concentrations in the blood. Another limitation is the lack of pneumoperitoneal insufflation pressure recordings. There is some evidence that maintaining low inflation pressures during laparoscopic surgery may reduce postoperative pain.<sup>25</sup>

Although it has been hypothesized that deep neuromuscular block when compared with moderate block would allow for the use of lower inflation pressures, there is little or no evidence to suggest that using deep block for laparoscopic surgery will improve operating condition and patient outcome.<sup>25</sup>

## Conclusion

We found postoperative analgesic efficacies of ultrasound guided TAP block with bupivacaine 0.25% and levobupivacaine 0.25% in patients undergoing laparoscopic cholecystectomy to be similar. Results of our study need to be supported by further studies with larger patient groups.

## Conflicts of interest

The authors declare no conflicts of interest.

## References

- Petersen PL, Stjernholm P, Kristiansen VB, et al. The beneficial effect of transversus abdominis plane block after laparoscopic cholecystectomy in day-case surgery: a randomized clinical trial. *Anesth Analg.* 2012;115:527–33.
- Dabbagh AA. Pain after laparoscopic cholecystectomy. *Zanco J Med Sci.* 2009;13:37–42.
- Mitra S, Khandelwal P, Roberts K, et al. Pain relief in laparoscopic cholecystectomy – a review of the current options. *Pain Pract.* 2012;12:485–96.

4. De Oliveira GS, Fitzgerald PC, Marcus RJ, et al. A dose-ranging study of the effect of transversus abdominis block on postoperative quality of recovery and analgesia after outpatient laparoscopy. *Anesth Analg*. 2011;113:1218–25.
5. Katircioğlu K, Hasegeli L, Ibrahimhakkioglu HF, et al. A retrospective review of 34,109 epidural anesthetics for obstetric and gynecologic procedures at a single private hospital in Turkey. *Anesth Analg*. 2008;107:1742–5.
6. Wills VL, Hunt DR. Pain after laparoscopic cholecystectomy. *Br J Surg*. 2000;87:273–84.
7. El-Dawlatly AA, Turkistani A, Kettner SC, et al. Ultrasound-guided transversus abdominis plane block: description of a new technique and comparison with conventional systemic analgesia during laparoscopic cholecystectomy. *Br J Anaesth*. 2009;102:763–7.
8. Ra YS, Kim CH, Lee GY, et al. The analgesic effect of the ultrasound-guided transverse abdominis plane block after laparoscopic cholecystectomy. *Korean J Anesthesiol*. 2010;58:362–8.
9. Finnerty O, McDonnell JG. Transversus abdominis plane block. *Curr Opin Anesthesiol*. 2012;25:610–4.
10. Hebbard P, Fujiwara Y, Shibata Y, et al. Ultrasound guided transversus abdominis plane (TAP) block. *Anaesth Intensive Care*. 2007;35:616–8.
11. Bava EP, Ramachandran R, Rewari V, et al. Analgesic efficacy of ultrasound guided transversus abdominis plane block versus local anesthetic infiltration in adult patients undergoing single incision laparoscopic cholecystectomy: a randomized controlled trial. *Anesth Essays Res*. 2016;10:561–7.
12. Sinha S, Palta S, Saroa R, et al. Comparison of ultrasound-guided transversus abdominis plane block with bupivacaine and ropivacaine as adjuncts for postoperative analgesia in laparoscopic cholecystectomies. *Indian J Anaesth*. 2016;60:264–9.
13. Ortiz J, Suliburk JW, Wu K, et al. Bilateral transversus abdominis plane block does not decrease postoperative pain after laparoscopic cholecystectomy when compared with local anesthetic infiltration of trocar insertion sites. *Reg Anesth Pain Med*. 2012;37:188–92.
14. Kadam VR, Hower S, Kadam V. Evaluation of postoperative pain scores following ultrasound guided transversus abdominis plane block versus local infiltration following day surgery laparoscopic cholecystectomy – retrospective study. *J Anaesthesiol Clin Pharmacol*. 2016;32:80–3.
15. Bhatia N, Arora S, Wig J, et al. Comparison of posterior and subcostal approaches to ultrasound-guided transversus abdominis plane block for postoperative analgesia in laparoscopic cholecystectomy. *J Clin Anesth*. 2014;26:294–9.
16. Oksar M, Koyuncu O, Turhanoglu S, et al. Transversus abdominis plane block as a component of multimodal analgesia for laparoscopic cholecystectomy. *J Clin Anesth*. 2016;34:72–8.
17. Perkins FM, Kehlet H. Chronic pain as an outcome of surgery: a review of predictive factors. *Anesthesiology*. 2000;93:1123–33.
18. Bisgaard T, Rosenberg J, Kehlet H. From acute to chronic pain after laparoscopic cholecystectomy: a prospective follow-up analysis. *Scand J Gastroenterol*. 2005;40:1358–64.
19. Alfieri S, Amid PK, Campanelli G, et al. International guidelines for prevention and management of post-operative chronic pain following inguinal hernia surgery. *Hernia*. 2011:239–49.
20. Bay-Nielsen M, Perkins FM, Kehlet H. Pain and functional impairment 1-year after inguinal herniorrhaphy: a nationwide questionnaire study. *Ann Surg*. 2001;233:1–7.
21. Poobalan AS, Bruce J, Cairns W, et al. A review of chronic pain after inguinal herniorrhaphy. *Clin J Pain*. 2003;19:48–54.
22. Koch T, Fichtner A, Schwemmer U, et al. Levobupivacaine for epidural anaesthesia and postoperative analgesia in hip surgery. *Anaesthesist*. 2008;57:475–82.
23. Cox CR, Checketts MR, Mackenzie N, et al. Comparison of S(-)-bupivacaine with racemic (RS)-bupivacaine in supraclavicular brachial plexus block. *Br J Anaesth*. 1998;80:594–8.
24. Peng K, Ji F, Liu H, et al. Ultrasound-guided transversus abdominis plane block for analgesia in laparoscopic cholecystectomy: a systematic review and meta-analysis. *Med Princ Pract*. 2016;25:237–46.
25. Kopman AF, Naguib M. Laparoscopic surgery and muscle relaxants: is deep block helpful? *Anesth Analg*. 2015;120:51–8.