



REVISTA BRASILEIRA DE ANESTESIOLOGIA

Publicação Oficial da Sociedade Brasileira de Anestesiologia
www.sba.com.br



CLINICAL INFORMATION

Bilateral mandibular nerve injury following mask ventilation: a case report



Bahattin Tuncali^{a,*}, Pinar Zeyneloglu^b

^a Baskent University Zubeyde Hanım Practice and Research Center, Department of Anesthesiology, Izmir, Turkey

^b Baskent University, Faculty of Medicine, Department of Anesthesiology, Ankara, Turkey

Received 16 February 2017; accepted 28 December 2017

Available online 1 February 2018

KEYWORDS

Mandibular nerve injury;
Mask ventilation;
Anesthesia

Abstract

Background and objectives: Nerve injury following mask ventilation is a rare but serious anesthetic complication. The majority of reported cases are associated with excessive pressure applied to the face mask, long duration of mask ventilation, excessive digital pressure behind the mandible to relieve airway obstruction and pressure exerted by the plastic oropharyngeal airway.

Case report: We present a case of bilateral mandibular nerve injury following mask ventilation with short duration, most likely due to a semi-silicone facemask with an over-inflated cushion.

Conclusion: An over-inflated sealing cushion of a facemask may trigger difficult mask ventilation leading to mandibular nerve injury following mask ventilation. Alternative airway management techniques such as laryngeal mask airway should be considered when airway maintenance can only be achieved with strong pressure applied to the facemask and/or mandible.

© 2018 Sociedade Brasileira de Anestesiologia. Published by Elsevier Editora Ltda. This is an open access article under the CC BY-NC-ND license (<http://creativecommons.org/licenses/by-nc-nd/4.0/>).

PALAVRAS-CHAVE

Lesão do nervo mandibular;
Ventilação com máscara;
Anestesia

Lesão do nervo mandibular bilateral após ventilação com máscara: um relato de caso

Resumo

Justificativa e objetivos: A lesão nervosa após ventilação com máscara é uma complicação anestésica rara, mas grave. A maioria dos casos relatados está associada à pressão excessiva aplicada à máscara facial, ao tempo prolongado de ventilação, à pressão digital excessiva atrás da mandíbula para aliviar a obstrução das vias aéreas e à pressão exercida pela cânula orofaríngea.

* Corresponding author.

E-mail: tuncali.bahattin@gmail.com (B. Tuncali).

Relato de caso: Apresentamos um caso de lesão do nervo mandibular bilateral após uma ventilação de curta duração via máscara, provavelmente devido ao uso de uma máscara facial (de semissilicone) com insuflação excessiva da almofada.

Conclusão: A insuflação excessiva da almofada de uma máscara facial pode desencadear uma ventilação com máscara difícil, levando à lesão do nervo mandibular após a ventilação. Técnicas alternativas de manejo das vias aéreas, como o uso de máscara laríngea, devem ser consideradas quando a manutenção das vias aéreas só pode ser obtida com forte pressão aplicada à máscara facial e/ou mandíbula.

© 2018 Sociedade Brasileira de Anestesiologia. Publicado por Elsevier Editora Ltda. Este é um artigo Open Access sob uma licença CC BY-NC-ND (<http://creativecommons.org/licenses/by-nc-nd/4.0/>).

Introduction

Injury of nerves which innervate lower facial region following mask ventilation is a rare anesthetic complication. The majority of cases reported have been associated with excessive pressure applied to the face mask, long duration of mask ventilation, excessive digital pressure behind the mandible to relieve airway obstruction and pressure exerted by the plastic oropharyngeal airway.¹⁻⁹ However, there is little knowledge about the relationship between nerve injury and the type of the facemask or the amount of air in its cushion.

We present a case of bilateral mandibular nerve injury following difficult mask ventilation most likely due to a semi-silicone facemask with an over-inflated cushion. Written consent for publication of this report was obtained from the patient.

Case description

A 51 years old woman underwent an endometrial biopsy under general anesthesia. She had no prior history of the medical problem. Anesthesia was induced with midazolam 1 mg, fentanyl 100 µg and propofol 150 mg and maintained with sevoflurane in nitrous oxide-oxygen administered by the face mask. Jaw thrust and tight facemask (size 4) seal using digital pressure with both hands were required for adequate mask ventilation. A Guedel airway was also inserted. The surgical procedure lasted 9 min and the patient was ventilated for 14 min. She was then transferred to the recovery room and discharged home the same day. Five hours after the procedure, the patient presented to the anesthetic department complaining of numbness at both sides of her chin and lower lip. She described her sensations as similar to the numb feeling after dental treatment under local anesthesia. Clinical assessment showed bilateral parotid tenderness and loss of temperature and touch perception at both sides of her chin and lower lip. There was no motor deficit. Neurological evaluation performed by a neurologist revealed that the area of numbness corresponded to the area of innervation of the mandibular divisions of the right and left trigeminal nerves (Fig. 1A). Treatment with a non-steroid anti-inflammatory agent and vitamin B was started.

Follow-up of the patient revealed that bilateral parotid tenderness and the numbness at the left side of her face were improved gradually and recovered completely in 1 week (Fig. 1B). The numbness at the right side of her face was also regressed gradually from her chin to a small area under the right side of her lower lip after 3 weeks (Fig. 1C). Complete remission occurred within 5 weeks.

Discussion

Sensory and/or motor nerve dysfunction of the mental nerve, inferior alveolar nerve, mandibular division of trigeminal nerve and facial nerve following mask ventilation have been reported with several case reports since 1950s.¹ Reported cases of nerve injuries associated with mask ventilation under general anesthesia are presented in Table 1. The majority of cases were associated with long duration of mask ventilation and/or difficult mask ventilation.²⁻⁷ However, cases with easy ventilation and short duration were also reported.^{1,8,9} Although digital pressure is frequently applied to the facemask and/or the mandible to relieve airway obstruction during mask ventilation in anesthesia practice, the reported cases of nerve injury are infrequent. Possible explanations may be individual differences, anatomical variations or hereditary predisposition. Moreover, there may be many unreported cases.

Difficult mask ventilation is described as the clinical situation that develops when it is not possible for the anesthesiologist to provide adequate mask ventilation due to inadequate mask seal, excessive gas leak or excessive resistance to the ingress or egress of gas.¹⁰ Additionally, technical problems, inadequate depth of anesthesia, patient and equipment related factors, separately or combined, may lead to difficult mask ventilation.¹⁰ Several authors reported the incidence of difficult mask ventilation between 1.4% and 5% and found various risk factors such as male gender, age older than 55 year, body mass index more than 26 kg.m⁻², lack of teeth, history of snoring, presence of a beard, Mallampati Class III or IV and limited mandibular protrusion test.¹¹ Although none of the risk factors were present in our patient, mask ventilation was

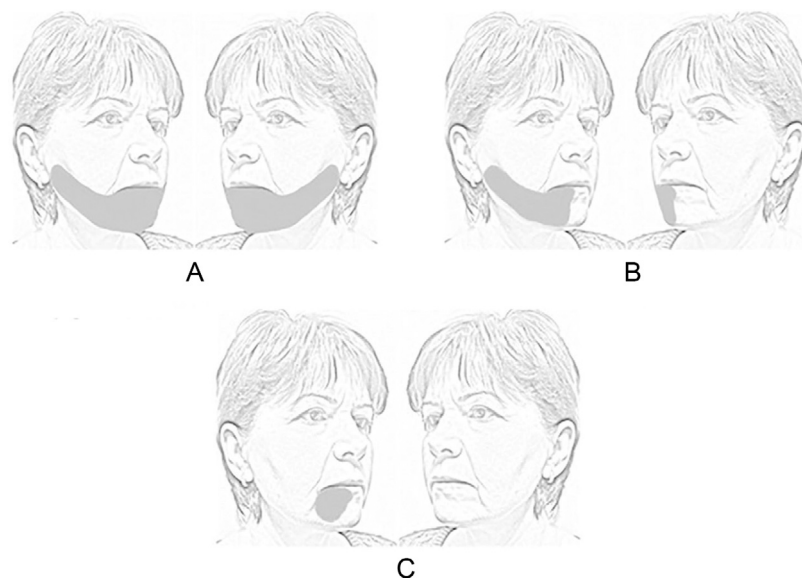


Figure 1 (A) Five hours after the procedure, numbness at both sides of her chin and lower lip. (B) One week after the procedure, numbness at the left side of her face was improved gradually and recovered completely. (C) Three weeks after the procedure, numbness at the right side of her face was regressed gradually from her chin to a small area under the right side of her lower lip.

difficult requiring chin lift and jaw thrust maneuvers and two-person.

The type, size and design of the mask can affect the effectiveness of ventilation.¹² Bhuiyan et al.,⁶ pointed out that, when a difficult airway is encountered, a lot of pressure is needed to get a good seal around the face with a semi silicone face mask than with the traditional black rubber facemask. Therefore, following readmission of the patient we checked the facemask we used. In our case, we used a transparent, disposable, semi-silicone facemask with an inflating valve and cushion rim which is commonly used in anesthesia practice. Moreover, we found that the wall of its cushion was over-stretched due to over-inflation with 150 mL of air volume. The type of the facemask we used and/or the excessive volume of air in its cushion might have partly contributed to this complication. Ensuring proper inflation of the sealing cushion is important in providing an effective seal and reducing the risk of inadvertent pressure over the face. If the cushion is over-inflated, pressure is concentrated to a smaller contact area over the face, leading to difficulty in maintaining the seal, requiring higher digital pressures to the mask and/or jaw-thrust maneuver by bilateral digital pressure behind the mandible. Moreover, these higher pressures may lead to compression and injury of nerves which innervate the lower facial region.¹³ The potential mechanisms of injury in our patient were the combined effects of excessive direct pressure by the rim of the facemask against the mandible and the stretching forces caused by strong forward traction during jaw-thrust maneuver due to difficult mask ventilation triggered by the semi-silicone facemask with an over-inflated cushion.

Nerve injuries may be apparent immediately after recovery from anesthesia or may occur 1–2 days later.^{1–9}

Rapid onset is more likely to be direct nerve injury. Various mechanisms included mechanical compression or stretching the nerve, ischemia, needle trauma or injection of a neurotoxic material have been proposed. Other predisposing factors include hypothermia, hypovolemia, dehydration, hypotension, hypoxia electrolyte disturbances and anatomic variations.¹⁴ Clinical presentation includes anesthesia, hypoesthesia, paresthesia and pain in the areas supplied by the affected nerves. There may also be paresis or paralysis of affected muscles. Fortunately, the majority of cases are self-limited with a full and spontaneous recovery over 10 days and 3 months to resolve.^{1–9} In our patient, bilateral numbness distributed to the area of innervation of the mandibular divisions of the trigeminal nerves began at the postoperative 5th hour and gradually resolved. Considering the nerve anatomy, it appears likely that the neural damage was caused by extensive jaw thrust due to difficult mask ventilation. Complete remission occurred over 5 weeks. Despite the complete resolution, the complication reported here was extremely dissatisfying to the patient.

In conclusion, nerve injury following mask ventilation is multifactorial in origin. An over-inflated sealing cushion of a facemask may trigger difficult mask ventilation requiring excessive digital pressure to the mask, jaw-thrust maneuver or oropharyngeal airway use. Although nerve injuries typically completely resolve within a few weeks to several months, the loss of sensation may lead to thermal injury or self-induced trauma to the affected areas. Therefore, patients should be alerted to avoid injuries to the lip and mouth until any such numbness resolves. Lastly, alternative airway management techniques such as laryngeal mask airway should be considered when airway maintenance can only be achieved with strong pressure applied to the facemask and/or mandible.

Table 1 Reported cases of nerve injuries associated with mask ventilation under general anesthesia.

Author	Patient	Age	Sex	Surgical procedure	Difficult MV	Duration of MV (min)	Nerve injury	Possible cause	Onset of symptoms	Full recovery
Fuller et al. ¹ (1956)	1	54	F	Cholecystectomy	(+)	30 min	Facial nerve	Direct pressure on the mask and strong forward traction of the mandible	After recovery period 24 h	After 3 months
	2	53	M	Inguinal hernia repair	(+)	10 min				
Azaar et al. ² (1986)	3	44	F	Dilatation and curettage	(-)	30 min	Mental nerve	Excessive pressure of the mask and airway on the mental and inferior alveolar nerves respectively	24 h	Within 5 weeks
	4	47	F	Incision of breast mass	(-)	45 min				
Glauber ³ (1986)	5	54	M	Arthroscopic menisectomy of the knee	(+)	75 min	Facial nerve	Lifting the jaw forward by bilateral digital pressure	24 h	Over 5 weeks
Gimmon ⁴ (1988)	6	35	F	Right hemicolecotomy	(-)	?	Mental nerve	Compression by the extraoral part of the tracheal tube and traction by it's fixation technique	24 h	Over 5 weeks
Ananthanaryan et al. ⁵ (1988)	7	19	M	Circumcision	(-)	?	Facial nerve	Direct pressure by mask on the nerves, pressure behind the mandible to relieve airway obstruction, oral airway, anatomical variations	?	After 10 days
	8	48	F	Breast biopsy	(-)	45 min			24 h	Within 4 weeks
	9	58	M	Cystoscopy and hydrocelectomy	(-)	?			48 h	Within 3 months
Lorentz et al. ⁸ (1988)	10	40	F	Derotation osteotomy of femur	(+)	5-6 min	Mental nerve	Considerable pressure exerted on the mask	24 h	Within 6 weeks
Bhuiyan et al. ⁶ (2006)	12	43	F	Excision of Mortons' neuroma	(+)	30 min	Mental nerve	Excessive pressure of the mask on the lower lip against mandible	24 h	Within 3 weeks
Richa et al. ⁷ (2008)	11	31	F	Gynecologic laparoscopy	(-)	45 min	Mental nerve	Pressure applied by the airway on the mental branch of the inferior alveolar nerve	24 h	Within 2 weeks
Baidya et al. ⁹ (2011)	13	62	F	Laporoscopic hysterectomy and cholecystectomy	(+)	3 min	Mental, buccal nerves	Forward digital pressure at the right angle of the jaw	24 h	After 6 weeks

MV, mask ventilation.

Conflicts of interest

The authors declare no conflicts of interest.

References

1. Fuller JE, Thomas DV. Facial nerve paralysis after general anesthesia. *J Am Med Assoc.* 1956;162:645.
2. Azar I, Lear E. Lower lip numbness following general anesthesia. *Anesthesiology.* 1986;65:450–1.
3. Glauber DT. Facial paralysis after general anesthesia. *Anesthesiology.* 1986;65:516–7.
4. Gimmon Z. Neuropraxia of the mental nerve. *Anaesthesia.* 1988;43:613.
5. Ananthanarayan C, Rolbin SH, Hew E. Facial nerve paralysis following mask anaesthesia. *Can J Anaesth.* 1988;35:102–3.
6. Bhuiyan MS, Chapman M. Mental nerve injury following face-mask anaesthesia. *Anaesthesia.* 2006;61:516–7.
7. Richa F, Yazigi A, Yazbeck P. Mental nerve injury following general anaesthesia. *Eur J Anaesthesiol.* 2008;25:951.
8. Lorentz A, Podstawski H, Osswald PM. Numbness of the lower lip following general anesthesia. *Anaesthesist.* 1988;37:381–3.
9. Baidya DK, Bhoi D, Sinha R, et al. Partial facial nerve paralysis after laparoscopic surgery under general anaesthesia. *Indian J Anaesth.* 2011;55:416–8.
10. Practice guidelines for management of the difficult airway: an updated report by the American Society of Anesthesiologists Task Force on Management of the Difficult Airway. *Anesthesiology.* 2003;98:1269–77.
11. Kheterpal S, Han R, Tremper KK, et al. Incidence and predictors of difficult and impossible mask ventilation. *Anesthesiology.* 2006;105:885–91.
12. El-Orbany M, Woehlck HJ. Difficult mask ventilation. *Anesth Analg.* 2009;109:1870–80.
13. Munckton K, Ho KM, Dobb GJ, et al. The pressure effects of facemasks during noninvasive ventilation: a volunteer study. *Anaesthesia.* 2007;62:1126–31.
14. Sawyer RJ, Richmond MN, Hickey JD, et al. Peripheral nerve injuries associated with anaesthesia. *Anaesthesia.* 2000;55:980–91.