



REVISTA BRASILEIRA DE ANESTESIOLOGIA

Publicação Oficial da Sociedade Brasileira de Anestesiologia
www.sba.com.br



CLINICAL INFORMATION

Determination of residual mass in left ventricle by intraoperative transesophageal echocardiography after a giant and floating left atrial myxoma resection



Ali Sait Kavakli*, Nilgun Kavrut Ozturk

Antalya Training and Research Hospital, Department of Anesthesiology and Reanimation, Antalya, Turkey

Received 6 March 2017; accepted 3 October 2017

Available online 9 November 2017

KEYWORDS

Giant cardiac tumor;
Left atrial myxoma;
Surgical resection;
Residual mass;
Transesophageal
echocardiography

Abstract Atrial myxoma is a benign tumor of the heart that occurs primarily in the left atrium. Floating or large left atrial myxomas frequently cause functional mitral stenosis, may also affect mitral valve structure and flow, and lead to mitral regurgitation. Systemic embolization occurs in around 30% of cases either from tumor fragmentation or complete tumor detachment hence it should be removed as soon as it is detected. Intraoperative transesophageal echocardiography has a vital importance in the surgery. After resection of myxoma, intraoperative transesophageal echocardiography must be performed to rule out residual mass. The case here reported is of a 48-year old female, who presented with giant and floating left atrial myxoma. Residue mass was detected with intraoperative transesophageal echocardiography in the left ventricle after the resection of myxoma. Subsequently, the residue mass was successfully removed. Complete resection must be required to prevent possible complications such as recurrence, embolization in atrial myxomas. Transesophageal echocardiography performed intraoperatively is vital importance to confirm that the myxoma is completely resected.

© 2017 Sociedade Brasileira de Anestesiologia. Published by Elsevier Editora Ltda. This is an open access article under the CC BY-NC-ND license (<http://creativecommons.org/licenses/by-nc-nd/4.0/>).

* Corresponding author.

E-mail: alisaitkavakli@hotmail.com (A.S. Kavakli).

PALAVRAS-CHAVE

Tumor cardíaco gigante;
 Mixoma do átrio esquerdo;
 Ressecção cirúrgica;
 Massa residual;
 Ecocardiografia transesofágica

Determinação da massa residual em ventrículo esquerdo por ecocardiografia transesofágica intraoperatória após ressecção de mixoma gigante e flutuante em átrio esquerdo

Resumo Mixoma atrial é um tumor benigno do coração que ocorre principalmente no átrio esquerdo. Os mixomas flutuantes ou grandes em átrio esquerdo com frequência causam estenose mitral funcional, podendo também afetar a estrutura e o fluxo da válvula mitral e levar à insuficiência mitral. A embolização sistêmica ocorre em cerca de 30% dos casos, quer pela fragmentação do tumor ou pelo desprendimento total do tumor; portanto, o tumor deve ser removido assim que detectado. A ecocardiografia transesofágica intraoperatória tem uma importância vital na cirurgia. Após a ressecção do mixoma, a ecocardiografia transesofágica intraoperatória deve ser feita para excluir a massa residual. O caso aqui relatado é o de uma paciente de 48 anos que apresentou um mixoma de átrio esquerdo gigante e flutuante. A massa residual foi detectada com ecocardiografia transesofágica intraoperatória no ventrículo esquerdo após a ressecção do mixoma. Posteriormente, a massa residual foi removida com sucesso. A ressecção completa é necessária para evitar possíveis complicações, como recorrência e embolização em mixomas atriais. A ecocardiografia transesofágica realizada no intraoperatório é de vital importância para confirmar a ressecção completa do mixoma.

© 2017 Sociedade Brasileira de Anestesiologia. Publicado por Elsevier Editora Ltda. Este é um artigo Open Access sob uma licença CC BY-NC-ND (<http://creativecommons.org/licenses/by-nc-nd/4.0/>).

Introduction

Myxomas are the most common primary benign neoplasms of the heart and about 75% of them are located in the left atrium. Myxomas are more common among women and frequently occur between the ages of 30–60 years. Their clinical signs and symptoms may be nonspecific. Large left atrial (LA) myxomas frequently cause functional mitral stenosis, but can also lead to mitral regurgitation.¹ Intraoperative transesophageal echocardiography (TEE) is very important in myxoma surgery. TEE can provide useful information for medical management and surgical intervention of intracardiac tumors and intraoperative TEE assessment may result in a change of the surgical plan.²

Case report

A 46 year-old female patient presented to our hospital with fatigue, progressive palpitation and paroxysmal nocturnal dyspnea for two weeks. On examination, blood pressure was 120/80 mmHg, heart rate 90 beats.min⁻¹. Cardiac auscultation revealed 2/6 systolic murmur in the apex. Lungs were clear to auscultation. A 12 lead electrocardiogram showed sinus rhythm and left axial deviation. Chest X-ray showed normal cardiothoracic ratio. Laboratory parameters were normal. A coronary angiography showed a normal coronal anatomy. Transthoracic Echocardiogram (TTE) revealed a mass of 52 × 37 mm, attached to the interatrial septum with a pedicle. The mass was floating and prolapsed into the left ventricle through the mitral orifice during diastole, leading to mild mitral regurgitation. Thickening, calcification and restricted motion of the mitral leaflets were not observed by TTE. Surgery was planned to remove the mass.

In the operating room, general anesthesia with 37F left sided of double lumen endotracheal tube for one lung

ventilation in the supine position was administered. Anesthesia was maintained with 50% air and 5–6% desflurane in oxygen with positive pressure ventilation in a circle system.

Transesophageal echocardiography monitoring was set up. An arterial cannula (Fr17, Medtronic, Inc, Minneapolis, MN, USA) was positioned into the right jugular vein. A femoral vein cannula (Fr23, Medtronic, Inc, Minneapolis, MN, USA) and femoral arterial cannula (Fr19, Medtronic, Inc, Minneapolis, MN, USA) were applied in the right groin after heparinization.

After one lung ventilation was initiated, a right anterolateral mini-thoracotomy was performed in the 4th intercostal space. Cardioplegia cannula was applied and aortic clamping was obtained. The heart was arrested with anterograde histidine-tryptophan-ketoglutarate solution (Custodiol Dr Franz Köhler Chemie, Alsbach-Hähnlein, Germany). The mass was reached through an atrial transeptal incision. The mass with its pedicle was resected. The left atriotomy was closed using double-layer continuous prolene 3/0 running sutures. Once the patient was weaned off CPB, a transesophageal echocardiographic control was performed. A moving mass of 15 × 15 mm was detected in the left ventricle ([Supplementary data Video clip 1 and 2](#)). Aortic cross clamping was re-applied and the residual mass removed through ventriculotomy. The absence of another residual mass was confirmed by TEE and mild mitral regurgitation was observed with color Doppler ([Supplementary data Video clip 3, Fig. 1](#)). The bypass was terminated after rewarming of the patient to 36.5 °C. The procedural time was 170 min (skin to skin).

After surgery, the patient was transferred to the intensive care unit (ICU). The postoperative course was uneventful. The patient was transferred from ICU to the cardiovascular surgery ward at the postoperative 24th hour and was discharged from the hospital on the sixth postoperative day.

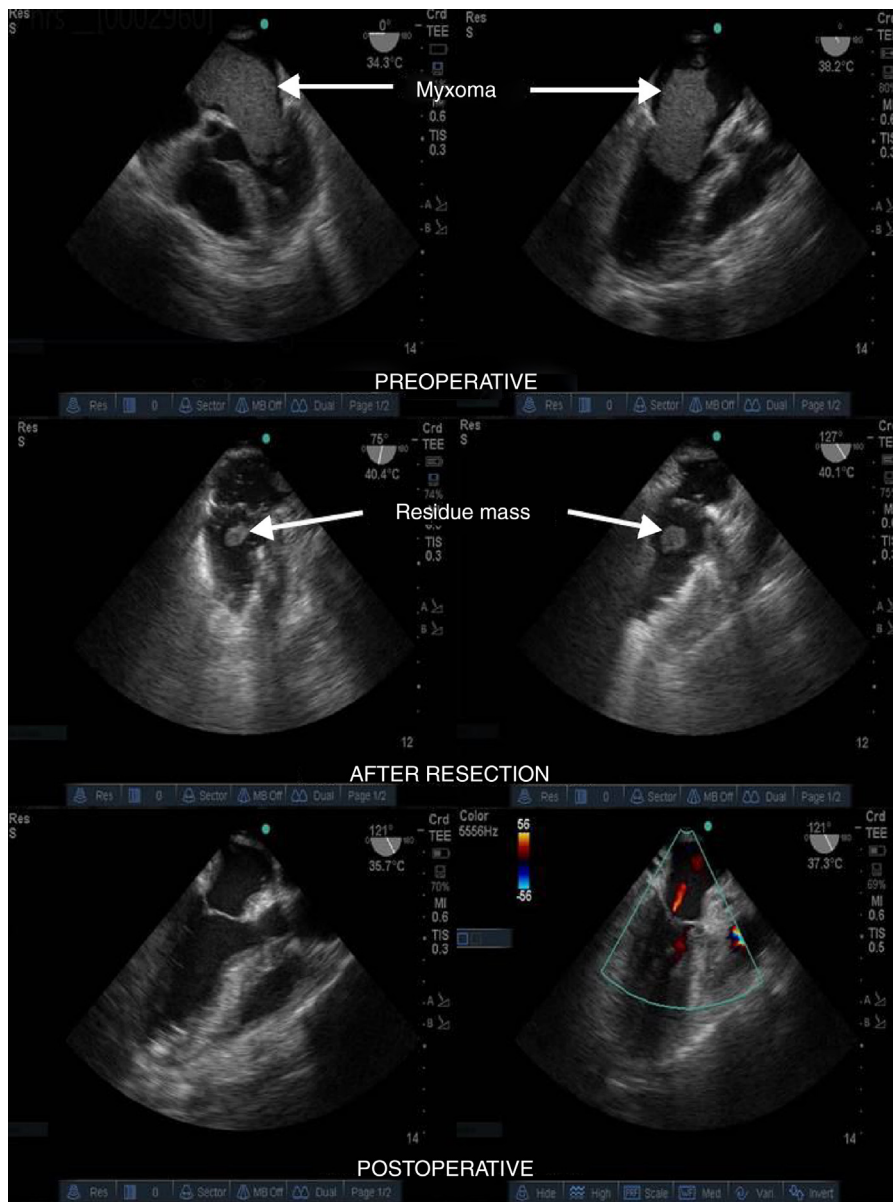


Figure 1 Transesophageal echocardiogram from preoperatively, after resection and postoperatively.

Discussion

Because of risks of embolization, valvular or outflow tract obstruction, and arrhythmogenesis, generally treatment approach is surgery in patients with myxomas and, outcomes are usually favorable. Therefore, surgical excision must be planned as soon as the diagnosis is confirmed.³ Postoperative thromboembolic events are rarely, and atrial arrhythmias are the most common complications after surgery for myxoma.⁴ Myxomas can be resected with low early mortality and excellent long-term survival. Although tumor recurrence is rare, closer imaging is recommended because the recurrence rate is significantly higher for the first 10 years after surgery.⁵

Different approaches for resection of atrial myxoma may be preferred. Median sternotomy for left atrial myxoma resection has been reported a safe surgery, with

minimal mortality and rare recurrence of tumor.⁶ The port-access surgery via a right minithoracotomy has become the standard approach for atrial myxoma at some institutions. Vistarini et al. reported that minimally invasive video-assisted surgery for left atrial myxoma resection was a safe, reproducible and cosmetic operation and could be a valid oncologic approach as an alternative to standard sternotomy.⁷ Similarly, Donk et al. reported that right anterolateral minithoracotomy approach for resection of left atrial myxoma could be safely and lower cost and alternative to standard median sternotomy.⁸ Although port access approach has been safe and effective for resection of left atrial tumors, it has been reported that use of this technique for right atrial tumor resection can be detrimental.⁹

Intraoperative TEE is useful not only in confirming the presence and characteristics of a cardiac tumor but is also fundamental in planning the best surgical approach.¹⁰

Dujardin et al. reported that result of new information provided by intraoperative TEE was changed the surgical plan in 16% of the patients undergoing resection of intracardiac masses.¹¹ One of the surgical purposes is prevention of recurrences. Probable risk factors for recurrence of cardiac myxoma include incomplete resection, intracardiac implantation, embolization and intraoperative displacement of tumor material. Therefore, complete extirpation with precise removal of the base under a clear surgical view is required. Even if there is a clear surgical view and surgical confirmation, it is important to confirm with intraoperative TEE that there is no residual mass.

In our case, the residue mass was noticed with TEE after the resection of the left atrial myxoma, thus avoiding possible complications. This case report emphasizes the importance of TEE in the surgery of atrial myxoma.

Whichever surgical approach is used, complete resection must be required to prevent possible complications such as recurrence, embolization in atrial myxomas. TEE performed intraoperatively is vital importance to confirm that the myxoma is completely resected.

Conflicts of interest

The authors declare no conflicts of interest.

Appendix A. Supplementary data

Supplementary data associated with this article can be found, in the online version, at [doi:10.1016/j.bjane.2017.10.002](https://doi.org/10.1016/j.bjane.2017.10.002).

References

1. Reynen K. Cardiac myxomas. *N Engl J Med*. 1995;333:1610–7.
2. Dharmalingam SK, Sahajanandan R. Intraoperative transesophageal echocardiography assessment of right atrial myxoma resulting in a change of the surgical plan. *Ann Card Anaesth*. 2014;17:306–8.
3. Butany J, Nair V, Naseemuddin A, et al. Cardiac tumours: diagnosis and management. *Lancet Oncol*. 2005;6:219–28.
4. Samanidis G, Perreas K, Kalogris P, et al. Surgical treatment of primary intracardiac myxoma: 19 years of experience. *Interact Cardiovasc Thorac Surg*. 2011;13:597–600.
5. Shah IK, Dearani JA, Daly RC, et al. Cardiac myxomas: a 50-year experience with resection and analysis of risk factors for recurrence. *Ann Thorac Surg*. 2015;100:495–500.
6. ElBardissi AW, Dearani JA, Daly RC, et al. Survival after resection of primary cardiac tumors: a 48-year experience. *Circulation*. 2008;118:7–15.
7. Vistarini N, Alloni A, Aiello M, et al. Minimally invasive video-assisted approach for left atrial myxoma resection. *Interact Cardiovasc Thorac Surg*. 2010;10:9–11.
8. Dong NG, Zhang KL, Wu L, et al. Right anterolateral minithoracotomy versus median sternotomy approach for resection of left atrial myxoma. *Thorac Cardiovasc Surg*. 2018;66:193–7.
9. Bakir I, Van Vaerenbergh G, Deshpande R, et al. Right atrial tumor: a contraindication to minimally invasive surgery? *Innovations (Phila)*. 2009;4:39–42.
10. Connors CW, Locke A, Silver DA. Surgical approach to a left ventricular mass guided by transesophageal echocardiography. *Anesth Analg*. 2009;108:1465–6.
11. Dujardin KS, Click RL, Oh JK. The role of intraoperative transesophageal echocardiography in patients undergoing cardiac mass removal. *J Am Soc Echocardiogr*. 2000;13:1080–3.