



REVISTA BRASILEIRA DE ANESTESIOLOGIA

Publicação Oficial da Sociedade Brasileira de Anestesiologia
www.sba.com.br



CLINICAL INFORMATION

Internal carotid artery dissection after laparoscopic surgery



Esperanza Martín-Mateos^a, Manuel Ángel Gómez-Ríos^{a,b,*}, Enrique Freire-Vila^{a,b}

^a *Complejo Hospitalario Universitario de A Coruña, Departamento de Anestesiología y Medicina Perioperatoria, A Coruña, Spain*

^b *Instituto de Investigación Biomédica de A Coruña (Inibic), Grupo de Investigación de Anestesiología y Control del Dolor, A Coruña, Spain*

Received 1 September 2016; accepted 11 January 2017

Available online 17 April 2017

KEYWORDS

Carotid dissection;
Anesthesia;
Laparoscopy;
Complication

Abstract Headache is a common symptom in the postoperative period and may be attributable to, dehydration, sleep deprivation, intentional or inadvertent dural puncture during a neuraxial anesthesia technique, from an inhaled anesthetic agent, or from specific surgical procedures, among other etiologies. However, more serious, uncommon and life-threatening conditions as carotid artery dissection can be associated with severe neurologic sequelae in otherwise young, healthy patients. For these reasons, clinicians involved with postoperative patients should be familiar with the presentation and management strategies for this complication.

© 2017 Published by Elsevier Editora Ltda. on behalf of Sociedade Brasileira de Anestesiologia. This is an open access article under the CC BY-NC-ND license (<http://creativecommons.org/licenses/by-nc-nd/4.0/>).

PALAVRAS-CHAVE

Dissecção carotídea;
Anestesia;
Laparoscopia;
Complicação

Dissecção da artéria carótida interna após cirurgia laparoscópica

Resumo A cefaleia é um sintoma comum no período pós-operatório e pode ser atribuída à desidratação, privação do sono, punção dural intencional ou acidental durante a administração de anestesia neuraxial, ao anestésico inalatório ou a procedimentos cirúrgicos específicos, entre outras etiologias. Entretanto, condições mais graves, incomuns e potencialmente fatais, como a dissecção da artéria carótida, podem estar associadas a sequelas neurológicas graves em pacientes jovens e, sob outros aspectos, saudáveis. Portanto, os médicos envolvidos com pacientes pós-operados devem estar familiarizados com as estratégias de apresentação e manejo dessa complicação.

© 2017 Publicado por Elsevier Editora Ltda. em nome de Sociedade Brasileira de Anestesiologia. Este é um artigo Open Access sob uma licença CC BY-NC-ND (<http://creativecommons.org/licenses/by-nc-nd/4.0/>).

* Corresponding author.

E-mail: magoris@hotmail.com (M.Á. Gómez-Ríos).

<https://doi.org/10.1016/j.bjane.2017.04.002>

0104-0014/© 2017 Published by Elsevier Editora Ltda. on behalf of Sociedade Brasileira de Anestesiologia. This is an open access article under the CC BY-NC-ND license (<http://creativecommons.org/licenses/by-nc-nd/4.0/>).

Introduction

Postoperative headache is common, can delay discharge, and can contribute to patients' suffering and dissatisfaction with their care. It may result from dehydration, sleep deprivation, intentional or inadvertent dural puncture during a neuraxial anesthesia technique, from an inhaled anesthetic agent, or from specific surgical procedures. However, atypical features (atypical distribution, absence of postural component, unresponsiveness to analgesics), accompanying neurological symptoms, or the presence of vomiting, seizures, altered level of consciousness and focal motor and sensory deficits should lead to consideration of other causes whose consequences can be devastating if an early diagnosis and treatment are not performed. We report a case of an otherwise healthy female who presented with persistent headache and partial Horner's syndrome after laparoscopic surgery and was ultimately found to have an Internal Carotid Artery Dissection (ICAD). The patient gave written informed consent for publication of this article.

Case report

The patient was a 39-year-old, 58 kg female without relevant medical history. She was scheduled for laparoscopic right adnexectomy due to mucinous cystadenoma. Preoperative physical examination and routine laboratory studies were unremarkable.

Following application of standard monitoring and pre-oxygenation with a facemask, general anesthesia was induced with fentanyl (2–3 µg/kg) and propofol (2 mg/kg), and muscle relaxation was achieved with rocuronium (0.6 mg/kg). Endotracheal intubation was performed using the Totaltrack™ size 3 with a 7 mm inner diameter cuffed endotracheal tube. Tracheal intubation produced no significant changes in vital signs. The pressure-controlled ventilation was adjusted to maintain normocapnia using a mixture of oxygen–air (FiO 50%). Maintenance of general anesthesia was carried out using sevoflurane and remifentanyl. Induction and maintenance of anesthesia throughout the surgery was uneventful. The procedure was carried out without incident, and the patient's trachea was extubated at the end of the operation, with minimal fluctuation in arterial blood pressure and pulse rate. She was transferred to the recovery unit.

In the post-anesthesia care unit, patient developed a persistent oppressive right-sided frontotemporal headache and neck pain with swallowing. The headache was of mild intensity and did not have any "throbbing" or pulsating qualities. Acetaminophen and nonsteroidal anti-inflammatory drugs provided no substantial relief. Neurological examination showed an ipsilateral partial ptosis and reactive miosis without visual loss. There was no evidence of other neurological deficits. Computed Tomography (CT) of the brain was normal. However, a subsequent contrast angiography revealed segmental narrowing from the post bulbar segment of the right internal carotid artery extending into the petrous segment of the vessel (Fig. 1). These findings were consistent with a spontaneous ICAD. The remaining diagnostic work-up was unremarkable. Anticoagulation and antiplatelet therapy was initiated. Our patient had a favorable evolution

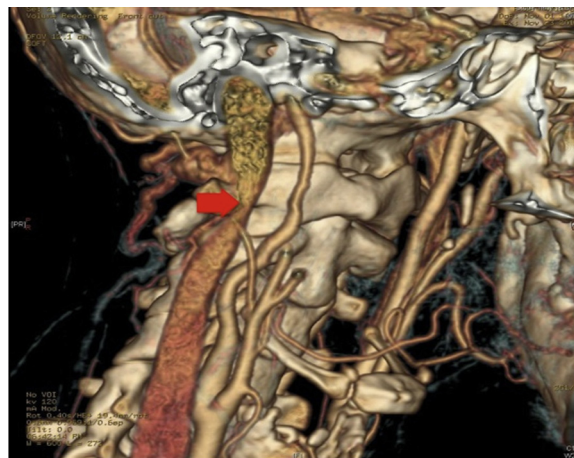


Figure 1 Angio-CT showing stenosis in cervical segment of the right internal carotid artery compatible with an internal carotid artery dissection.

and was discharged home without any neurologic sequelae. The patient remained asymptomatic 6 months afterwards, and a follow-up magnetic resonance imaging showed an ad integrum restitution of the artery.

Discussion

Carotid artery dissection is a rare condition, mostly occurring in previously healthy, young individuals. Its incidence is still likely underestimated, as asymptomatic patients are not captured by the majority of studies.¹ The annual incidence of stroke due to ICAD is 1.21/100,000 per year.¹

The pathophysiology of ICAD involves genetic, anatomic and environmental factors (Table 1). Vascular layers

Table 1 Risk factors associated with carotid artery dissection.

Genetic factors	Acquired and anatomic factors
Marfan syndrome	Cervical trauma
Ehlers–Danlos syndrome type IV	Iatrogenic after surgical interventions
Osteogenesis imperfecta type I	Medical procedures
Fibromuscular dysplasia	Oropharyngeal infections
Hyperhomocysteinemia	Arterial hypertension
Hemochromatosis	Vascular tortuosity
α1-Antitrypsin deficiency	Aorta coarctation
Turner syndrome	Illicit drug abuse
Down syndrome	Chiropractic cervical manipulation
Williams syndrome	Severe exercise
Menkes disease	Vomiting
Moyamoya disease	Violent coughing or sneezing
	Migraine
Polycystic kidney disease	
Pseudoxanthoma elasticum	

separate, creating a false lumen, which may lead to stenosis, occlusion or formation of an intramural hematoma and pseudo-aneurysm.² Thrombus formation may lead to life-threatening emboli by fragmentation.¹ Its etiology is either spontaneous or traumatic, although simple manipulation of the neck can evoke a dissection.³ Thus, there have been reports of ICAD related to medical procedures such as bronchoscopy, rigid esophagoscopy, endotracheal intubation, catheterization of the jugular vein, hyperextension of the head during mask ventilation and tracheal intubation or tonsillectomy.^{4–6} In our case, several factors may have contributed to formation of ICAD. The combination of pneumoperitoneum along with the steep Trendelenburg position during laparoscopy affect cerebrovascular and hemodynamic homeostasis increasing the risk of arterial dissections.⁷ Pneumoperitoneum may cause intraoperative hypertension and vascular instability. It is thought to be either through the activation of a neuro-humoral response or as a result of pain from stretching of the peritoneum. Increasing intrathoracic pressure during laparoscopy induces high shear stresses on the arterial wall of the brachiocephalic vessels due to pressure changes.⁷ It might produce intimal injury. The Trendelenburg position also cause increased intracranial pressure and increase cardiac output that may intensify hemodynamic forces applied to vessel walls. Cervical extension and rotation or sudden lateroversion neck movements can compress the cervical carotid artery against any of the transverse processes, cervical vertebrae or the styloid process of the mastoid bone, leading to dissection. Likewise, neck hyperextension with axial rotation of the head during endotracheal intubation could have played a role,⁶ however the use of Totaltrack™ device allowed an orotracheal intubation with the head in a neutral position.⁸

Diagnosis of ICAD can be delayed because of a low index of suspicion or symptoms may be absent or may seem unimportant.^{1–3} The classic triad of unilateral pain in the head, face or neck, partial Horner's syndrome and cerebral ischemia is found in fewer than 30% of cases.¹ However, the 60%–90% of patients present with headache, neck, or headache and neck pain, which typically precede neurologic symptoms by hours to days. Horner's syndrome results from disruption of the ocular and facial sympathetic pathways that ascend within the carotid sheath.⁹ Anhidrosis may be absent because sympathetic fibers that innervate the facial sweat glands follow the external carotid artery.¹⁰ Cranial nerve palsies and pulsatile tinnitus have also been reported.

Because diagnosis of carotid injury is rarely suspected, the first diagnostic test performed is usually CT of the brain. However, the gold standard for diagnosis of ICAD is contrast angiography, showing a string sign, a double lumen, or intimal flaps.¹¹ Magnetic Resonance Imaging (MRI) and/or magnetic resonance angiography are reliable methods for diagnosis and follow-up.¹⁰

Treatment of carotid artery dissection consists of avoiding or limiting neurological deficit through the prevention of thrombus formation or associated embolism. Therefore, anticoagulation, antiplatelet therapy, or anticoagulation and antiplatelet therapy are the mainstay of the treatment,

although the optimal antithrombotic strategy has been controversial.¹ Endovascular therapy or surgery is the treatment of choice in specific situations,² including the following: dissections with flow limiting stenosis; "isolated hemisphere" dependence on the dissected artery for perfusion; failure of medical therapy with worsening hemodynamic dependent neurologic symptoms or imaging findings; multiple bilateral arterial dissections that may progress to cause hemodynamic compromise or expanding aneurysm.

Long-term prognosis appears to be favorable if diagnosis and treatment are prompt, with complete recovery in at least 50% of cases. The risk of recurrence is highest within the first month and remains about 1% per year after the first year, so it requires follow-up imaging studies.²

Carotid artery dissection should be considered in the differential diagnosis of postoperative headache. The presence of ipsilateral headache, facial pain or neck pain, oculomotor paresis or transient ischemic attack should lead to a high index of suspicion. Early recognition is important so that treatment may be initiated before complete vessel occlusion or embolic sequelae to avoid serious and potentially life-threatening neurologic deficits.

Conflicts of interest

The authors declare no conflicts of interest.

References

1. Ortiz J, Ruland S. Cervicocerebral artery dissection. *Curr Opin Cardiol.* 2015;30:603–10.
2. Patel RR, Adam R, Maldjian C, et al. Cervical carotid artery dissection: current review of diagnosis and treatment. *Cardiol Rev.* 2012;20:145–52.
3. Rubinstein SM, Peerdeman SM, van Tulder MW, et al. A systematic review of the risk factors for cervical artery dissection. *Stroke.* 2005;36:1575–80.
4. Ricchetti A, Becker M, Dulguerov P. Internal carotid artery dissection following rigid esophagoscopy. *Arch Otolaryngol Head Neck Surg.* 1999;125:805–7.
5. Parsons AJ, Alfa J. Carotid dissection: a complication of internal jugular vein cannulation with the use of ultrasound. *Anesth Analg.* 2009;109:135–6.
6. Gould DB, Cunningham K. Internal carotid artery dissection after remote surgery. Iatrogenic complications of anesthesia. *Stroke.* 1994;25:1276–8.
7. Hayden P, Cowman S. Anaesthesia for laparoscopic surgery. *Continuing education in anaesthesia.* *Crit Care Pain.* 2011;11:177–80.
8. Gómez-Ríos MÁ, Freire-Vila E, Vizcaino-Martínez L, et al. The Totaltrack™: an initial evaluation. *Br J Anaesth.* 2015;115:798–9.
9. Lyrer PA, Brandt T, Metso TM, et al. Clinical import of Horner syndrome in internal carotid and vertebral artery dissection. *Neurology.* 2014;82:1653–9.
10. Padaki AS, Fitch RW, Stack LB, et al. Horner's syndrome after scalene block and carotid dissection. *J Emerg Med.* 2016;50:e215–8.
11. Toelen C, Goverde P, Van Hee R. Dissection of the common carotid artery: a case report. *Acta Chir Belg.* 2009;109:224–7.