



REVISTA BRASILEIRA DE ANESTESIOLOGIA

Publicação Oficial da Sociedade Brasileira de Anestesiologia
www.sba.com.br



CLINICAL INFORMATION

Difficult fiberoptic tracheal intubation in 1 month-old infant with Treacher Collins Syndrome



Ricardo Fuentes, Juan Carlos De la Cuadra, Hector Lacassie, Alejandro González*

Pontificia Universidad Católica de Chile, Facultad de Medicina, División de Anestesiología, Santiago, Chile

Received 12 January 2015; accepted 11 February 2015

Available online 1 October 2015

KEYWORDS

Treacher Collins Syndrome;
Difficult airway;
Fiberoptic bronchoscope;
Laryngeal mask airway;
Infants

Abstract Neonates and small infants with craniofacial malformation may be very difficult or impossible to mask ventilate or intubate. We would like to report the fiberoptic intubation of a small infant with Treacher Collins Syndrome using the technique described by Ellis et al.

Case report: An one month-old infant with Treacher Collins Syndrome was scheduled for mandibular surgery under general endotracheal anesthesia. Direct laryngoscopy for oral intubation failed to reveal the glottis. Fiberoptic intubation using nasal approach and using oral approach through a 1.5 size laryngeal mask airway were performed; however, both approach failed because the fiberscope loaded with a one 3.5 mm ID uncuffed tube was stuck inside the nasal cavity or inside the laryngeal mask airway respectively. Therefore, the laryngeal mask airway was keep in place and the fiberoptic intubation technique described by Ellis et al. was planned: the tracheal tube with the 15 mm adapter removed was loaded proximally over the fiberscope; the fiberscope was advanced under video-screen visualization into the trachea; the laryngeal mask airway was removed, leaving the fiberscope in place; the tracheal tube was passed completely through the laryngeal mask airway and advanced down over the fiberscope into the trachea; the fiberscope was removed and the 15 mm adapter was reattached to the tracheal tube.

Conclusion: The fiberoptic intubation method through a laryngeal mask airway described by Ellis et al. can be successfully used in small infants with Treacher Collins Syndrome.

© 2015 Sociedade Brasileira de Anestesiologia. Published by Elsevier Editora Ltda. This is an open access article under the CC BY-NC-ND license (<http://creativecommons.org/licenses/by-nc-nd/4.0/>).

PALAVRAS-CHAVE

Síndrome de Treacher Collins;
Via aérea difícil;
Broncoscópio de fibra óptica;

Intubação traqueal difícil com fibra óptica em bebê de um mês de idade com síndrome de Treacher Collins

Resumo Os recém-nascidos e crianças pequenas com malformação craniofacial podem ser muito difíceis ou impossíveis de ventilar por máscara ou de intubar. Gostaríamos de relatar a intubação com fibra óptica de um bebê com síndrome de Treacher Collins usando a técnica descrita por Ellis et al.

* Corresponding author.

E-mail: gonzalea@med.puc.cl (A. González).

Máscara laríngea; Bebês

Relato de caso: Uma criança de um mês de idade com síndrome de Treacher Collins foi programada para cirurgia mandibular sob anestesia geral endotraqueal. A laringoscopia direta para intubação oral não revelou a glote. A intubação com fibra óptica usando as abordagens nasal e oral por meio de máscara laríngea de tamanho 1,5 foi tentada, mas ambas as abordagens falharam porque o fibroscópio portando um tubo sem balonete de 3,5 mm ficou preso no interior da cavidade nasal ou dentro da máscara laríngea, respectivamente. Portanto, a máscara laríngea foi mantida no lugar e a técnica de intubação com fibra óptica descrito por Ellis et al. foi planejada: o tubo traqueal com o adaptador de 15 mm removido foi colocado proximalmente sobre o fibroscópio; o fibroscópio foi avançado na traquéia sob visualização em tela de vídeo; a máscara laríngea foi removida, deixando o fibroscópio no lugar; o tubo traqueal foi passado completamente através da máscara laríngea e avançado para baixo sobre o fibroscópio na traquéia; o fibroscópio foi removido e o adaptador de 15 mm foi recolocado no tubo traqueal. *Conclusão:* O método de intubação com fibra óptica através de uma máscara laríngea descrito por Ellis et al. pode ser usado com sucesso em bebês com síndrome de Treacher Collins.

© 2015 Sociedade Brasileira de Anestesiologia. Publicado por Elsevier Editora Ltda. Este é um artigo Open Access sob uma licença CC BY-NC-ND (<http://creativecommons.org/licenses/by-nc-nd/4.0/>).

Introduction

Treacher Collins Syndrome is a congenital craniofacial malformation mainly characterized by bilateral hypoplasia of facial bones (mandible, maxilla and zygoma), cleft palate, ears and eyes deformities and temporomandibular joint abnormalities. Patients with this syndrome may be very difficult or impossible to mask ventilate or intubate.^{1,2}

Several techniques and devices have been successfully used to intubate pediatric patients with Treacher Collins Syndrome.¹⁻¹⁰ In newborns and small infants with Treacher Collins Syndrome only the use of laryngeal mask airway (LMA), fiberoptic bronchoscope (FB) and, more recently, two different optical devices have been described to handle the airway.¹¹⁻¹⁵ We would like to report the tracheal intubation of 1-month-old infant with Treacher Collins Syndrome, undergoing mandibular surgery, using the fiberoptic intubation method described by Ellis et al.¹⁶

Case report

Consent for publication was obtained from the patient's father. A 1 month old, 5 kg boy, with upper airway obstruction secondary to Treacher Collins Syndrome was scheduled for mandibular distraction osteogenesis under general endotracheal anesthesia. He had a significant micrognathia; therefore difficult tracheal intubation was anticipated. A nasal intubation was planned using conventional direct laryngoscopy or, in case of failure, using a pediatric FB with no working channel (Fujinon 120P, 2.8 mm OD; Fujinon Corporation, Saitama, Japan). Fiberoptic oral intubation through a LMA would be the next step if previous approaches were unsuccessful. Two senior pediatric anesthesiologists, a senior anesthesia registrar and two senior plastic surgeons were present in the operating room, and we were prepared for a tracheostomy if mentioned methods were unsuccessful.

In the operating room, before the anesthesia induction, the airway devices were checked and that the pediatric

FB would fit easily through a 3.5 mm ID uncuffed tracheal tube (Rusch Uruguay Ltda., Montevideo, Uruguay). Standard monitoring were applied while the infant received 100% O₂ via facial mask. Atropine 0.01 mg.kg⁻¹ was administered through a 24 gauge intravenous cannula previously inserted. In order to maintain spontaneous ventilation, inhalation induction was performed with increasing doses of sevoflurane in an air/O₂ mixture to obtain 4% end tidal concentration. Lung ventilation was easily assisted with bag and facial mask. Direct laryngoscopy with a Miller 0 blade failed to reveal the vocal cords. Then, we moved to fiberoptic nasal intubation. Maintaining an adequate anesthesia depth and spontaneous ventilation, a 3.5 mm ID uncuffed tracheal tube was carefully inserted through one naris into the nasopharynx to verify that passed easily across the nasal cavity and to facilitate the fiberoptic intubation. However, the FB was stuck inside the lumen of nasal tube and could not move further. Therefore, we went to the next step to secure the airway.

We verified that a FB loaded with a 3.5 mm ID uncuffed tracheal tube could pass both together through a size 1.5 LMA (Unique, LMA North America, San Diego, USA) lumen that had its grill bars previously cut. The LMA was gently inserted and its correct position was confirmed by end tidal CO₂ and the ability to provide assisted ventilation. The FB was threaded through the tracheal tube and both together were introduced and advanced into the LMA lumen under video-screen visualization. However, the tracheal tube with the FB in its interior was stuck inside the LMA lumen and anyone could not advance further, and both were removed keeping the LMA in place. At that time, we decided to try the fiberoptic intubating method through LMA described by Ellis et al.¹⁶ (Fig. 1).

A new 3.5 mm ID uncuffed tracheal tube with the 15 mm adapter removed was loaded proximally over the bronchoscope. The FB was introduced easily through the size 1.5 LMA and advanced under video-screen visualization into the trachea until the carina was visualized (Fig. 1A). Then, the LMA was deflated and removed from the mouth, leaving the FB in the trachea (Fig. 1B). The tracheal tube was

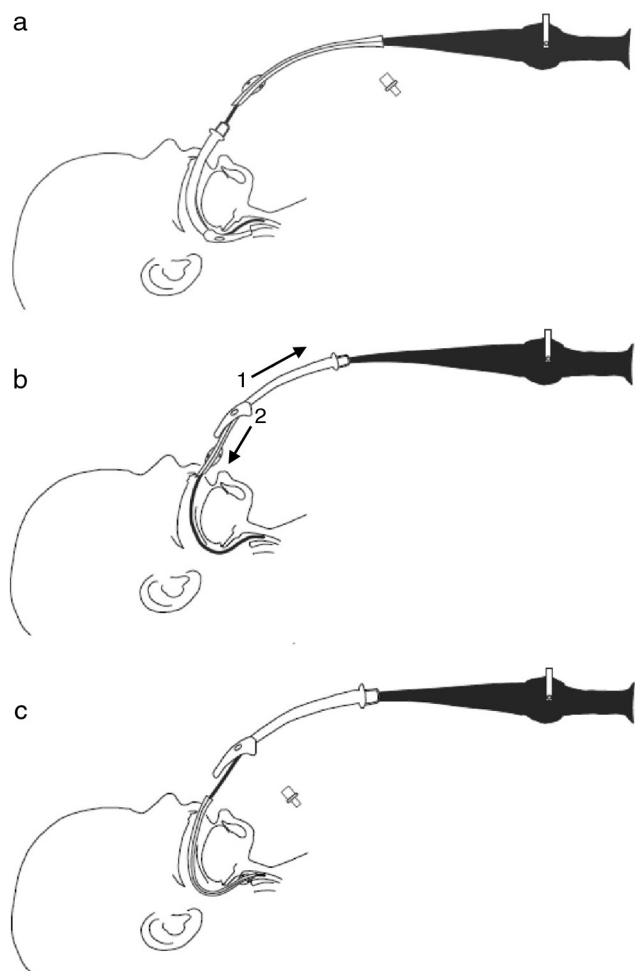


Figure 1 Fiberoptic intubation method through a laryngeal mask airway (LMA) described by Ellis et al.¹⁶ (A) The fiberoptic bronchoscope (FB) loaded proximally with a tracheal tube without 15 mm adapter is introduced and advanced through the LMA into the trachea. (B) The LMA is removed from the mouth and pulled up, and the tracheal tube is passed down through the LMA lumen. (C) The tracheal tube is advanced down over the FB into the trachea.

passed completely through the removed LMA (Fig. 1B) and advanced down over FB into the trachea (Fig. 1C). The FB was removed, the 15 mm tube adapter was reattached and the proper tracheal tube position was confirmed by end tidal CO₂ and the auscultation of bilateral breathing sound. The patient was connected to mechanical ventilation. The overall airway management procedure lasted for 1 h and vital signs were always within normal range. Surgery and the postoperative period in intensive care unit were uneventful.

One month later, the small infant was scheduled for a laparoscopic Nissen fundoplication. Again, visualization of the vocal cords during laryngoscopy with Miller 0 blade was not possible and the oral tracheal intubation was successfully performed with the method described previously.

Discussion

Difficult intubation in pediatric patients is usually anticipated and gives us some time to be prepared. Nevertheless,

it is always challenging and it requires experience in handle difficult pediatric airway and diverse airway instruments available. Several airway management techniques have been described in pediatric patients with craniofacial malformation.¹⁻¹⁷ However, there are only few devices in sizes that fit neonates and small infants, and that have been successfully used to secure the airway in Treacher Collins Syndrome;^{1,11-13,16} we have only available LMA and pediatric FB suitable for those patients. In the patient reported, a nasotracheal intubation was our first choice, because this airway approach is more appropriate for surgical access in mandibular distraction osteogenesis. Nevertheless, the nasal tube probably bent inside the nasal cavity narrowed by the facial hypoplasia, reducing its lumen and making fail the fiberoptic nasal intubation.

The use of a LMA in infants with difficult intubation is an established means for securing the airway: it provides a patent airway, it allows assisted ventilation of the anesthetized child and it serves as a conduit for intubation. The problem with this oral intubation technique is how to remove the LMA and FB without dislodging the tube from the trachea.¹⁸⁻²⁰ There are alternatives to solve this issue such as to leave the LMA in place if it does not interfere with surgery^{18,19}; to extend the length of tracheal tube with another tube of similar size and threading both on the bronchoscope using the proximal to hold the distal tube,^{3,13,18,19} allowing also uninterrupted ventilation during withdrawal of LMA,²⁰ and to place a wire through the bronchoscope and to advance a tube over the wire.^{18,19} In this case, our approach was to use two tracheal tubes, the proximal end of one wedged into the distal end of the other, to remove the FB and LMA. Due to the failure of nasal intubation, we decided first to be sure that the tracheal tube with the FB inside could pass through the LMA already in place. We think that a similar phenomenon of the nasal intubation could happen in the oral cavity and it would explain that the FB loaded with the tracheal tube was stuck inside the LMA lumen. The craniofacial abnormalities of Treacher Collins Syndrome probably reduce and deform the nasal and oral cavities; in addition, the tongue (due to mandibular hypoplasia) protrude posteriorly and may displace and deform the shaft of the LMA as reported by Inada et al.⁴ in their pediatric patients with Treacher Collins Syndrome. These events would explain the failure of both fiberoptic intubation approaches.

The LMA left in place allowed us to ventilate, to oxygenate and to keep the infant adequately anaesthetized while we decided how to solve this problem. Afterwards, we use the fiberoptic oral intubation method in which the tracheal tube was advanced easily over de FB after the LMA was removed. This method was described by Ellis et al.¹⁶ to handle the airway in a neonate with anasarca and laryngeal edema and, as the authors mention, is an alternative of oral intubation through a LMA in situations where the laryngeal mask it must be removed. To the best of our knowledge there are no previous reports of the successful use of this intubation method in a 1 month-old infant with Treacher Collins Syndrome.

In summary, we have shown that the method described by Ellis et al.¹⁶ can be successfully used for fiberoptic oral intubation through the LMA in small infants with Treacher Collins Syndrome. In our opinion, the key points of difficult pediatric airway management are to provide adequate depth of

anesthesia, to maintain spontaneous ventilation and to have experience in different intubation techniques.

Conflicts of interest

The authors declare no conflicts of interest.

References

- Hosking J, Zoanetti D, Carlyle A, et al. Anesthesia for Treacher Collins syndrome: a review of airway management in 240 pediatric cases. *Pediatr Anesth.* 2012;22:752–8.
- Frawley G, Espenell A, Howe P, et al. Anesthetic implications of infants with mandibular hypoplasia treated with mandibular distraction osteogenesis. *Pediatr Anesth.* 2013;23:342–8.
- Muraika L, Heyman JS, Shevchenko Y. Fiberoptic tracheal intubation through a laryngeal mask airway in a child with Treacher Collins syndrome. *Anesth Analg.* 2003;97:1298–9.
- Inada T, Fujise K, Tachibana K, et al. Orotracheal intubation through the laryngeal mask airway in paediatric patients with Treacher Collins syndrome. *Paediatr Anaesth.* 1995;5:129–32.
- Bishop S, Clements P, Kale K, et al. Use of GlideScope Ranger in the management of a child with Treacher Collins syndrome in a developing world setting. *Pediatr Anesth.* 2009;19:695–6.
- Péan D, Desdoits A, Asehnoune K, et al. Airtraq laryngoscope for intubation in Treacher Collins syndrome. *Pediatr Anesth.* 2009;19:698–9.
- Hirabayashi Y, Shimada N, Nagashima S. Tracheal intubation using pediatric Airtraq® optical laryngoscope in a patient with Treacher Collins syndrome. *Pediatr Anesth.* 2009;19:915–6.
- Sugawara Y, Inagawa G, Satoh K, et al. Successful intubation using a simple fiberoptic assisted laryngoscope for Treacher Collins syndrome. *Pediatr Anesth.* 2009;19:1031–3.
- Ebata T, Nishiki S, Masuda A, et al. Anesthesia for Treacher Collins syndrome using laryngeal mask airway. *Can J Anaesth.* 1991;38:1043–5.
- Jagannathan N, Roth AG, Sohn LE, et al. The new air-Q™ intubating laryngeal airway for tracheal intubation in children with anticipated difficult airway: a case series. *Pediatr Anesth.* 2009;19:618–22.
- Bucx MJL, Grolman W, Krusinga FH, et al. The prolonged use of the laryngeal mask airway in a neonate with airway obstruction and Treacher Collins syndrome. *Paediatr Anaesth.* 2003;13:530–3.
- Nilsson E, Ingvarsson L, Isern E. Treacher Collins syndrome with choanal atresia: one way to handle the airway. *Pediatr Anesth.* 2004;14:700–1.
- Asai T, Nagata A, Shingu K. Awake tracheal intubation through the laryngeal mask in neonates with upper airway obstruction. *Pediatr Anesth.* 2008;18:77–80.
- Gómez-Rios MA, Serradilla LN, Alvarez AE. Use of the TruView EVO2 laryngoscope in Treacher Collins syndrome after unplanned extubation. *J Clin Anesth.* 2012;24:257–8.
- Shurry M, Hanson RD, Koveleskie JR, et al. Management of the difficult pediatric airway with Shikani Optical Stylet™. *Pediatr Anesth.* 2005;15:342–5.
- Ellis DS, Potluri PK, O’Flaherty JE, et al. Difficult airway management in the neonate: a simple method of intubating through a laryngeal mask airway. *Paediatr Anaesth.* 1999;9:460–2.
- Holm-Knudsen R. The difficult pediatric airway – a review of new devices for indirect laryngoscopy in children younger than two years of age. *Pediatr Anesth.* 2011;21:98–103.
- Walker RW, Ellwood J. The management of difficult intubation in children. *Pediatr Anesth.* 2009;19:77–87.
- Wheeler M, Coté CJ, Todres D. The pediatric airway. In: Coté CJ, Lerman J, Todres D, editors. *Practice of anesthesia in infants and children.* 4th ed. Philadelphia, PA: Saunders Elseiver; 2009. p. 237–78.
- Weiss M, Gerber AC, Schmitz A. Continuous ventilation technique for laryngeal mask airway (LMA™) removal after fiberoptic intubation in children. *Pediatr Anesth.* 2004;14:936–40.