



# REVISTA BRASILEIRA DE ANESTESIOLOGIA

Publicação Oficial da Sociedade Brasileira de Anestesiologia  
[www.sba.com.br](http://www.sba.com.br)



## CLINICAL INFORMATION

### *Quadratus lumborum* block in chronic pain after abdominal hernia repair: case report



Rita Carvalho\*, Elena Segura, Maria do Céu Loureiro, José Pedro Assunção

Centro Hospitalar Tondela-Viseu, Serviço de Anestesiologia, Viseu, Portugal

Received 23 July 2014; accepted 26 August 2014

Available online 11 November 2016

#### KEYWORDS

Pain;  
Chronic;  
Neuropathic;  
*Quadratus lumborum*;  
Ultrasonography

#### Abstract

**Background and objectives:** The *quadratus lumborum* blockade was described by R. Blanco in its two approaches (I and II). The local anesthetic deposition in this location can provide blockade to T6-L1 dermatomes. We performed this fascia blockade guided by ultrasound for treating a chronic neuropathic pain in the abdominal wall.

**Case report:** Male patient, 61 years old, 83 kg, with a history of thrombocytopenia due to alcoholic cirrhosis, among others; had chronic pain in the abdominal wall after multiple abdominal hernia repairs in the last year and a half, with poor response to treatment with neuromodulators and opioids. On clinical examination, he revealed a neuropathic pain, with prevalence of allodynia to touch, covering the entire anterior abdominal wall, from T7 to T12 dermatomes. We opted for a *quadratus lumborum* block type II, guided by ultrasound, with administration of 0.2% ropivacaine (25 mL) and depot (vial) methylprednisolone (20 mg) on each side. The procedure gave immediate relief of symptoms and, after six months, the patient still had a significant reduction in allodynia without compromising the quality of life.

**Conclusions:** We consider that performing the *quadratus lumborum* block type II was an important analgesic option in the treatment of a patient with chronic pain after abdominal hernia repair, emphasizing the effects of local anesthetic spread to the thoracic paravertebral space. The technique has proven to be safe and well tolerated. The publication of more clinical cases reporting the effectiveness of this blockade for chronic pain is desirable.

© 2014 Sociedade Brasileira de Anestesiologia. Published by Elsevier Editora Ltda. This is an open access article under the CC BY-NC-ND license (<http://creativecommons.org/licenses/by-nc-nd/4.0/>).

\* Corresponding author.

E-mail: [ritasfcarvalho@hotmail.com](mailto:ritasfcarvalho@hotmail.com) (R. Carvalho).

**PALAVRAS-CHAVE**

Dor;  
Crônica;  
Neuropática;  
Quadrado lombar;  
Ultrassonografia

**Bloqueio do quadrado lombar em dor crônica pós-hernioplastia abdominal: relato de caso****Resumo**

*Justificativa e objetivos:* O bloqueio da fásia do músculo quadrado lombar foi descrito por R. Blanco nas suas duas abordagens (I e II). A deposição de anestésico local nessa localização pode conferir bloqueio dos dermatômos T6-L1. Os autores fizeram esse bloqueio de fásia, guiado por ultrassom, para tratamento de uma dor crônica neuropática da parede abdominal.

*Relato de caso:* Paciente do gênero masculino, 61 anos, 83 kg, com antecedentes de trombocitopenia por hepatopatia alcoólica, entre outros, apresentava dor crônica da parede abdominal após hernioplastias abdominais múltiplas havia um ano e meio, com má resposta ao tratamento com neuromoduladores e opioides. No exame clínico, apresentava uma dor neuropática, com predomínio de alodinia ao toque, que abrangia toda a parede abdominal anterior, desde os dermatômos T7 a T12. Optou-se pela realização de um bloqueio do quadrado lombar tipo II bilateral, guiado por ultrassom, com administração de 25 mL de ropivacaína 0,2% e 20 mg de metilprednisolona *depot* (ampola) em cada um dos lados. O procedimento conferiu alívio imediato da sintomatologia e, após seis meses, o paciente mantinha redução significativa da alodinia, sem compromisso da qualidade de vida.

*Conclusões:* Os autores consideram que a realização do bloqueio do quadrado lombar tipo II foi uma opção analgésica relevante no tratamento de um paciente com dor crônica pós-hernioplastia abdominal e salientaram os efeitos da dispersão do anestésico local até o espaço paravertebral torácico. A técnica mostrou ser segura e bem tolerada. É desejável a publicação de mais casos clínicos que reproduzam a eficácia desse bloqueio no contexto de dor crônica.

© 2014 Sociedade Brasileira de Anestesiologia. Publicado por Elsevier Editora Ltda. Este é um artigo Open Access sob uma licença CC BY-NC-ND (<http://creativecommons.org/licenses/by-nc-nd/4.0/>).

**Introduction**

Described by A. Blanco,<sup>1</sup> the block of fascia plane of the *quadratus lumborum* muscle provides unilateral blockade of the abdominal wall, which may extend from T6 to L1.<sup>2,3</sup> *Quadratus lumborum* muscle is inserted into the lower edge of the last rib and, by four tendons, into the apices of the transverse processes of the vertebrae L1 to L4. The local anesthetic deposited in this muscle fascia can be transported along it until the paravertebral space and also through the vascular-nervous rolls,<sup>2</sup> providing the blockade of the referred dermatomes.

We report a case of a type II bilateral block of *quadratus lumborum* for the management of a postoperative chronic pain.

**Case report**

Male patient, 61 years old, 83 kg, referred to the Chronic Pain Unit for chronic due to abdominal wall chronic pain after multiple abdominal hernioplasties. He had a history of diabetes mellitus type 2, hypertension, duodenal ulcer post-perforation status, alcoholic liver disease, and consequent thrombocytopenia ( $79.10^9/L$ ).

The patient had undergone four abdominal wall surgeries for abdominal wall repair with esophageal stent. The last procedure was made a year and a half before. He developed a chronic neuropathic pain after the third surgery, with poor response to treatment with opioid and neuromodulator drugs. The abnormal liver function and intolerance to

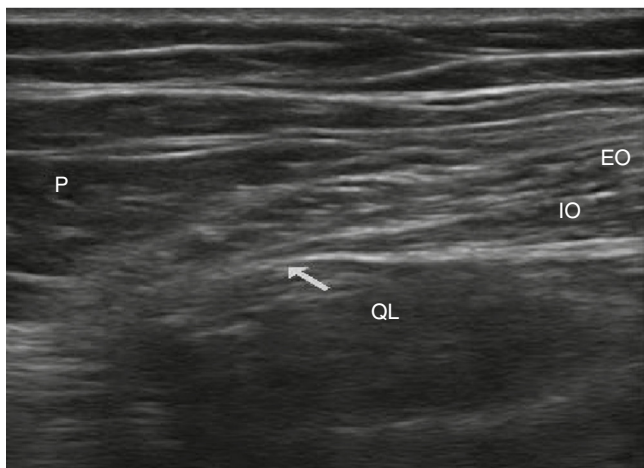
analgesics constituted a limitation to the increase in therapeutic doses.

The patient had a neuropathic pain, with prevalence of allodynia to touch, covering the entire anterior abdominal wall from T7 to T12 dermatomes, laterally limited by the anterior axillary line. His score on the visual analog scale (VAS) was 8/10 and 9/10 in the specific questionnaire for neuropathic pain screening (DN4), with great interference in quality of life.

Due to the poor analgesic response, limited by drug toxicity and associated liver morbidity, it was decided to perform a type II bilateral block of *quadratus lumborum* muscle guided by ultrasound, after obtaining the written informed consent of the patient.

The technique was performed in the supine position, with elevation of the ipsilateral pelvis. Under aseptic conditions, a high frequency probe was used (5–10 MHz), connected to an ultrasound unit in transverse orientation between the iliac crest and the costal margin, after the mid-clavicular line. The muscle planes were identified subsequently scanned until visualizing the *quadratus lumborum* muscle, at the same plane as the psoas major muscle and the erector spinae (Fig. 1).

A 100 mm neurostimulation needle was introduced outside the ultrasound plan, and subcutaneous infiltration was performed with 2% lidocaine (3 mL) guided by ultrasound. The needle tip was positioned between the rear face of the *quadratus lumborum* muscle and the anterior surface of the erector spinae. The needle path was accompanied by ultrasound and the correct needle position confirmed by injecting 2 mL of saline solution. After negative aspiration, 0.2%



**Figure 1** Ultrasound of the lumbar square approach type II (described by R. Blanco). EO, external oblique muscle; IO, internal oblique muscle; QL, *quadratus lumborum* muscle; P, psoas major muscle; arrow, injection site.

ropivacaine (25 mL) and depot (vial) methylprednisolone (20 mg) were injected, with visualization of the local anesthetic spread into the paravertebral space.

The procedure was repeated in the other side without incident or complications. During the procedure, verbal contact was maintained with the patient, who never expressed discomfort.

Sixty minutes after the procedure, the patient was asymptomatic, without allodynia throughout the abdominal wall, with a VAS score of 0/10 for pain at rest and in motion. He was discharged from the hospital two hours after the procedure and reported great satisfaction with the management of his pain.

Evaluated five days after the procedure, the patient remained asymptomatic, reporting only a sense of pressure on one side of the injection, not perceivable.

At the first month of the procedure, the patient had the allodynia restricted to a limited periumbilical area of approximately a quarter of the starting area and a VAS score of 2/10 at rest and of 6/10 in motion. Because of the underlying thrombocytopenia, it was decided not to repeat the blockade and schedule a local treatment with capsaicin 8% patch.

At the six months of the procedure and after a local treatment with capsaicin 8% patch, the allodynia remained restricted to the periumbilical area, with a VAS score of

3–4/10 at rest and in motion, and returned to his daily activity with quality.

## Conclusions

To the best of our knowledge, this is the first published case of a *quadratus lumborum* muscle type II blockade guided by ultrasound for postsurgical chronic pain.

We consider that the *quadratus lumborum* muscle type II blockade is a relevant analgesic option in the treatment of patients with chronic pain after abdominal hernia repair, refractory to conventional treatment.

The local anesthetic and adjuvant analgesic spread to the thoracic paravertebral space was essential for the symptomatic relief in this patient.<sup>1</sup> The follow-up after the procedure led to the conclusion that this is a safe and well-tolerated technique with irrelevant side effects. Its clinical utility was limited by the hematologic contingency of the patient to perform invasive therapeutic techniques. The authors subsequently opted for another therapeutic option of neuropathic pain, such as 8% capsaicin.<sup>4</sup>

We consider necessary the publication of more clinical cases that reproduce the analgesic efficacy of this blockade in the context of chronic pain.<sup>5,6</sup>

## Conflicts of interest

The authors declare no conflicts of interest.

## References

1. Blanco R. Optimal point of injection: the *quadratus lumborum* type I and II blocks. *Anaesthesia*. 2014.
2. Visoiu M, Yakovleva N. Continuous postoperative analgesia via *quadratus lumborum* block – an alternative to transversus abdominis plane block. *Pediatr Anesth*. 2013;23:959–61.
3. Kadam VR. Ultrasound-guided *quadratus lumborum* block as a postoperative analgesic technique for laparotomy. *J Anaesthesiol Clin Pharmacol*. 2013;29:550–2.
4. Dworkin R, O'Connor A, Audette J, et al. Recommendations for the pharmacological management of neuropathic pain: an overview and literature update. *Mayo Clin Proc*. 2010;85 Suppl.:S3–14.
5. Carney J, Finnerty O, Rauf J, et al. Studies on the spread of local anaesthetic solution in transversus abdominis plane blocks. *Anaesthesia*. 2011;66:1023–30.
6. Børglum J, Christensen A, Hoegberg L. Bilateral-dual transversus abdominis plane (BD-TAP) block or thoracic paravertebral block (TVPB)? Distribution patterns, dermatomal anaesthesia, and LA pharmacokinetics. *Reg Anesth Pain Med*. 2012;37:E137–9.