



REVISTA BRASILEIRA DE ANESTESIOLOGIA

Publicação Oficial da Sociedade Brasileira de Anestesiologia
www.sba.com.br



MISCELLANEOUS

Correlation of computed tomography, magnetic resonance imaging and clinical outcome in acute carbon monoxide poisoning



Namik Ozcan^{a,*}, Giray Ozcam^a, Pinar Kosar^b, Ayse Ozcan^a,
Hulya Basar^a, Cetin Kaymak^a

^a Department of Anesthesiology and Reanimation, Intensive Care Unit, Ankara Training and Research Hospital, Ankara, Turkey

^b Department of Radiology, Ankara Training and Research Hospital, Ankara, Turkey

Received 18 February 2014; accepted 5 May 2014

Available online 2 June 2014

KEYWORDS

Intensive care;
Carbon monoxide;
Imaging;
Poisoning

Abstract

Background and objectives: Carbon monoxide is a toxic gas for humans and is still a silent killer in both developed and developing countries. The aim of this case series was to evaluate early radiological images as a predictor of subsequent neuropsychological sequelae, following carbon monoxide poisoning.

Case 1: After carbon monoxide exposure, early computed tomography scans and magnetic resonance imaging findings of a 52-year-old woman showed bilateral lesions in the globus pallidus. This patient was discharged and followed for 90 days. The patient recovered without any neurological sequela.

Case 2: In a 58-year-old woman exposed to carbon monoxide, computed tomography showed lesions in bilateral globus pallidus and periventricular white matter. Early magnetic resonance imaging revealed changes similar to that like in early tomography images. The patient recovered and was discharged from hospital. On the 27th day of exposure, the patient developed disorientation and memory impairment. Late magnetic resonance imaging showed diffuse hyperintensity in the cerebral white matter.

Conclusion: White matter lesions which progress to demyelination and end up in neuropsychological sequelae cannot always be diagnosed by early computed tomography and magnetic resonance imaging in carbon monoxide poisoning.

© 2014 Sociedade Brasileira de Anestesiologia. Published by Elsevier Editora Ltda. This is an open access article under the CC BY-NC-ND license (<http://creativecommons.org/licenses/by-nc-nd/4.0/>).

* Corresponding author.

E-mails: namikozcan@gmail.com, namikozcan@yahoo.com (N. Ozcan).

PALAVRAS-CHAVE

Tratamento intensivo;
Monóxido de carbono;
Imagem;
Intoxicação

Correlação de tomografia computadorizada, ressonância magnética e resultados clínicos em intoxicação aguda por monóxido de carbono

Resumo

Justificativa e objetivos: Monóxido de carbono é um gás tóxico para os seres humanos, além de ser um assassino silencioso em países tanto desenvolvidos quanto em desenvolvimento. O objetivo desta série de casos foi avaliar as imagens radiológicas iniciais como um preditivo de sequelas neuropsicológicas subsequentes após intoxicação por monóxido de carbono.

Caso 1: Após exposição ao monóxido de carbono, os achados iniciais em tomografias computadorizadas e ressonâncias magnéticas de uma mulher de 52 anos de idade mostraram lesões em globo pálido bilateralmente. A paciente recebeu alta e foi acompanhada por 90 dias. A paciente se recuperou sem sequelas neurológicas.

Caso 2: Paciente do sexo feminino, 58 anos de idade, exposta ao monóxido de carbono. A tomografia computadorizada mostrou lesões em globo pálido, bilateralmente, e substância branca periventricular. A ressonância magnética inicial revelou alterações semelhantes àquelas em tomografias precoces. A paciente se recuperou e recebeu alta. No vigésimo sétimo dia de exposição, a paciente evoluiu com desorientação e perda de memória. Ressonância magnética posterior mostrou hiperintensidade difusa da substância branca cerebral.

Conclusão: As lesões da substância branca que progridem para desmielinização e resultam em sequelas neuropsicológicas nem sempre podem ser diagnosticadas em tomografias e ressonâncias iniciais em casos de intoxicação por monóxido de carbono.

© 2014 Sociedade Brasileira de Anestesiologia. Publicado por Elsevier Editora Ltda. Este é um artigo Open Access sob uma licença CC BY-NC-ND (<http://creativecommons.org/licenses/by-nc-nd/4.0/>).

Introduction

Carbon monoxide (CO) is a well-known, colorless and odorless gas that is toxic to all kinds of human tissues.^{1,2} Following exposure to CO, morphologic changes are seen in regions of the brain within hours.^{3–5} Bilateral demyelination of the cerebral white matter, hyperintensities of centrum semiovale, and hemorrhagic necrosis of the globus pallidus are some of the neuropathologic findings seen after CO poisoning.^{4,6}

The aims of this study were to evaluate the integrity of brain white matter and basal ganglions with magnetic resonance imaging (MRI) and computed tomography (CT) in the acute phase of CO exposure, and to evaluate early radiological images as a predictor of subsequent neuropsychological sequelae, following CO poisoning.

Case 1

A 52-year-old woman was found unconscious at home and referred to hospital with possible CO poisoning. Her heart rate was 95 beats min⁻¹, respiratory rate was 25 min⁻¹ and blood pressure measured was 90/60 mmHg. Results of arterial blood gas analysis were pH: 7.38, pO₂: 25 mmHg, pCO₂: 40 mmHg, HCO₃: 20.9 mEq L⁻¹, COHb: 46.4%, BE: -12.7, and lactate: 7 mEq L⁻¹ (<1.5). Laboratory findings showed Myoglobin: 488 ng mL⁻¹ (0–38.5), CK: 147 U L⁻¹ (0–145), CK-MB: 16.11 ng mL⁻¹ (0–5.6), and troponin-I: 0.048 μg L⁻¹ (<0.1). In neurological examination, the patient was comatose with a Glasgow Coma Scale (GCS) score of 9/15 and pupils were mydriatic.

Axial CT scans showed bilateral hypodensity in the globus pallidus within first 24 h (Fig. 1A). MRI findings on the 7th day of exposure were bilateral hyperintensity in the globus pallidus on axial, coronal T2-weighted (T2) (Fig. 1B and C), and axial FLAIR sequences. In addition, axial and sagittal unenhanced T1-weighted (T1) (Fig. 1D) images interestingly revealed peripheral hyperintensity of the globus pallidus.

The patient progressively recovered within 3 days and was discharged from the hospital on the 8th day of admission. The patient was followed for 90 days and did not develop any neurological sequela.

Case 2

A 58-year-old woman was admitted to intensive care unit after several hours of CO exposure. The clinical examination revealed heart rate 80 beats min⁻¹, respiratory rate 15 min⁻¹, and blood pressure 80/60 mmHg. Results of blood gas analysis were pH: 7.18, pO₂: 11.6 mmHg, pCO₂: 50 mmHg, HCO₃: 14.9 mEq L⁻¹, COHb: 56.2%, BE: -12.7, and lactate: 9 mEq L⁻¹ (<1.5). The laboratory findings showed myoglobin 4000 ng mL⁻¹ (0–38.5), CK: 247 U L⁻¹ (0–145), CK-MB: 27.6 ng mL⁻¹ (0–5.6), and troponin-I 0.131 μg L⁻¹ (<0.1), and ProBNP 1040 pmol L⁻¹ (<350). Physical examination showed mydriatic pupils and papilledema, the GCS score of 5/15, and the patient had generalized convulsions.

Brain CT performed in the 6th hour of admission showed hypodensity in bilateral globus pallidus (Fig. 2A). MRI performed on the 3rd day of admission showed patchy and peripheral enhancement in bilateral globus pallidus in contrast-enhanced T1 images (Fig. 2B) and hyperintensity in bilateral globus pallidus and in posterior crus of internal

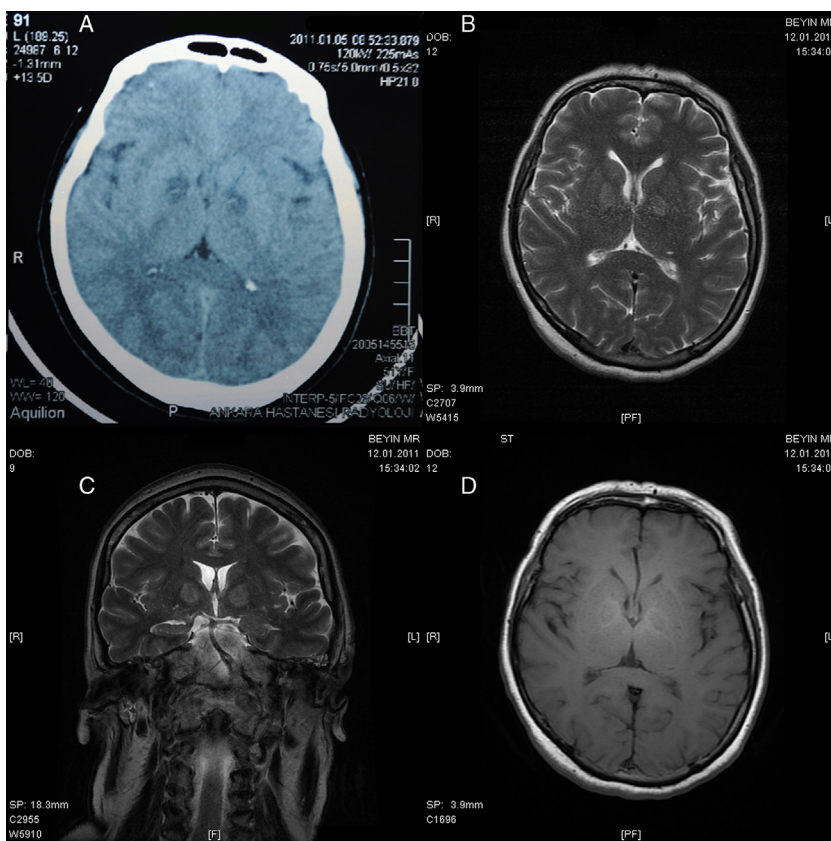


Figure 1 (A) Axial CT, (B) axial T2 MRI, (C) coronal T2 MRI, and (D) axial T1 MRI of Case 1.

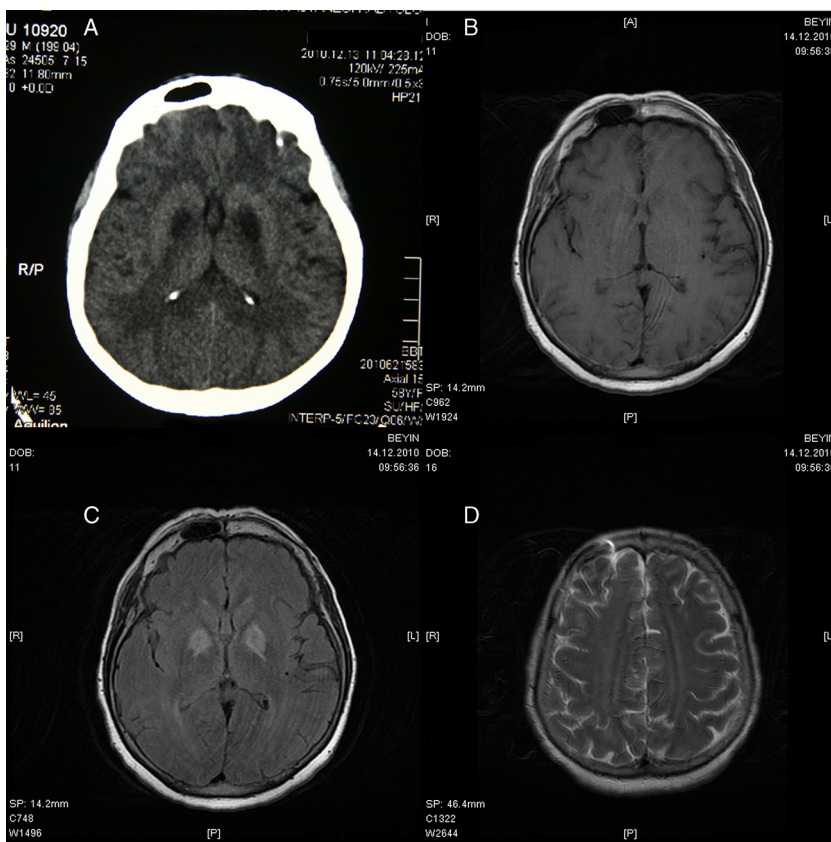


Figure 2 (A) Axial CT, (B) axial T1 MRI, (C) axial T2 MRI, and (D) axial T2 MRI (30th day) of Case 2.

capsule in axial T2, axial FLAIR (Fig. 2C), coronal T2 images. Cerebral white matter changes were not observed in any of the images.

The patient recovered within 5 days. She was discharged from the hospital on the 8th day of admission. This patient had developed disorientation and memory impairment on the 27th day of follow-up. Another diffusion MRI was performed on the 30th day of exposure. In addition to previous findings, diffuse hyperintensity in the cerebral white matter appeared, which was consistent with white matter damage in axial T2 images and diffusion T2 images (Fig. 2D).

Conclusion

Acute and intense CO exposure can lead to diffuse hypoxic-ischemic encephalopathy, including basal ganglia and cerebral white matter involvement.^{3,7} The globus pallidus is the most common site of involvement of basal ganglia in CO poisoning.^{4,6,8} Several studies concluded that there may be a correlation between acute stage hypoperfusion areas and the neuropsychiatric symptoms which develop consequently.^{1,3,7,9,10} It has been suggested that white matter lesions were more commonly associated with neurologic sequelae compared to lesions in the globus pallidus.¹⁰

After CO inhalation, globus pallidus damage usually occurs immediately, and cerebral white matter damage occurs within hours.³⁻⁵ It has been reported that the most common demyelination areas are the periventricular white matter and centrum semiovale.^{4,6,7} In severe cases, demyelination can extend to the subcortical white matter, corpus callosum, and external and internal capsules. These findings correlate well with the prognosis.⁴

In our cases, bilateral and symmetrical hypodensity of globus pallidus was present in early CT scans of both cases. In early MRIs, globus pallidus was isointense in the first case and in the second, interestingly, the periphery of globus pallidus was hyperintense in T1 images. However, we observed the typical finding of CO poisoning in T2 and FLAIR images, bilateral, symmetrical hyperintense globus pallidus for both cases. In addition, the posterior crus of the internal capsule was hyperintense in T2 and FLAIR images for the second case. In control MRI examination of the second case, which was performed one month later, we observed diffusely hyperintense white matter in T2 and FLAIR images which indicates white matter damage. Restricted diffusion in the white matter, which reflects cytotoxic edema, was observed in DW images and ADC map, at the same time.

In conclusion, our cases confirm the regional specificity of CO poisoning in the cerebral white matter and basal ganglia. White matter lesions progress to demyelination, which can be predictive of outcome and neuropsychological sequelae. Early CT and MRI images do not always correlate well with the clinical outcome. Further cases of CT and MRI with larger numbers of patients are needed to demonstrate the clinical outcome and prognosis.

Conflicts of interest

The authors declare no conflicts of interest.

References

1. Kim HJ, Chang KH, Song IC, et al. Delayed encephalopathy of acute carbon monoxide intoxication: diffusivity of cerebral white matter lesions. *Am J Neuroradiol.* 2003;24:1592-7.
2. Omaye ST. Metabolic modulation of carbon monoxide toxicity. *Toxicology.* 2002;180:139-50.
3. Thom SR, Fisher D, Manevich Y. Roles for platelet-activating factor and NO-derived oxidants causing neutrophil adherence after CO poisoning. *Am J Physiol Heart Circ Physiol.* 2001;281:H923-30.
4. Porter SS, Hopkins RO, Weaver LK, et al. Corpus callosum atrophy and neuropsychological outcome following carbon monoxide poisoning. *Arch Clin Neuropsychol.* 2002;17:195-204.
5. O'Donnell P, Buxton PJ, Pitkin A, et al. The magnetic resonance imaging appearances of the brain in acute carbon monoxide poisoning. *Clin Radiol.* 2000;55:273-80.
6. Chu K, Jung KH, Kim HJ, et al. Diffusion-weighted MRI and ^{99m}Tc-HMPAO SPECT in delayed relapsing type of carbon monoxide poisoning: evidence of delayed cytotoxic edema. *Eur Neurol.* 2004;51:98-103.
7. Chang KH, Han MH, Kim HS, et al. Delayed encephalopathy after acute carbon monoxide intoxication: MR imaging features and distribution of cerebral white matter lesions. *Radiology.* 1992;184:117-22.
8. Lo CP, Chen SY, Lee KW, et al. Brain injury after acute carbon monoxide poisoning: early and late complications. *AJR Am J Roentgenol.* 2007;189:W205-11.
9. Silver DA, Cross M, Fox B, et al. Computed tomography of the brain in acute carbon monoxide poisoning. *Clin Radiol.* 1996;51:480-3.
10. Gale SD, Hopkins RO, Weaver LK, et al. MRI, quantitative MRI, SPECT, and neuropsychological findings following carbon monoxide poisoning. *Brain Inj.* 1999;13:229-43.