



# REVISTA BRASILEIRA DE ANESTESIOLOGIA

Official Publication of the Brazilian Society of Anesthesiology  
[www.sba.com.br](http://www.sba.com.br)



## SCIENTIFIC ARTICLE

# Effectiveness of the C-MAC video laryngoscope in the management of unexpected failed intubations

Alper Kilicaslan\*, Ahmet Topal, Aybars Tavlan, Atilla Erol, Seref Otelcioglu

Department of Anaesthesiology, Meram Medical Faculty, Necmettin Erbakan University, Konya, Turkey

Received 2 December 2012; accepted 20 March 2013

### KEYWORDS

Airway management;  
Laryngoscopy;  
Difficult intubation

### Abstract

**Background and objectives:** The purpose of this study was to review the experiences of an anesthesiology department regarding the use of a C-MAC videolaryngoscope in unexpected failed intubation attempts.

**Methods:** Data were analyzed from 42 patients whose intubation attempts using Macintosh direct laryngoscopes had failed, and on whom a C-MAC videolaryngoscope was utilized as the primary rescue device. The success rate of C-MAC in intubation was assessed, and laryngeal views from both devices were compared.

**Results:** The Cormack and Lehane score was III in 41 patients, and IV in one patient, with the Macintosh laryngoscope, while Cormack and Lehane score was I in 27 patients, II in 14 and III in one with CMAC. Tracheal intubation with CMAC was successful on the first attempt in 36 patients (86%), and on the second attempt in 6 patients (14%). No complications were observed other than minor damage (blood on blade) in 8 patients (19%).

**Conclusion:** These data provide evidence for the clinical effectiveness of C-MAC videolaryngoscope in managing the unexpected failed intubations in routine anesthesia care. The C-MAC videolaryngoscope is efficient and safe as a primary rescue device in unexpected failed intubations.

© 2013 Sociedade Brasileira de Anestesiologia. Published by Elsevier Editora Ltda. All rights reserved.

## Introduction

Two capabilities that an anesthesiologist must possess are accurate assessment and efficient control of the airway.

Despite the strategic advancements in predicting difficult airway, the efficacy of routine preoperative tests is still limited.

Unexpected difficult laryngoscopy and failed tracheal intubation are among the major causes of morbidity and mortality associated with anesthesia.<sup>1,2</sup> In addition to the low success rates of multiple intubation attempts, complications such as airway trauma, hypoxia, tachycardia,

\* Corresponding author.

E-mail: [dralperkilicaslan@gmail.com](mailto:dralperkilicaslan@gmail.com) (A. Kilicaslan).

increase in blood pressure and intracranial and intraocular pressure, aspiration, and cardiac arrest may arise.<sup>3</sup> The American Society of Anesthesiologists (ASA) has limited repeated use of the same technique for the prevention of complications in difficult airway, and recommends the utilization of alternative techniques.<sup>4</sup> Videolaryngoscopes introduce a potential solution that enables better imaging of the larynx when conventional laryngoscopes fail.<sup>5</sup>

The C-MAC<sup>®</sup> videolaryngoscope (Karl Storz, Tuttlingen, Germany) features standard Macintosh blade designs with an external light source and small digital camera at the distal third of the blade that extend to a video display monitor.<sup>6</sup> Unlike videolaryngoscopes with acute angulated blades, it is possible to see the glottis in two ways: the first is the direct view of the glottis with the naked eye, and the second is the indirect view from the monitor with the help of a miniature camera at the tip of the blades.

Studies have shown that the limited laryngeal view improved with C-MAC following direct laryngoscopy.<sup>6,7</sup> Successful applications of a C-MAC in expected difficult laryngoscopy settings have also been reported.<sup>8</sup> However, there is insufficient knowledge on the efficacy of C-MAC and potential complications in emergencies during everyday clinical practices, such as unexpected (unpredicted) failed intubation.

A C-MAC is used as the primary emergency airway device in unexpected failed intubation cases in our department, and these cases are recorded using a standardized form. The purpose of this retrospective review was to evaluate the utility of a C-MAC that is used after failed intubation attempts with a conventional Macintosh laryngoscope.

## Methods

### Setting

This study analyses the recorded data on the difficult airway forms from patients who underwent tracheal intubation under general anesthesia in the operating room. In our operating room practices, we use C-MAC whenever suitable, if primary conventional laryngoscopy attempt reveals a difficult intubation and we are able to provide enough ventilation using a mask. However, a C-MAC is not used in every difficult laryngoscopy case since a number of our 24 operating rooms are located in different blocks, and we have only 1 videolaryngoscope (C-MAC) with a no. 3 blade in our department. Moreover, familiarization with how to use the newly acquired C-MAC in our department has not yet been fully achieved. Therefore, some anesthesiologists do not use the C-MAC because it is not available or because they are not trained. In cases of difficult laryngoscopy, a semi-rigid stylet is used to guide the endotracheal tube. The C-MAC is used by anesthesiologists with prior training and over 20 clinical use experiences, whenever possible.

In our department, information on unexpected failed intubation cases, applied techniques and results are recorded in a prepared standardized form. This form includes the following information: patient characteristics (including age, gender, ASA status), anesthesia technique, difficult facemask ventilation, device(s) used for intubation, person(s) who performed the intubation, the number of

intubation attempts, use of stylet, external laryngeal manipulations, success of intubation, complications.

The best laryngeal views obtained on consecutive attempts were recorded as Cormack and Lehane (CL) grade.<sup>9</sup> An attempt was defined as insertion of the endotracheal tube into the oropharynx. Retraction of the tube or unintended esophageal intubation is defined as "failure". The completion of the unexpected failed intubation forms is triggered by the anesthesiology specialist's clinical decision.

### Study design

After receiving approval from the institutional review board, the recorded difficult airway assessment forms for patients, who underwent general anesthesia between the dates of April 2011 and 2012, were retrospectively reviewed. Information regarding cases, in which a C-MAC videolaryngoscope was used following a failed orotracheal intubation attempt with a Regular Macintosh laryngoscope (Heine instruments Germany), was analyzed.

From these records, patients over the age of 18, who had no history of difficult intubation or difficult airway, had a Mallampati score of  $\leq 2$ , and normal airway examination, but had a failed intubation attempt following induction of anesthesia, were specified. Emergency surgery, obstetric cases, and cases in which direct laryngoscope was simultaneously used with a C-MAC by different anesthesiology specialists were excluded from the study.

### Outcome measures

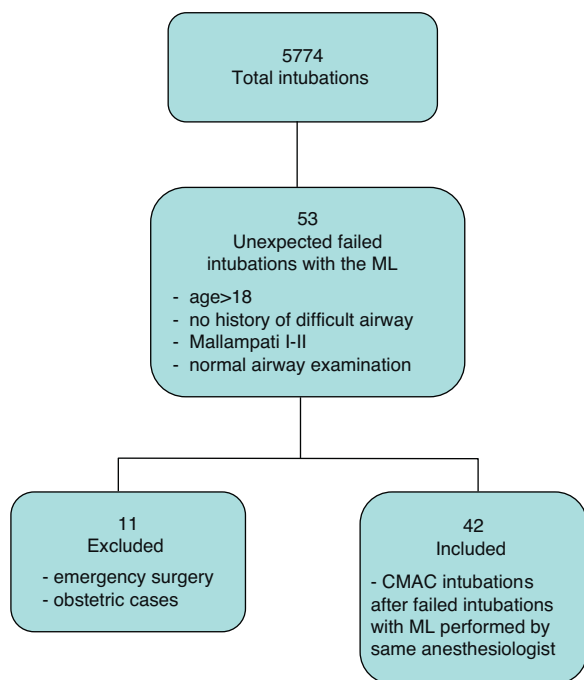
The primary outcome measure was the intubation success of C-MAC in direct laryngoscopy and unexpected difficult intubation cases. The second outcome measures were the Cormack–Lehane views through direct laryngoscopy and C-MAC.

### Statistical analysis

Statistical analysis was carried out with the 16.0 version of the SPSS programme for Windows (SPSS Inc., Chicago, IL). The Wilcoxon signed-rank test was used for the comparison of data obtained from the same patient using two separate devices. Normally distributed numerical data were presented as mean, standard deviation, and range (minimum–maximum). Categorical variables were presented as counts and percentages. *p*-Values of less than 0.05 were accepted as significant.

## Results

During the study period in our department, endotracheal intubation was performed on 5774 patients whose preoperative airway examinations were normal. Tracheal intubation attempts using Macintosh laryngoscope failed in 53 patients (0.91%), and a C-MAC laryngoscope was used as the primary emergency airway device. Out of these patients, 11 were excluded from the study either because they fit the exclusion criteria or the anesthesiology specialist using the C-MAC did not have sufficient experience (Fig. 1).



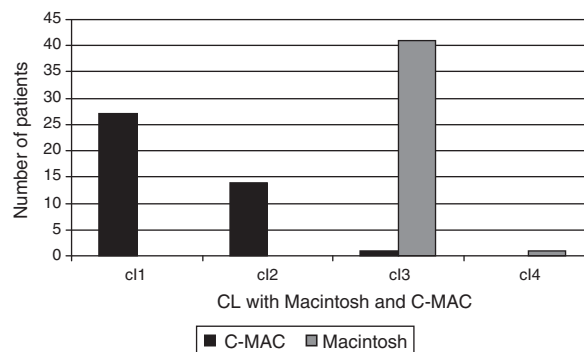
**Figure 1** Chart flow of patients' selection and inclusion.

The demographic and clinical characteristics of the patients are presented in Table 1. After induction of anesthesia, all patients' lungs could be ventilated by bag-mask ventilation, and no desaturation occurred.

The results of direct laryngoscopy using a Macintosh revealed a CL grade of 3 in 41 patients (97.6%), and a CL grade of 4 in 1 patient (2.4%). Then a CL score was III in 41 patients (97.6%), and IV in one patient (2.4%), with the Macintosh laryngoscope, while CL score was I in 27 patients (64%), II in 14 patients (33%), and III in one patient (3%) with CMAC.

**Table 1** Patient characteristics. Data are mean (SD) [range], or percentage and numbers.

Number of patients	42
Gender (male/female)	26 (62)/16 (38)
Age (years)	45.9 (12.5 [24–67])
Body weight (kg)	82.1 (12.6 [50–118])
Height (cm)	171.1 (8[154–188])
BMI ( $\text{kg m}^{-2}$ )	28.1 (7.9[19.1–42.2])
ASA class (I/II/III)	16/14/12
Mallampati class (I/II)	7 (17)/35 (83)
Thyromental distance (mm)	72 (8.5[65–105])
Opening mouth (mm)	39.8 (5.4[28–52])
Type of muscle relaxant (n)	
Rocuronium	28 (67)
Atracurium	14 (33)
Type of surgery (n)	
Cardiac surgery	9 (21.4)
General	18 (42.8)
Urologic	6 (14.3)
Orthopedic	3 (7.1)
Otorhinolaryngological	6 (14.3)



**Figure 2** Comparison of glottic view (Cormack and Lehane grades) using the Macintosh laryngoscope and C-MAC videolaryngoscope.

Forty-one laryngeal views (97.6%) improved when a C-MAC was used after a Macintosh (Fig. 2). The views in 14 patients (33%) improved 1 CL grade, while it improved 2 CL grades in 27 patients (64%) ( $p < 0.001$ ). The laryngeal views of 27 patients (64%) were CL 1, while it was CL 2 in 14 patients (33%), and CL 3 in 1 patient (3%). Although the C-MAC did not improve the laryngeal view in 1 patient, intubation was successful on the second attempt using a C-MAC.

Tracheal intubations were successful in all patients (100%;  $n = 42$ ) when C-MAC was used following failed intubations with Macintosh blades. Tubes were placed on the first attempt in 36 patients (86%), and on the second attempt in 6 patients (14%) when using C-MAC. Even though stylets were used in all patients during direct laryngoscopy, it was required in 6 patients (17%) during videolaryngoscopy. External laryngeal manipulation was performed in all patients during direct laryngoscopy but only in 6 patients (17%) during the second attempt with the C-MAC.

None of the patients' surgeries were postponed. No complications were observed other than minor damage (blood on blade) in 8 patients (19%).

## Discussion

According to the results of this study, in which the experiences of our institute were reviewed, videolaryngoscopy with C-MAC improves the glottic view and increases the success rate of tracheal intubation in cases of unexpected difficult intubations with conventional direct laryngoscopes. In this routine clinical care environment, the percentage of successful intubation in total was 100% with 86% of patients intubated at the first attempt without major complications in patients with unanticipated failed intubations.

The improvement in the laryngeal view and successful intubation rate observed in this study is similar to that of prior studies in which a C-MAC was used.<sup>6,8</sup> Piepho et al. have used a C-MAC laryngoscope in 52 patients with unexpected CL grade 3 or 4 laryngeal views through Macintosh laryngoscopy. In their study, the laryngeal view was improved in 49 patients (94%) using C-MAC, with successful intubations in all of them.<sup>7</sup> In a new, controlled, randomized study with a predicted difficult airway population, Aziz et al. reported that the intubation success rate of C-MAC at first

attempt (138/149; 93%) was higher compared to that of direct laryngoscopy (124/147; 84%).<sup>8</sup> In Byhahn et al. study, in which simulated difficult airway was established using rigid cervical immobilization collars, successful tracheal intubations were performed using C-MAC in 88% (38/43) of the patients.<sup>10</sup>

Earlier studies have shown that videolaryngoscopes, such as McGrath<sup>11</sup> or GlideScope<sup>12</sup> that have more angled blades than the conventional Macintosh, improved glottis view and increased intubation success rates. In a study where McGrath Series 5 videolaryngoscopes was evaluated, unsuccessful attempts were reported in 5% of the patients.<sup>13</sup> In another study, although good laryngeal views were established with a GlideScope, 6% of the patients could not be intubated.<sup>14</sup> When the blades are curved further to improve the view, the tip of the intubation tube, which has to be directed at a steeper angle to the larynx, touches the front wall of the trachea, preventing it from going further down.<sup>15</sup> In addition to being very similar to the Macintosh blade, the blade of the C-MAC is thinner, and the region that might touch the incisors has been narrowed, thus allowing more space to lift the epiglottis with a crank maneuver.<sup>9</sup> Due to its physical and formal characteristics, the issue of not being able to advance the tube further in difficult laryngoscopy cases occurs less when using a C-MAC blade compared to blades with steeper angles. According to the findings of the current study, C-MAC has an increased intubation success rate, while enhancing laryngeal views.

Stylets used in difficult airway cases may cause serious complications, such as palatal, tracheal or pharyngeal perforation. Data of the current study show that the need to use stylets was greatly reduced with C-MAC, and that no complications, other than minor bleeding, were observed.

This study has a number of limitations. First of all, the study was retrospective in nature, and the anesthetics and muscle relaxants could not be standardized. However, individual circumstances can be assessed equally because laryngoscopies were performed by the same experienced anesthesiology specialists on the same patient using both the Macintosh blade and C-MAC blade. Secondly, the failed intubation rates do not fully reflect the normal practice, because C-MAC was used as a secondary airway device without attempting intubation in a number of patients, in whom poor laryngeal views were observed with Macintosh.

In summary, the C-MAC videolaryngoscope is efficient and safe as a primary rescue device in unexpected failed intubations. These data provide evidence for the clinical effectiveness of videolaryngoscopy in managing the unexpected failed intubations in routine anesthesia care.

## Conflicts of interest

The authors declare no conflicts of interest.

## References

1. Caplan RA, Posner KL, Ward RJ, Cheney FW. Adverse respiratory events in anesthesia: a closed claims analysis. *Anesthesiology*. 1990;72:828–33.
2. Mort TC. Emergency tracheal intubation: complications associated with repeated laryngoscopic attempts. *Anesth Analg*. 2004;99:607–13.
3. Cook TM, Woodall N, Frerk C, Fourth National Audit Project. Major complications of airway management in the UK: results of the Fourth National Audit Project of the Royal College of Anaesthetists and the Difficult Airway Society. Part 1: Anaesthesia. *Br J Anaesth*. 2011;106:617–31.
4. A report by the ASA Task Force on Management of the Difficult Airway. Practice guidelines for management of the difficult airway. *Anesthesiology*. 2003;98:1269–77.
5. Stroumpoulis K, Pagoulatou A, Violari M, et al. Videolaryngoscopy in the management of the difficult airway: a comparison with the Macintosh blade. *Eur J Anaesth*. 2009;26:218–22.
6. Cavus E, Kieckhaefer J, Doerges V, Moeller T, Thee C, Wagner K. The C-MAC videolaryngoscope: first experiences with a new device for videolaryngoscopy-guided intubation. *Anesth Analg*. 2010;110:473–7.
7. Piepho T, Fortmueller K, Heid FM, Schmidtman I, Werner C, Noppens RR. Performance of the C-MAC videolaryngoscope in patients after a limited glottic view using Macintosh laryngoscopy. *Anaesthesia*. 2011;66:1101–5.
8. Aziz MF, Dillman D, Fu R, Brambrink AM. Comparative effectiveness of the C-MAC® videolaryngoscope versus direct laryngoscopy in the setting of the predicted difficult airway. *Anesthesiology*. 2012;116:1–8.
9. Cormack RS, Lehane J. Difficult tracheal intubation in obstetrics. *Anaesthesia*. 1984;39:1105–8.
10. Byhahn C, Iber T, Zacharowski K, et al. Tracheal intubation using the mobile C-MAC videolaryngoscope or direct laryngoscopy for patients with a simulated difficult airway. *Minerva Anesthesiol*. 2010;76:577–83.
11. Shippey B, Ray D, McKeown D. Case series: the McGrath videolaryngoscope – an initial clinical evaluation. *Can J Anaesth*. 2007;54:307–13.
12. Cooper RM, Pacey JA, Bishop MJ, McCluskey SA. Early clinical experience with a new videolaryngoscope (GlideScope) in 728 patients. *Can J Anaesth*. 2005;52:191–8.
13. Noppens RR, Mobus S, Heid F, Schmidtman I, Werner C, Piepho T. Evaluation of the McGrath Series 5 videolaryngoscope after failed direct laryngoscopy. *Anaesthesia*. 2010;65:716–20.
14. Rai MR, Dering A, Verghese C. The Glidescope system: a clinical assessment of performance. *Anaesthesia*. 2005;60:60–4.
15. Maassen R, Lee R, Hermans B, Marcus M, van Zundert A. A comparison of three videolaryngoscopes: the Macintosh laryngoscope blade reduces, but does not replace, routine stylet use for intubation in morbidly obese patients. *Anesth Analg*. 2009;109:1560–5.