



REVISTA BRASILEIRA DE ANESTESIOLOGIA

Official Publication of the Brazilian Society of Anesthesiology
www.sba.com.br



SCIENTIFIC ARTICLE

A New Technique for Long Time Catheterization of Sacral Epidural Canal in Rabbits

Yüksel Erkin^{a,*}, Zeynep Aydın^b, Aydın Taşdöğen^a, Ayşe Karcı^a

^a Department of Anesthesiology, School of Medicine, Dokuz Eylül University, İzmir, Turkey

^b Department of Anesthesiology, Alsancak State Hospital, İzmir, Turkey

Received August 24, 2012; accepted October 31, 2012

KEYWORDS

Anesthesia, Caudal;
Catheters, Indwelling;
Epidural Space;
Lidocaine;
Rabbits

Abstract

Introduction: In this study we aimed to develop a simple and practical technique for chronic sacral epidural catheterization of rabbits.

Methods: We included ten rabbits weighing 2-2.5 kg in the study. After anesthesia and analgesia, we placed an epidural catheter by a 2cm longitudinal skin incision in the tail above the sacral hiatus region. We confirmed localization by giving 1% lidocaine (leveling sensory loss and motor function loss of the lower extremity). The catheter was carried forward through a subcutaneous tunnel and fixed at the neck.

Results: Chronic caudal epidural catheter placement was successful in all rabbits. The catheters stayed in place effectively for ten days. We encountered no catheter complications during this period. The localization of the catheter was reconfirmed by 1% lidocaine on the last day. After animals killing, we performed a laminectomy and verified localization of the catheter in the epidural space.

Conclusions: Various methods for catheterization of the epidural space in animal models exist in the literature. Epidural catheterization of rabbits can be accomplished by atlanto-occipital, lumbar or caudal routes by amputation of the tail. Intrathecal and epidural catheterization techniques defined in the literature necessitate surgical skill and knowledge of surgical procedures like laminectomy and tail amputation. Our technique does not require substantial surgical skill, anatomical integrity is preserved and malposition of the catheter is not encountered. In conclusion, we suggest that our simple and easily applicable new epidural catheterization technique can be used as a model in experimental animal studies.

© 2013 Sociedade Brasileira de Anestesiologia. Published by Elsevier Editora Ltda. All rights reserved.

*Corresponding author. 852 Sokak, No:21, Atatürk Mahallesi, Bornova İzmir/Türkiye. Phone: +90.505.525.01.22, +90.232.221.19.94.
E-mail: yuksel.erkin@deu.edu.tr (Y. Erkin)

Introduction

Epidural catheterization is among the frequently used procedures for anesthesia and analgesia in humans. Local anesthetics, morphine and other opioid agents, agents like clonidine and somatostatin can be given via this route.¹⁻⁸ Many new agents are being tested for obtaining analgesia by epidural and spinal routes. Before using any agent by epidural or spinal routes in humans its effects have to be tested in experimental animals.^{1,2,5,8-11} Different catheterization techniques have been developed in animals like cats, dogs and monkeys. However, maintenance and preparation of these animals are expensive and require special laboratory conditions. Rabbits are comparatively easily supplied, maintained and monitored experimental animals used for this purpose.^{1-4,7,9-12} Various techniques for chronic epidural catheterization of the rabbit epidural canal have been defined in the literature. Most of these techniques require special surgical skill and experience, requiring an operating microscope in most instances.^{1,2,4,7-9,11-13} In this study we aimed to develop a simple, applicable and efficient technique for chronic sacral epidural catheterization of rabbits.

Methods

After approval from the Ethical Committee on Experimental Animal Testing, we included 10 rabbits weighing 2-2.5 kg in the study. We brought all experimental subjects to the experiment laboratory one day prior and allowed them to adapt to the environment. The next day, we obtained anesthesia with 40 mg.kg⁻¹ intraperitoneal thiopental. We fixed the rabbits to the study table and draped them with sterile surgical cover; then infiltrated local anesthesia of the region to be incised in the tail with 1 mL of 1% lidocaine. We removed all hair in the incision site. Taking into consideration that the vertebral column of the rabbits is composed of seven cervical, 12 lumbar, four sacral and 15 or 16 caudal vertebrae,¹⁴ we made a 2 cm longitudinal skin incision in the tail approximately 1 cm distal to the anus in the sacral vertebral region, coinciding with the sacral hiatus with strict attention to asepsis. After recognition of the sacral hiatus, a G-18 epidural catheter (Portex; fixed end, three side ports, OD: 0.9 mm) was carried forward 5 cm cranially in the epidural canal (Fig. 1). Ten minutes later, after seeing absence of neuronal mechanical injury and hemorrhage or cerebrospinal fluid leakage by aspiration of the catheter, we confirmed placement of the catheter with an injection of 1 mL of 1% lidocaine. Leveling sensory loss and lower extremity motor function loss (dragging both extremities while walking) were considered clinical findings of sacral anesthesia. There was no motor function loss in the upper extremities, which were easily moving. The part of the catheter exiting from the tail was fixed to the skin for providing continuous placement of the catheter in the caudal canal. Sensory level of rabbits were tested with pin-prick test. Local anesthesia with 1% lidocaine was administered subcutaneously between the level determined and the neck and then the catheter was carried forward in the subcutaneous tunnel towards the neck (Fig. 2). Skin was sutured in the incised regions (Fig. 2). The catheters were kept in the rabbits for 10 days to verify efficiency. One 1ml of saline solution was used every day to

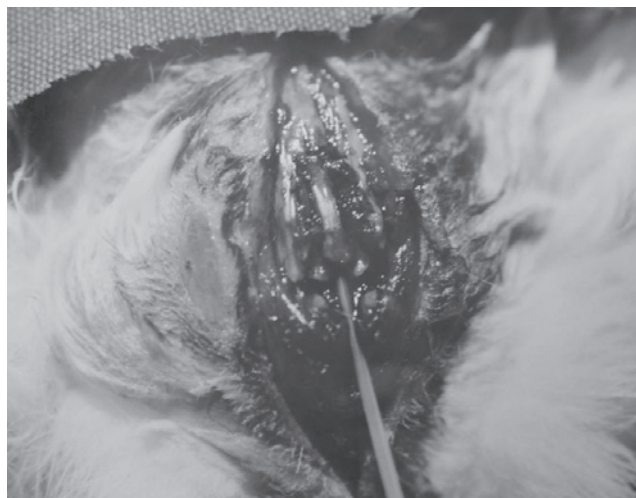

Figure 1 Catheter carried forward through sacral hiatus.

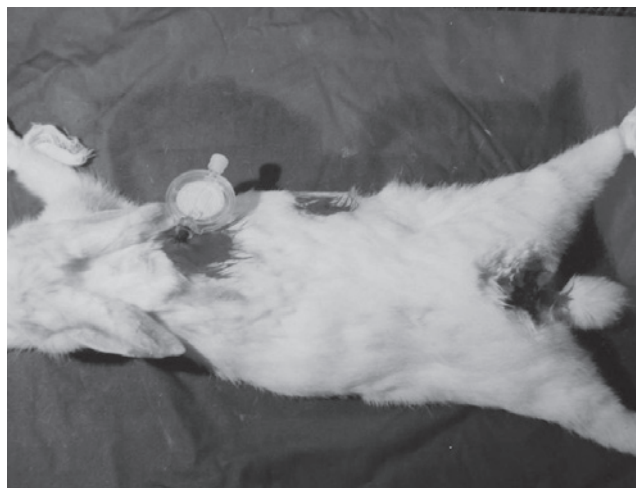


Figure 2 Catheter carried forward through subcutaneous tunnel and fixed at the neck.

inhibit catheter obstruction. On the last day, the position of the catheters were verified by 1 mL of 1% lidocaine. Afterwards, intraperitoneal high dose thiopental was administered and all animals were killed. Finally, laminectomy was performed to reconfirm the placement of the catheters in the epidural space.

Results

We achieved successful placement of caudal epidural catheter in all rabbits. We did not encounter subarachnoid catheterization or neurological injury in any rabbit. The catheters remained effective for ten days in all animals. No catheter related infection or any other complications were



Figure 3 Catheter placement verified by laminectomy.

seen during this period. Laminectomy performed after animals killing on the tenth day revealed that the catheters were in the epidural space in all rabbits (Fig. 3).

Discussion

Local anesthetics, opioids and many other agents are used by epidural route for providing analgesia or sedation in humans. However before applying any agent into the epidural space, its safety and efficiency has to be proved with animal experiments.

In order to investigate neuraxial anesthesia with different agents, many different methods of chronic catheterization in animal models have been described.^{1,3,7,9-13} While performing some procedures in larger animals seems feasible, supplying, maintaining, feeding, and sheltering of larger animals is expensive and demanding. Supplying, manipulating, sheltering, feeding and protection of smaller animals is cheaper and easier during a study. As in many animals, rabbits' vertebral columns are different from humans'. The vertebral column in rabbits is composed of seven cervical, 12 thoracic, seven lumbar, four sacral and 15 or 16 caudal vertebrae.¹⁴ Chronic subarachnoid catheterization in rabbits have been defined by Langerman et al.,⁷ and Yaksh and Rudy¹³ while chronic epidural catheterization has been defined by Madsen et al.¹¹ and Malinovsky et al.,⁸ Taguchi et al.¹² Epidural catheterization can be done by atlanto-occipital, lumbar routes or by tail amputation of rabbits.^{1,2,7-9,11-13} Histopathological changes are encountered less infrequently by epidural catheterization in comparison to intrathecal catheterization.^{5,11} While the atlanto-occipital approach seems practical, neurological deficits may have occurred due to the movement of distal catheter end with the animal's head movements or during advancement of catheter distally.¹³ Neurological injury is less often reported with lumbar compared to atlanto-occipital approach. However laminectomy requires surgical skill.^{1,2,5,7-9,11-13} Caudal approach with tail amputation in rabbits damages anatomical integrity.¹ Percutaneous caudal approach is less invasive and recommended by some authors; however it relies on loss of resistance and is eventually a

blind procedure. This increases neural damage risk and can decrease success.¹² Since Madsen et al.¹¹ have shown that 1 mL volume is distributed in Thoracic 8-9 level when given into epidural space, we used 1 mL of local anesthetic in our testing procedure. Our caudal technique does not require major surgical manipulation like laminectomy, and anatomical integrity is not disrupted as in tail amputation. In addition, unlike percutaneous approaches, our technique provides easy catheterization with direct observation of hiatus sacralis. Moreover, catheter malposition is prevented since we push the catheter forward through a subcutaneous tunnel until the neck and then fix it. The major drawback of our study is lack of histopathological studies of the spinal cord. If we had performed histopathological examination, we could also comment on the effects of chronic catheterization on the spinal cord, either favorable or unfavorable. Our technique is easily performed, does not disturb anatomical integrity, avoids catheter malposition, and is amenable to improvement. In conclusion, we think that this new technique of epidural catheterization in rabbits can be an appropriate model for investigating epidural agents in animals.

Conflicts of interest

The authors declare no conflicts of interest.

References

1. Arkan A, Kucukguclu S, Kupelioglu A, Maltepe F, Gokel E - New technique for catheterization of the sacral canal in rabbits. *Laboratory Animal Science*. 1990;71:529-535.
2. Aydın Z, Sayit E, Erkin Y, Capa G, Ertay Y, Sagiroğlu E, Durak H - Effects of octreotide and morphine on the clearance rate of indium-111-pentetreotide from the epidural space. *Nucl Med Commun*. 2000;21:835-838.
3. Bahar M, Rsen M, Vickers MD - Chronic cannulation of the intradural space in the rat. *Br J Anaesth*. 1984;56:405-410.
4. Castro MI, Eisenach JC - Pharmacokinetics and dynamics of intravenous, intrathecal and epidural clonidine in sheep. *Anesthesiology*. 1989;71:418-425.
5. Coombs DW, Fratkin JD - Neurotoxicology of spinal agents. *Anesthesiology*. 1987;66:724-726.
6. Durant PAC, Yaksh TL - Epidural injections of bupivacaine, morphine, fentanyl, lofentanyl and DADL in chronically implanted rats: A pharmacologic and pathologic study. *Anesthesiology*. 1981;64:43-53.
7. Langerman L, Chaimky G, Golomb E - A rabbit model for evaluation of spinal anesthesia. Chronic cannulation of the subarachnoid space. *Anesth Analg*. 1990;71:529-535.
8. Malinovsky JM, Bernard JM, Baudrimont M, Dumand JB, Lepage JY - A chronic model for experimental investigation of epidural anesthesia in the rabbit. *Regional Anesthesia*. 1997;22:80-85.
9. Canduz B, Aktug H, Mavioglu O et al. - Epidural lornoxicam administration-innocent. *Journal of Clinical Neuroscience*. 2007;14:968-974.
10. Feldman HS, Covino BG - A chronic model of investigation of experimental spinal anesthesia in the dog. *Anesthesiology*. 1981;54:148-152.
11. Madsen JB, Jensen FM, Faber T, Bille-Hansen V - Chronic catheterization of the epidural space in rabbits: a model for behavioral and histopathological studies. Examination of meptazinol neurotoxicity. *Acta Anesthesiol Scand*. 1993;37:307-313.

12. Taguchi H, Murao K, Nakamura K, Uchida M, Shingu K - Percutaneous chronic catheterization in the rabbit. *Acta Anesthesiol Scand.* 1996;40:232-236.
13. Yaksh TN, Rudy TA - Chronic catheterization of the spinal subarachnoid space. *Physiol Behav.* 1976;17:1031-1036.
14. Whitehouse RH, Grove AJ - The dissection of the rabbit with an appendix on the rat. London: University Tutorial Press, 1958, p. 32-70.